

Bilateral labia-minora skin flaps in vaginoplasty for partial vaginal agenesis: A new technique

R Singh, S Nanda, S Dalal, A Jain

Citation

R Singh, S Nanda, S Dalal, A Jain. *Bilateral labia-minora skin flaps in vaginoplasty for partial vaginal agenesis: A new technique*. The Internet Journal of Plastic Surgery. 2008 Volume 5 Number 2.

Abstract

A 17-years unmarried girl underwent vaginoplasty for partial vaginal agenesis along with drainage of haematocolpo-metro-salpingx. From the over hanging redundant labia-minora tissues, bilateral labia-minora flaps were designed to provide an intra-luminal surface lining of the neo-vagina. Bilateral labia-minora flaps are ideal for intra-luminal surface lining of the newly created vaginal cavity as the flaps are thin, pliable, non-hairy, vascular, versatile, well accustomed to genito-urinary secretions and obviate the necessity of prolonged post-operative dilatations to prevent neo-vaginal stenosis. Lining of the neo-vagina with bilateral labia-minora flaps was aesthetically and functionally acceptable.

INTRODUCTION

Different techniques have been described for correction of different degree of vaginal agenesis. Providing an intra-luminal lining of the newly created vaginal cavity with the use of labia minora flaps fulfils almost all the criteria of an ideal neo-vagina.

CASE REPORT AND TECHNIQUE

A 17-years unmarried girl was brought by her parents with 3 months history of pain and lump in the left half of the hypogastrium. She denied of having onset of menarche. She had feminine characters, well developed bilateral breasts and pubic hair. Three months back, she had undergone unsuccessful attempt of vaginoplasty by some private practitioner. Examination revealed an 8x8 cm tender, firm and mobile lump in left half of the hypogastrium and vaginal atresia. Rectal and bimanual examinations also showed haematocolpos and haematometra. USG delineated haematocolpo-metro-salpingx, normal ovaries and rudimentary uterus. IVP mapped normal upper and lower urinary tract. MRI confirmed vaginal agenesis, haematocolpo-metro-salpingx with pelvic collection of the retained blood. An 18 F Foley catheter was put to identify and safe guard the urethra and 28 F Hagar dilator was inserted into rectum to protect incidental rectal perforation.

Xylocaine-adreneline solution (1:200,000) was infiltrated into the atretic tissues. Through a V-shaped incision, a blunt and sharp dissection was carried out taking special care not

to perforate urethra and bladder anteriorly and rectum posteriorly. The bluish coloured dome was aspirated to confirm haematocolpos. It was drained with a cruciate incision to open it widely. The over hanging labia minoras were displayed on both sides (Fig.1); bilateral symmetrical flaps were marked (Fig.2); laterally based flaps were designed on either side by opening up of both the layers (Fig.3); and, both the flaps were repositioned in to the neo-vaginal cavity to be sutured high-up with the pre-existing vaginal lining. Thorough irrigation was done to evacuate all retained blood products. Any urethral, bladder or rectal injuries were excluded. A condom packed with cotton gauzes was put into the neo-vagina and patient was dressed with T-shaped bandage. Her postoperative recovery was smooth. At discharge, she was advised regular use of candle for self vaginal dilatation. Examination at 3 months showed healthy and well taken labia-minora flaps. At 6 month of follow-up, the neo-vagina was having adequate lumen and fully epithelialized (Fig.4). There after she did not require any vaginal mould to be put regularly to prevent vaginal stenosis. She had started having normal menstrual cycle of 5 / 30 days.

Figure 1

Figure 1: Redundant labia minoras.

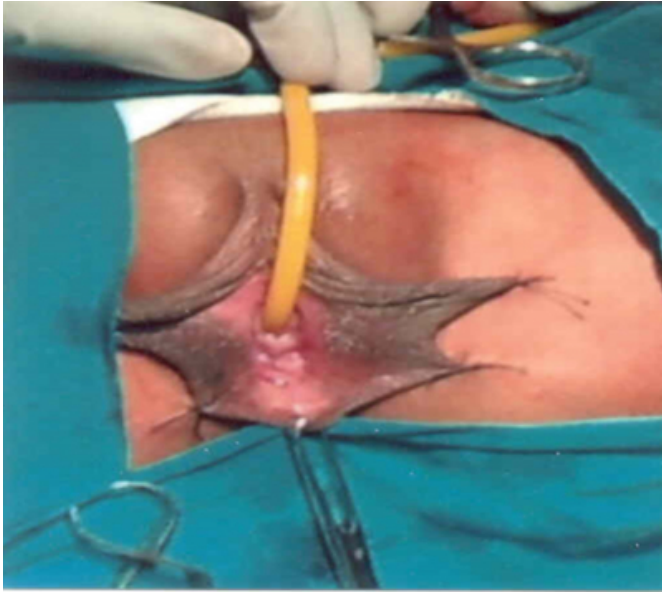


Figure 2

Figure 2: Labia minora flaps marked.

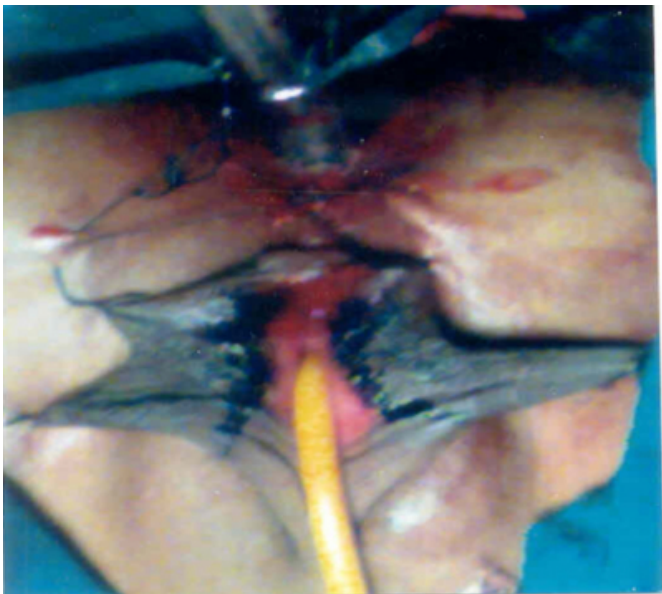


Figure 3

Figure 3: Labia minora flaps designed.

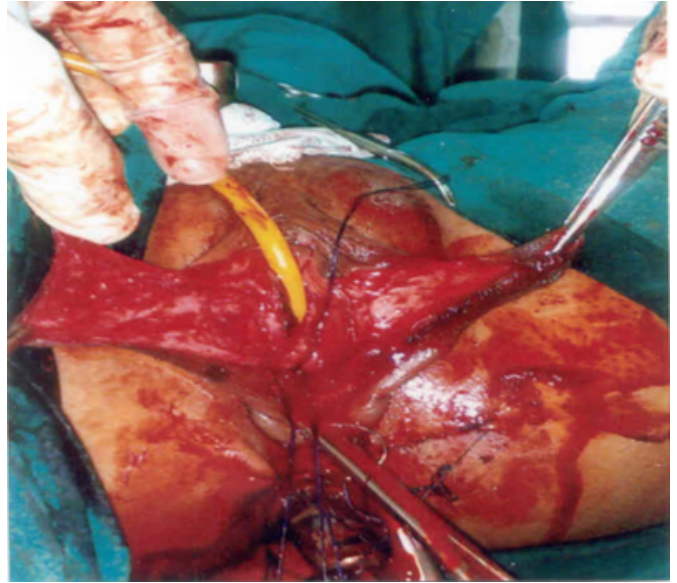
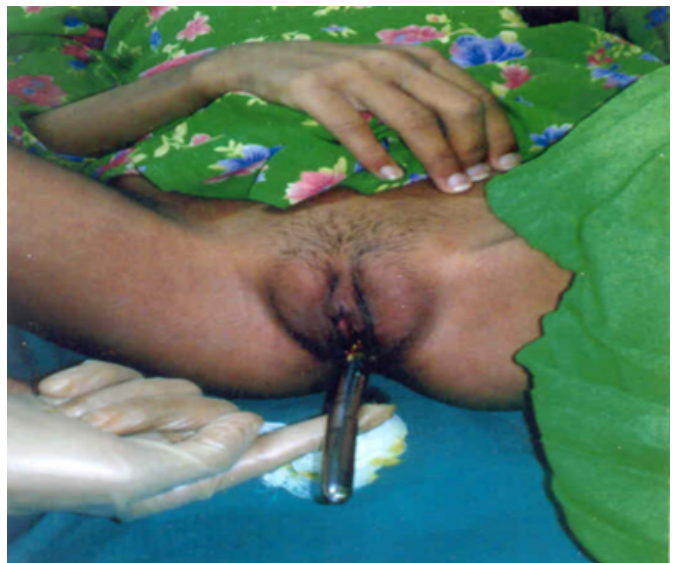

Figure 4

Figure 4: At 6 months of follow-up – 26 F Hegar dilator easily accommodated by neo-vagina.



LIMITATION

While designing bilateral labia-minora flaps, extreme care and gentleness is needed to open both the leaves of the labia-minoras. These flaps are ideal only for providing tension free lining in cases of partial vaginal agenesis and a supplementation with split thickness or full thickness skin graft is required to provide complete coverage in cases of total vaginoplasty.

DISCUSSION

The neo-vagina, apart from having adequate depth and breadth, should have near-normal textured surface lining not requiring long term post-operative care, especially to prevent stenosis and re-do surgery. Different techniques have been described for vaginoplasty like: labia minora flaps^{1,2}; labia minora flaps after tissue expansions³; labia minora flaps supplemented with skin grafts^{4,5}; and, inlay split skin graft, skin flaps, fascio-cutaneous flaps, myocutaneous flaps, intestinal transposition, external pressure on the perineum by an external mould, dissection of cavity and insertion of mould for spontaneous epithelialization, amnion homograft and delayed skin grafting of the dissected neo-vaginal cavity.^{6,7,8} Labia-minora skin flaps are extremely thin, non-hairy, highly vascular, versatile and pre-acclimatized to urine and genital secretions; obviate post-operative lengthy, cumbersome and repeated maneuvers of inserting vaginal moulds / dilators to prevent stenosis and contracture; make use of redundant tissues for neo-vaginal lining and aesthetically re-shape the over hanging labia-minora to become more acceptable; do not require much of lubrications like that of the split-thickness skin graft; are best suited in repeat vaginoplasty and in the presence of excessive scarring; and, might help in re-enforcement of incidentally / accidentally created urethral, bladder or rectal perforations during dissection.

CONCLUSION

Labia-minora skin, by virtue of its location and physical

characteristics, is best suited for vaginoplasty in partial vaginal agenesis, both aesthetically and functionally.

CORRESPONDENCE TO

Dr. Satish Dalal 9J/54, Medical Campus, PGIMS, Rohtak-124001 (Haryana) INDIA Tel. No. +91-1262-213459, Mobile : 09315326802 E-mail : drsatishdalal@rediffmail.com

References

1. Hwang WY, Chang TS, Sun P, Chung TH. Vaginal reconstruction using labia minora flaps in congenital total absence. *Ann Plast Surg* 1985; 15(6): 534-37.
2. Purushothaman V. Horse shoe flap vaginoplasty - a new technique of vaginal reconstruction with labia-minora flaps for primary vaginal agenesis. *Br J Plast Surg* 2005; 58(7):934-39.
3. Wu J, Hong Y, Li SF, Hu ZQ. Labia minora skin flaps vaginoplasty using tissue expansion. *Zhonghua Zheng Xing Wai Ke Za Zhi* 2003; 19(1):18-20.
4. Baytekin C, Menderes A, Mola F, Balik O, Tayfur V, Vayvada H. Total vaginal reconstruction with combined 'Split Labia Minora Flaps' and full-thickness skin grafts. *J Obstet Gynaecol Res* 2007; 33(4):524-8.
5. Huang WY. Reconstruction of the vagina by using the labia minora supplemented by partial skin grafting. *Zhonghua Yi Xue Za Zhi* 1984; 64: 474-7.
6. Mustarde JC. Vaginal agenesis. In "Plastic surgery in infancy and childhood". 2nd edition. London. Churchill Livingstone. 1979: 482-7.
7. Rock JA, Breech LL. Surgery for anomalies of the Mullerian ducts. In "Te Linde's operative gynecology". Rock JA, Jones HW 111 (eds). 9th edition, Philadelphia. Lippincot Williams and Wilkins. 2003: 705- 52.
8. Hudson CN, Setchell ME. Genital fistula. In "Shaw's text book of operative gynaecology". 6th edition. Elsevier , a division of Reed Elsevier India Private Limited. Srinivasapuri, New Delhi.2006: 237-69.

Author Information

R.B. Singh, M.S., MCh.

Professor, Department of Burns & Plastic Surgery and Special Clinic Hypospadias & VVFs, Pt.B.D.Sharma Postgraduate Institute of Medical Sciences (P.G.I.M.S.)

S. Nanda, MD

Professor, Department of Obstetrics and Gynecology, Pt.B.D.Sharma Postgraduate Institute of Medical Sciences (P.G.I.M.S.)

S. Dalal, MS

Associate Professor, Department of General Surgery, Pt.B.D.Sharma Postgraduate Institute of Medical Sciences (P.G.I.M.S.)

A. Jain, M.S.,M.Ch.

Assistant Professor, Department of Burns & Plastic Surgery and Special Clinic Hypospadias & VVFs, Pt.B.D.Sharma Postgraduate Institute of Medical Sciences (P.G.I.M.S.)