

Submental Epidermoid Cyst- A Case Report

J chaturvedi, K Hegde, A Ananthamurthy, R Nayar

Citation

J chaturvedi, K Hegde, A Ananthamurthy, R Nayar. *Submental Epidermoid Cyst- A Case Report*. The Internet Journal of Head and Neck Surgery. 2009 Volume 4 Number 2.

Abstract

Epidermoid cysts are rare lesions in the head and neck and are most often located in the submental region. They are usually due to surgical or accidental events leading to traumatic implantation of epithelial cells into deeper tissues. It is uncommon to find an Epidermoid cyst without this history. We operated on a 30 year old male patient who presented with a 10 year history of a slow growing painless midline neck swelling and had no history of any trauma or surgical procedures in the head and neck area. The cyst was excised under general anesthesia and found to be in the submental region extending to the left parapharyngeal area. A histopathological examination revealed a connective tissue wall lined by squamous keratinizing epithelium without any identified adenexal structures suggestive of an Epidermoid cyst. This case was noteworthy due to the absence of any apparent cause explaining implantation of epithelial cells in this region.

INTRODUCTION

The Differential diagnosis of slow growing midline swellings of the neck include Ranula's, Thyroglossal cysts, Teratomas and Keratin cysts. The term Keratin cysts includes Epidermoid cysts and Pilar cysts.⁽⁹⁾ Benign teratomatous lesions are Dermoid Cyst and Teratoid Cyst⁽⁷⁾.

Epidermoid cysts of the neck are rare and most often located in the submental region [Incidence - 1.6 to 6.9%]⁽¹⁾⁽³⁾. These cysts remain asymptomatic for a long time until they interfere with swallowing, speaking, breathing or when an infection occurs⁽³⁾. They are usually due to surgical or accidental events leading to traumatic implantation of epithelial cells into deeper tissues and it is uncommon to find an Epidermoid cyst without this history.

We present a case of Epidermoid Cyst of the submental region with review of relevant literature.

CASE REPORT

A 30 yr old man presented in the OPD of a Tertiary Medical Centre in South India with a 10 year history of a painless slow growing midline neck swelling. There was no dysphagia, dyspnoea or hoarseness.

On inspection, a single, smooth, firm 3 x 5 cm swelling was noted in the submental region 2 cm below the mandible extending upto the hyoid bone. It was soft and cystic in consistency and did not move with protrusion of tongue or with deglutition. The skin over swelling was mobile and

there were no palpable Lymphnodes.

A Contrast enhanced CT of the neck showed a thin walled cyst extending superiorly up to sublingual area, inferiorly upto the pyriform sinus compressing the aryepiglottic folds and laterally up to submandibular gland and sternocleidomastoid muscle. [Fig 1] A provisional diagnosis of a dermoid cyst was made. A possibility of a plunging ranula was also considered. A Fine needle aspiration Cytology showed keratinous Cystic material suggestive of an Epidermoid cyst.

The cyst was excised under general anesthesia. A multi lobulated dumbbell shaped swelling present superior and inferior to the hyoid bone was noted extending to the left parapharyngeal area, pushing the larynx to the right. It was dissected and removed. [Fig 2, 3]

A histopathological examination revealed a connective tissue wall lined by squamous keratinizing epithelium without any identified adenexal structures indicative of an Epidermoid cyst. [Fig 4]

Figure 1

Table 1

	Epidermoid Cyst	Dermoid Cyst	Teratoid cyst	Plunging Ranula
<u>Incidence in Head and Neck</u>	Less common in head and neck region*	More common in head and neck region	Less common	More common
<u>Location</u>	Midline and Non Midline*	Midline	Midline	Non Midline
<u>Type of cyst</u>	Inclusion cysts lined by ectoderm	Inclusion cysts lined by ectoderm	Inclusion cysts lined by ectoderm	Pseudocysts of the floor of the mouth
<u>Thickness of Wall</u>	Thin lining because of lack of dermal appendages*	Thick lining	Thick lining	Thick Lining
<u>Pathology</u>	Failure of surface ectoderm to separate from underlying structures, sequestration of surface ectoderm and implantation of surface ectoderm.	Failure of surface ectoderm to separate from underlying structures, sequestration of surface ectoderm and implantation of surface ectoderm.	Failure of surface ectoderm to separate from underlying structures, sequestration of surface ectoderm and implantation of	Mucous extravasation from a blocked sublingual gland.
<u>Presence of skin appendages</u>	Skin appendages are absent* within the wall.	Skin appendages are present	Skin appendages are present	Skin appendages absent
<u>Epithelium</u>	Contains only squamous epithelium*	Contains hair sebaceous and sweat glands and squamous epithelium.	Contains tissue from other organ systems like, Nervous system, GI system or respiratory system.	They are cystic saliva filled distensions of salivary gland ducts on the floor of the mouth alongside the tongue, and lack a true epithelium.
<u>Contents</u>	Keratinaceous cheesy material due to squamous epithelium*	Keratinaceous cheesy material due to squamous epithelium	Keratinaceous cheesy material due to squamous epithelium	consists of collected mucin from a ruptured salivary gland duct.
<u>Treatment</u>	Excision*	Excision	Excision	Includes excision in continuity with the sublingual gland of origin.

*Present in this case

Figure 5

Fig[4] A histopathological examination revealed a connective tissue wall lined by squamous keratinizing epithelium without any identified adenexal structures indicative of an Epidermoid cyst

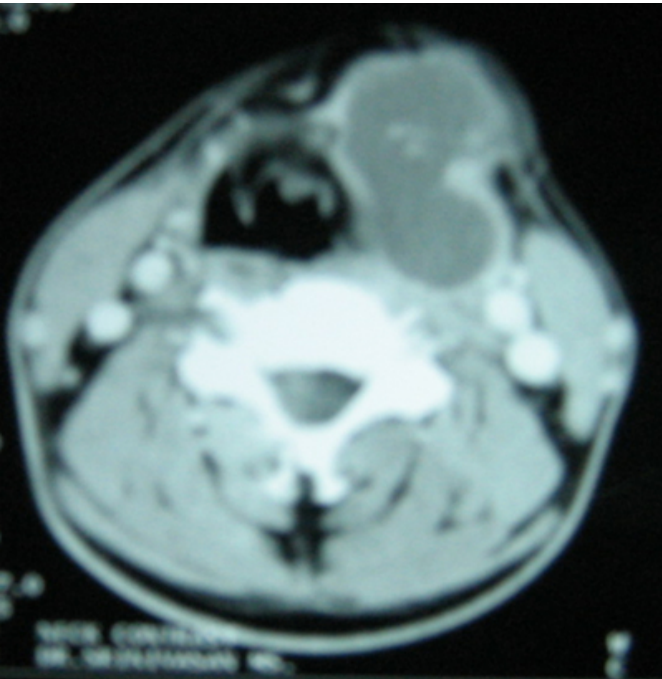


Figure 3

Fig[2]Cyst Exposed and dissected from surrounding muscles of floor of mouth, strap muscles inferiorly and laterally with parapharyngeal region attachment encountered at lower border of hyoid which was released and excised.

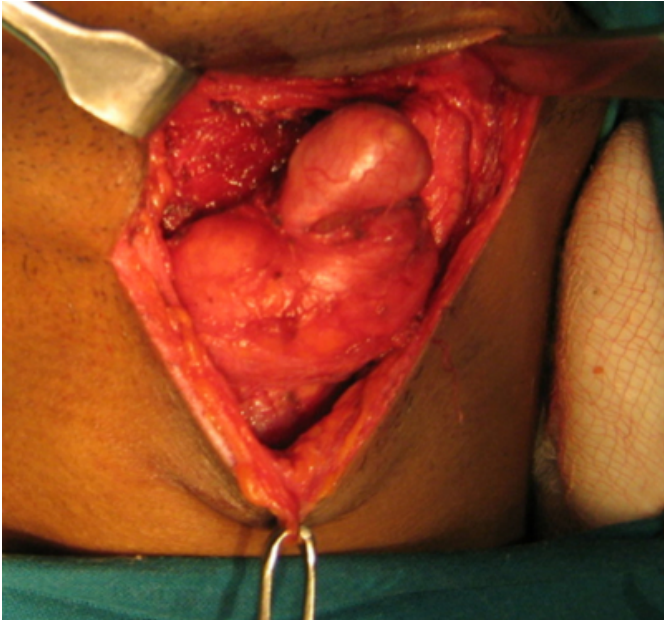
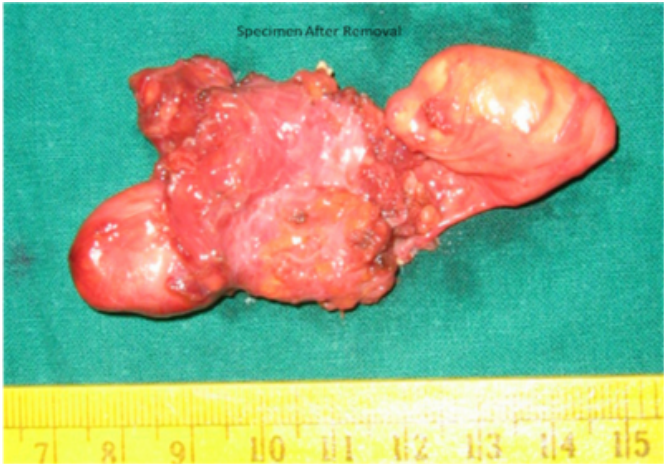

Figure 4

Fig[3] Specimen after removal.



{image:5}

DISCUSSION

Epidermoid cysts are rare lesions in the head and neck and are most often located in the submental region ⁽⁸⁾. They are a form of Keratin cysts and need to be differentiated from other similar lesions such as Dermoid cysts, Teratoid cysts, Thyroglossal cysts and Plunging Ranula's to decide the surgical approach during Excision. ^{(1)(7) (9)}[Table 1]

They most commonly present with a midline, painless, slow

growing, suprahyoid swelling in the neck enlarging over years due to accumulation of cutaneous products⁽⁵⁾⁽¹⁾. Typically, the mass is soft, mobile and unattached to overlying skin⁽¹⁾. They are described as pearly tumors because of the shiny, smooth and waxy character of their dry keratin⁽¹⁾. The size of the cyst can range from few mm to 12 cms⁽⁵⁾

Most dermoid or epidermoid cysts of the floor of the oral cavity are derived from epithelial debris or rests, enclaved during midline closure of the bilateral first and second branchial arches, between 3rd and 5th weeks of gestation.⁽¹⁾⁽³⁾ Another theory suggests surgical or accidental events leading to traumatic implantation of epithelial cells into deeper tissues. Some theories believe it to be a variant form of thyroglossal duct cyst⁽⁵⁾

The term Traumatic Epidermoid cysts and Epidermoid Inclusion Cysts (EIC) describe the same phenomenon, and both indicate a traumatic etiology.⁽²⁾ The epithelial implant theory is the most commonly accepted pathogenesis. It proposes that epidermal structures are driven into deeper tissues. The trapped epidermal structures assume the role of a skin graft and become independent. The tissue continues growing in its new position and produces keratin, thus forming a cyst.⁽²⁾ Tympanomastoid surgery, insertion of ventilation tubes and stapedectomy are examples of Otolological procedures that have been reported as etiologic factors in the development of Epidermal Inclusion Cyst in areas such as the Tympanic membrane and middle ear.⁽²⁾ However in many cases where traumatic events were identified it did not always lead to the development of an Epidermoid cyst. A Role of surgical injury in the formation of cysts still remains uncertain.⁽³⁾

To determine the nature and contents of the lesion a CT Scan showing moderately thin walled, unilocular masses filled with a homogenous, hypoattenuating (0-18HU) fluid material with multiple hypoattenuating fat nodules giving the "sack-of-marbles" appearance, is virtually pathognomonic for a dermoid cyst in this location⁽⁵⁾ Epidermoid cysts have fluid attenuation on CT Scans and on MRI they are hypointense on T1 and hyperintense on T2 weighted images.⁽⁵⁾

Based on imaging the relationship of the lesion with the

mylohyoid muscles can help to decide the surgical approach.⁽¹⁾ Most Dermoid cysts are located superior to the mylohyoid muscle in the sublingual space and only a small external swelling is noted which can be removed by an intraoral approach. Less commonly, the lesion may be inferior to the mylohyoid muscles where an obvious submental swelling is seen and the cyst which is externally palpable can be removed by an external submandibular approach.⁽¹⁾

Treatment consists of complete surgical removal, without rupturing the cyst, as the luminal contents may act as irritants to fibro vascular tissues, producing postoperative inflammation⁽¹⁾. After any ear surgery, all otolaryngologists must be aware of the possibility of EICs developing in the upper neck region particularly in patients with a prior history of tympanomastoid surgery on the same side.⁽⁵⁾

This case was noteworthy due to the absence of any apparent cause explaining implantation of epithelial cells in this region.

References

1. Pancholi A., Raniga S., Vohra P A., Vaidya V. Midline Submental Epidermoid Cyst: A Rare Case :The Internet Journal of Otorhinolaryngology. 2006;4(2)
2. Ulku C.H., Uyar Y., Kocaogullar Y ., Avunduk M.C. Iatrogenic Epidermal Inclusion Cyst of the Parapharyngeal space: Unusual Complication of Ear Surgery :Skull Base: An Interdisciplinary Approach.2004;14(1):47-51
3. Ponte F.S.D., Brunelli A., Marchetti E., Bottini D.J. Sublingual Epidermoid cyst:The Journal of Craniofacial Surgery.2002;13(2):308-310
4. Chandra P.S., Gupta A., Mishra N.K., Mehta V.S. Association of Craniovertebral and upper cervical anomalies with Dermoid and Epidermoid cysts: Report of 4 cases: Neurosurgery. 2005;56(5):E1155
5. Darrouzet V., Vidal V.F., Hilton M., Nguyen D.Q., Fougere S.L., Guerin J., Bebear J.P. Surgery of Cerebropontine Angle Epidermoid Cysts: Role of the widened Retrolabyrinthine approach combined with endoscopy: Otorhinolaryngology- Head and neck surgery.2004;131(1):120-125.
6. Byron J., Jonas T., Shawn D. Text book of Head & Neck Surgery - Otolaryngology, 4th Edition : Chapter 86 - Congenital Neck Masses and Cysts;86:1210-1216
7. Koeller K.K., Alamo L., Adair C.F., Smirniotopoulos J.G. Congenital Cystic Masses of the Neck: Radiologic - Pathologic Correlation. Radiographics.1999;19:121-146
8. Lohaus M, Hansmann J, Witzel A, Flechtenmacher C, Mende U, Reisser C. Uncommon sonographic findings of an Epidermoid cyst in the head and neck: HNO;1999;47(8):737-40.
9. Rose J. Skin: Tumour and tumour like conditions .Rosai and Ackermans Text book of Surgical Pathology:7th ed; Vol 1:193-245

Author Information

Jagdish chaturvedi, MBBS

Post Graduate Resident, Department of ENT, St John's Medical College and Hospital, Bangalore, India

Kalpana Hegde, MBBS, DLO

Post Graduate Resident, Department of ENT, St John's Medical College and Hospital, Bangalore, India

Anuradha Ananthamurthy, MD

Associate Professor, Department of Pathology, St John's Medical College and Hospital, Bangalore, India

Ravi C Nayar, MBBS, MS, DLO, DNBE

Professor and Head, Department of ENT, St John's Medical College and Hospital, Bangalore, India