

# Sonoanatomy Of The Ulnar Nerve In The Distal Forearm

A Thallaj, A El-Dawlatly, A Turkistani, O Zoraigi, M Shraf al-deen

## Citation

A Thallaj, A El-Dawlatly, A Turkistani, O Zoraigi, M Shraf al-deen. *Sonoanatomy Of The Ulnar Nerve In The Distal Forearm*. The Internet Journal of Anesthesiology. 2006 Volume 15 Number 1.

## Abstract

In the distal forearm, ulnar nerve gives off a dorsal cutaneous branch which supplies the dorso-medial hand and digits. We aimed to test the reliability of ultrasound to visualize the dorsal cutaneous branch and to examine the relationship of ulnar nerve division point and other palpable bony landmarks.

Methods: 100 male and female volunteers were studied. We scanned the left distal forearm using 5-13 MHz linear transducer (LOGIQe-GE). Distance between the ulnar division point and ulnar styloid process (DS) was recorded.

Results: Ulnar nerve division point and the dorsal cutaneous branch were visible in all subjects. There was no statistically difference in the DS distance between both groups (male: 5.9+/- 1.4 vs. female 5.7+/- 1.2 cm ; p = .12).

Conclusion: Ultrasound can reliably depict the ulnar nerve division point and the dorsal cutaneous branch in the distal forearm.

## INTRODUCTION

The practice of ultrasound (US) guided regional anesthesia requires excellent knowledge of the related clinical anatomy. In the distal forearm, ulnar nerve gives off a dorsal cutaneous branch which supplies sensation to the dorso-medial hand and digits (1). Ulnar nerve block in the distal forearm with conventional technique may spare the dorsal branch and result in incomplete block (2, 3). US represent a unique modality for visualizing peripheral nerves, because of its ability to scan the nerve over a long distance, and it has been used to visualize and to guide ulnar nerve block in the distal forearm (4, 5, 6). The aim of this study is to describe the sonographic appearance of the ulnar nerve division in the

distal forearm, test the reliability of ultrasound to depict the dorsal cutaneous branch and to examine the relationship of the ulnar nerve division point and other palpable bony landmarks.

## SUBJECTS & METHODS

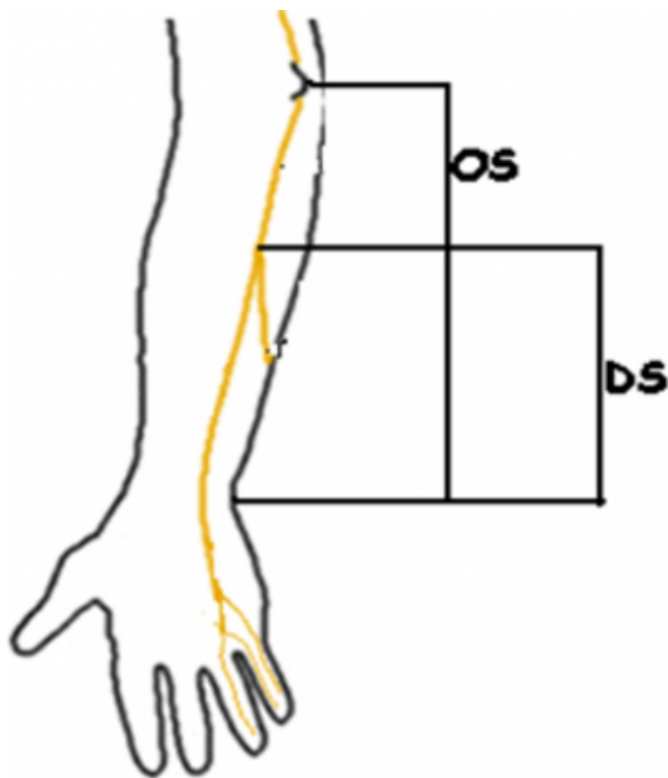
After institutional approval and informed consent, 100 male and female volunteers (equal gender distribution) were studied. Exclusion criteria include injury or deformity to the upper extremity. Initially, volunteers had their anthropometric data recorded, including age, gender, height and weight. Using high frequency (5-13MHz) linear transducer (LOGIQ e, GE), we scanned the medial aspect of

the left distal forearm. A transverse view of the ulnar nerve, the division point and the dorsal cutaneous branch were obtained.

The skin over the division point (D point) was marked in agreement between two anesthetists (Fig-1). Two measurements were taken to map out the ulnar nerve division point (Fig-2). A line was drawn from the ulnar styloid process to the olecranon and this distance was recorded as (OS), and the distance between the division point and the ulnar styloid process was recorded as (DS). SPSS version 15 (Chicago, USA) package was used for statistical analysis.

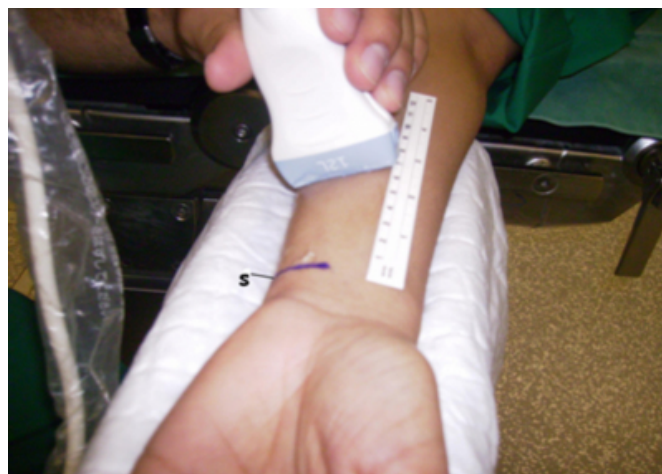**Figure 1**

Figure 1: Measurements: DS is the distance between ulnar nerve division point and ulnar styloid process. OS is the distance between olecranon and ulnar styloid process.



**Figure 2**

Figure 2: The transducer over the ulnar nerve division.

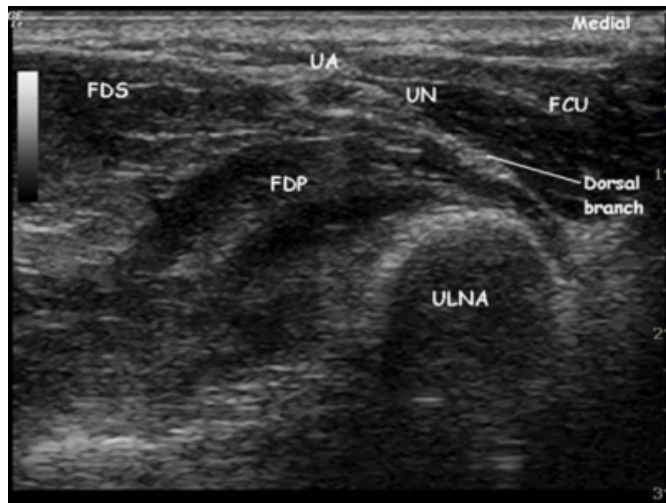


## RESULTS

All subjects completed the study. Demographic data are summarized as follow; mean age for males and females were  $32.9 \pm 8.9$  and  $39.3 \pm 10$  yr, mean weight were  $75.9 \pm 19$  and  $61.8 \pm 10$  kg, mean height were  $172.6 \pm 7.1$  and  $158.4 \pm 6$  cm respectively. The ulnar nerve and the dorsal cutaneous branch were visible in all scanned forearms. The ulnar nerve in the distal forearm appeared as hyper-echoic triangle with gross internal hypo-echoic punctuate and lying medial to the ulnar artery between the flexor carpi ulnaris, flexor digitorum profundus and flexor digitorum superficialis muscles (Fig-3). Moving the transducer distally, the ulnar nerve appeared to have a 'flank' (division –D point), the dorsal cutaneous branch consistently leaves the main ulnar nerve beneath the flexor carpi ulnaris muscle and winds around it (Fig-4). In the study group, male subjects have longer OS distance ( $26.8 \pm 1.6$ cm) than females ( $24.6 \pm 1.4$ cm) ( $p < .0001$ ). But there were no significant differences in the DS distance (male:  $5.9 \pm 1.4$  vs. female  $5.7 \pm 1.2$  cm) ( $p = .43$ ) or the DS/OS ratio (male:  $0.21 \pm .05$  vs. female  $0.23 \pm .04$ ) ( $p < .12$ ).

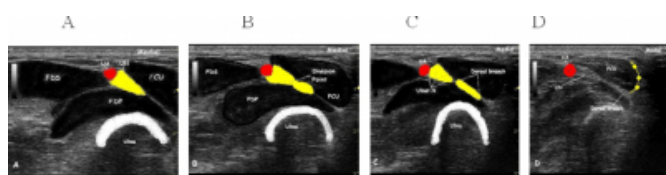
**Figure 3**

Figure 3: Short-axis view of the left distal forearm. The dorsal branch leaves the main ulnar nerve (UN) between the flexor carpi ulnaris muscle (FCU) and the flexor digitorum profundus muscle (FDP). (FDS) flexor digitorum superficialis muscle, (UA) ulnar artery.



**Figure 4**

Figure 4: Short-axis sonographic images of the left distal forearm.



Ulnar nerve before division.

Ulnar nerve has a flank at the division point.

The dorsal branch leaving the main ulnar nerve.

Yellow arrow indicates the course of the dorsal branch over the dorsal aspect of the flexor carpi ulnaris muscle.

FCU: Flexor carpi ulnaris, FDP: Flexor digitorum profundus, FDS: Flexor digitorum superficialis, UN: Ulnar nerve, UA: Ulnar artery.

## DISCUSSION

The dorsal cutaneous branch of the ulnar nerve is a terminal sensory branch. It arises proximal to the wrist and winds around the ulnar side of the forearm to supply sensation to the dorso-medial aspect of the hand and digits. In this study, we were able to visualize the division point and the dorsal coetaneous branch in our 100 volunteer subjects. Unlike the ulnar nerve which was identifiable in static images because of its typical “honeycomb” appearance, the dorsal coetaneous branch was best visualized in video clips.

Through its appearance passing under the fascial plane of the flexor carpi ulnaris muscle. Previous anatomical studies on cadavers have found that the dorsal branch originated at an average distance of 5.5 cm proximal to the ulnar head (7). In our study, we measured the distance between the ulnar nerve division point and the ulnar styloid process (the average length of the ulnar styloid process is 4.2 mm) (8). Our sonographic estimates of the DS distance (~ 5.9 cm and ~ 5.7 cm for males and females respectively) confirmed the previous anatomical findings. We found also that the DS distance has no correlation with other measured variables. In a previous report we have described the sonoanatomy

of some peripheral nerves of concern to anesthesiologists (9). To the best of our knowledge this is the first report on visualization of the dorsal cutaneous branch of the ulnar nerve using US technology.

In conclusion, high-end ultrasound machines with high frequency broad band transducers can reliably visualize the ulnar nerve division point and the dorsal coetaneous branch in the distal forearm.

## CORRESPONDENCE TO

A.Thallaj Riyadh 11471 P.O.Box 7805 Saudia Arabia  
athallaj@yahoo.com

## References

1. Boles CA, Kannam S, Cardwell AB. The Forearm; Anatomy of the muscle compartments and nerves. Am J Roent 2000; 174:151-159.
2. Botte MJ, Cohen MS, Lavernia CJ et al. The dorsal branch of the ulnar nerve: An anatomical study. J Hand Surg 1990; 15: 603-607.
3. Tindall A, Patel M, Forst M et al. The anatomy of the dorsal cutaneous branch of the ulnar nerve- a safe zone for positioning of the 6R portal in wrist arthroscopy. J Hand Surg 2006; 31: 203-205.
4. Schfthalter-zoppoth I, Gray AT. Ultrasound-guided ulnar nerve block in the presence of a superficial ulnar artery. Reg Anesth Pain Med 2004; 29:297-298.
5. Gray AT, Schfthalter-zoppoth I. Ultrasound guidance for ulnar nerve block in the forearm. Reg Anesth Pain Med 2004; 28: 335-339.
6. A. Kathirgamanathan, J.French, G.L. Foxall, J.G. Hardman, N.M. Bedford. Ultrasound anatomy of the ulnar nerve in the upper and forearm. Reg Anesth Pain Med 2007;32: 3.
7. Grossman J A, Yen L, Rapaport D. The dorsal cutaneous branch of the ulnar nerve. An anatomic clarification with six case reports. Chir Main; 1998;17: 154-8.
8. Van Der Heijden B, Groot S, Shuurman AH. Evaluation of the ulnar styloid length. J Hand Surg 2005;30: 954-959.
9. Thallaj A. Sonoanatomy Of The Brachial Plexus With Single Broad Band-High Frequency (L17-5 Mhz) Linear Transducer. Internet Journal of Anesthesiol 2007 Volume 11 Number 2.



**Author Information**

**Ahmed Thallaj, A.B.**

Consultant Anesthetist, King Khalid University Hospital

**Abdelazeem El-Dawlatly, M.D.**

Professor of Anesthesia, College of Medicine, King Saud University

**Ahmed Turkistani, FCPS**

Associate Professor of Anesthesia, College of Medicine, King Saud University

**Osama Zoraigi, MBBS**

Resident in Anesthesia, King Khalid University Hospital

**Mohamed Shraf al-deen, A.B.**

Registrar in Anesthesia, King Khalid University Hospital