

Pulmonary Artery Bronchial Fistula After Sleeve Lobectomy, A Case Report: A Fatal Complication Of Sleeve Lobectomy

J Abe, K Kanma, Y Saito

Citation

J Abe, K Kanma, Y Saito. *Pulmonary Artery Bronchial Fistula After Sleeve Lobectomy, A Case Report: A Fatal Complication Of Sleeve Lobectomy*. The Internet Journal of Pulmonary Medicine. 2000 Volume 2 Number 1.

Abstract

A rare case of pulmonary artery bronchial fistula after sleeve lobectomy for lung cancer is described. Non-aspergillous ulcerative bronchitis was the most considerable cause of death in our case. The patient was once saved by emergency thoracotomy, but finally he died from recurrent massive hemoptysis resulting from newly formed pulmonary artery bronchial fistula. Albeit our case had quite rarely clinical course, we must have a threat for this fatal complication even when we are managing non-immunosuppressive patients.

INTRODUCTION

Recently, a case of fatal massive hemoptysis resulting from ulcerative bronchitis after lung transplantation was reported¹. The patient described in that article was treated with immunosuppressive drugs such as corticosteroids and was forced to be in a condition in which he was easily infected to bacteria or fungus. Aspergillus infection sometimes forms ulcerative tracheobronchitis in immunosuppressive patients^{2,3}, and it is one of the major causes of anastomosis insufficiency in these lung transplanted patients. Ulcerative bronchitis also occur in non-immunosuppressive patients. In these cases, aspergillus infection is rarely observed. We report here our experience of massive hemoptysis owed to non-aspergillous ulcerative bronchitis which resulted in fatal pulmonary artery bronchial fistula after sleeve lobectomy for lung cancer.

CASE

A 69-year-old male was suffered squamous cell carcinoma developed from the intermediate trunk and referred our unit. He was performed right middle and lower sleeve lobectomy on 20 December, 1999. His postoperative course was poor because of sputum pooling around anastomosis site, and we had to remove them by bronchofiber scope several times at intensive care unit. In this examination, we found that white pseudomembrane was attached to overall anastomosis. Just two weeks after sleeve lobectomy, he had sudden massive hemoptysis. More than 2000ml of blood loss were observed

until we performed an emergency thoracotomy. (Figure 1)

Figure 1

Figure 1. (A) Left; Chest roentgenogram at the initial day of right sleeve middle and lower lobectomy. The trachea was shown a shift to the right and the left main bronchus was branched off with a larger angle than usual

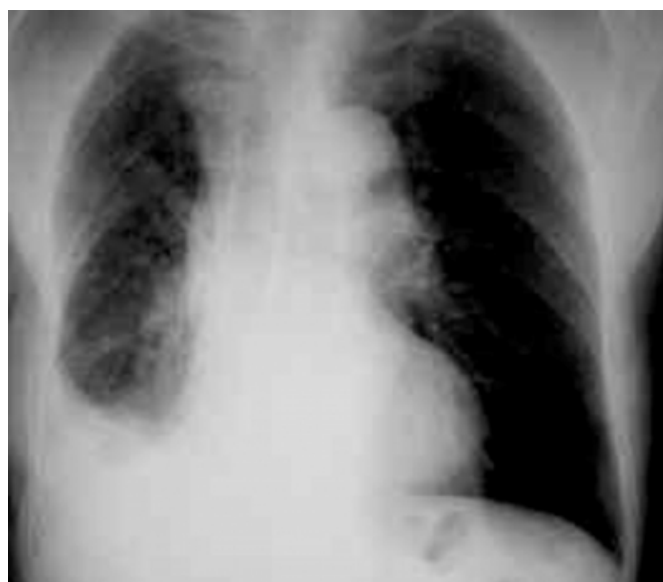
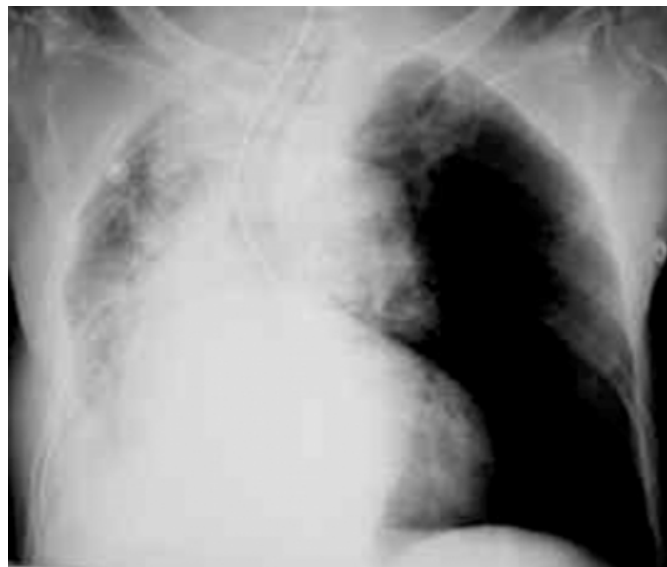
Figure 2

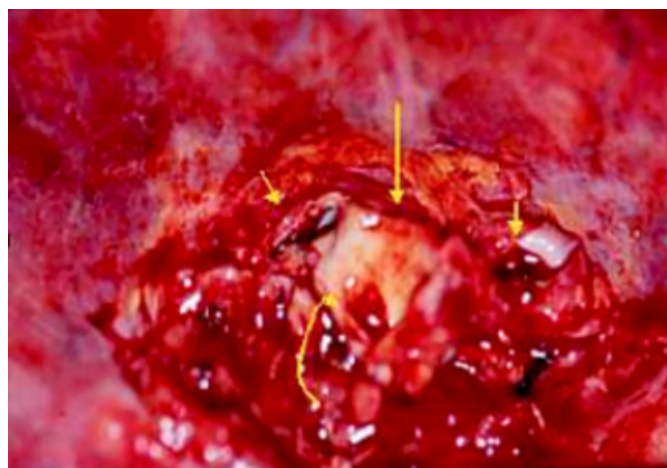(B) Right; After the first massive hemoptysis from the anastomosis site, a tracheal tube was placed in the proper position where the tip was over insertion into the left main bronchus to save left lung ventilation



As the operative findings, segmental branch of pulmonary artery communicated directly to tracheobronchial tree through the bronchial anastomosis (Figure 2).

Figure 3

Figure 2. Right main bronchus (straight arrow) and the branches of the pulmonary artery (arrow heads). A deep ulcer was formed in the mucus of the bronchial wall (curved arrow). The direct communication path was not demonstrated in this view

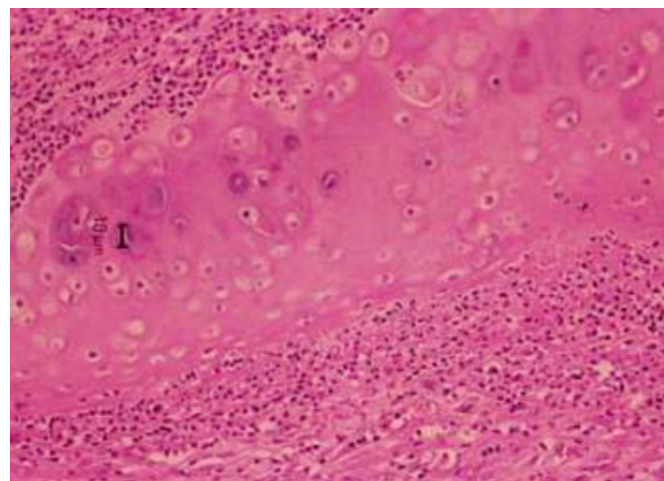


This completion pneumonectomy once saved the patient's life, but bronchopleural fistula and pyothorax was developed three days after emergency thoracotomy. A chest tube was inserted into his right hemithorax, and he was managed with antibiotics. A culture of the pleural effusion from his chest

tube revealed a multiplication of pseudomonas aeruginosa. He had a recurrent bleeding from the tracheal tube which was inserted in normal position now. Hemothorax also was observed ten days after the thoracotomy. The patient died 25 days after the first sleeve lobectomy. Newly formed pulmonary artery bronchial fistula was contemplated as the cause. The post mortem exam was not done. In the removed right upper lobe, aspergillous infection was not demonstrated. His bronchial cartilage around anastomosis was destructed by aggregated neutrophils (Figure 3) and which suggested us that his anastomosis insufficiency did not occur merely from ischemia of bronchial wall but from a severe ulcerative bronchitis.

Figure 4

Figure 3. The bronchial cartilages of the central airways in removed right upper lobe were destructed severely by aggregated neutrophils



Though some bacterial infection was considered as the cause, normal bacterial floras were observed in his sputum samples which were taken frequently before and after the initial operation. He did not take corticosteroids or other immunosuppressive drugs, and he did not suffered human immunodeficiency virus.

COMMENTS

Pulmonary artery bronchial fistula after sleeve lobectomy for lung cancer is rarely reported. Uncontrollable bleeding into the traheobronchial tree often causes sudden unexpected death₄. Ischemia of the anastomosis is considered one of the most significant factors of ulcerative bronchitis. Prolonging airway inflammation also affect progressive ulcer formation. Recent reported cases of ulcerative bronchitis are all occurred in patients after lung transplantation. We report here this may also occur in non-immunosuppressive patients.

We could not determine the causes of inflammation but at least aspergillus infection was not related in our case. Although our case was quite rare, clinicians who manage sleeve lobectomy for lung cancer should have a threat of this fatal complication.

References

1. Kessler, Massard, Warter, Wihlm, Weitzenblum. Bronchial-pulmonary artery fistula after unilateral lung transplantation: a case report [see comments]. J Heart Lung Transplant 1997;166:674-7.
2. Kramer, Denning, Marshall, Ross, Berry, Lewiston, et al. Ulcerative tracheobronchitis after lung transplantation. A new form of invasive aspergillosis. Am Rev Respir Dis 1991;1443 Pt 1:552-6.
3. Hamacher, Spiliopoulos, Kurt, Nicod. Pre-emptive therapy with azoles in lung transplant patients. Geneva Lung Transplantation Group. Eur Respir J 1999;131:180-6.
4. Kawahara, Akamine, Takahashi, Nakamura, Muraoka, Tsuji, et al. Management of anastomotic complications after sleeve lobectomy for lung cancer. Ann Thorac Surg 1994;576:1529-32; discussion 32-3.

Author Information

Jiro Abe, M.D.

Department of thoracic surgery, National Sendai Hospital

Keiji Kanma, M.D.

Department of thoracic surgery, National Sendai Hospital

Yasuki Saito, M.D.

Department of thoracic surgery, National Sendai Hospital