

Outcomes Of Endoscopic Quilting Of Nasal Septum Versus Nasal Packing Following Septoplasty

S Shah, S Kumari, B Pradhan, N Thapa

Citation

S Shah, S Kumari, B Pradhan, N Thapa. *Outcomes Of Endoscopic Quilting Of Nasal Septum Versus Nasal Packing Following Septoplasty*. The Internet Journal of Otorhinolaryngology. 2010 Volume 13 Number 2.

Abstract

INTRODUCTION:

Objective: To compare the outcomes of Endoscopic quilting of nasal septum with BIPP nasal packing following Septoplasty. MATERIALS AND METHODS A Prospective, longitudinal, comparative and a randomised study was conducted in 72 for 22 months at the Ganesh Man Singh Memorial Academy of ENT & HN Studies, IOM, TUTH, Kathmandu. Patients of both genders greater than or equal to 13 years undergoing Septoplasty for symptomatic DNS were included. In the BIPP packing group following Septoplasty nasal cavity was packed with BIPP. In the Septal suture group following Septoplasty septum was quilted under endoscopic guidance using 3/0 Vicryl. OUTCOME MEASURES: Pain, Demand of analgesia and significant reactionary haemorrhage requiring either repacking or blood transfusion. RESULTS: The mean post-operative pain on the first post-operative day was 2.58 in the Septal suture group and 4.51 in the BIPP pack group ($p < 0.001$) whereas on the second post-operative day was 2.20 and 3.40 respectively ($p = 0.005$). Six in the Septal suture group and twenty four in the BIPP pack group required demand of analgesia ($p < 0.001$). Two in the Septal suture group required packing for 'significant haemorrhage' ($p = 0.246$) and blood transfusion was required in none. CONCLUSION: Pain is significantly lower in the Septal suture group as compared to the BIPP pack group. Bleeding may occur and even if the patients are not packed there is no significant risk of haemorrhage. Septoplasty can be safely performed with Endoscopic quilting of nasal septum without BIPP nasal packing.

INTRODUCTION

Septoplasty is a frequently performed operation in Otorhinolaryngology clinics.¹ Nasal packing is performed as a routine by many surgeons following nasal surgery. The use of postoperative packing has been proposed to minimize postoperative complications such as haemorrhage,^{2,3} formation of synechiae and septal haematoma.⁴ There are no generally accepted standards regarding the materials that should be used for nasal packing, how long the packing should be left in place.⁵ The commonly used material are bismuth iodoform paraffin paste (BIPP), Telfa, paraffin gauze, Vaseline gauze, glove fingers, silastic sheets, Surgicel, Gelfoam, Merocel,⁶ gauzes impregnated with different antibiotics and fibrin glue.⁷ Other packing methods are pneumatic balloons left in place for various amounts of time, septal splints and through and through mattress sutures to approximate two mucosal septal flaps. Packing is associated with complications such as pain, profound vagal response, soft palate laceration, septal perforation and toxic-shock syndrome.⁸ Besides this there are many other complications

of using nasal packs.⁹

The most common morbidity associated with packing in post septoplasty patients is postoperative pain. There have been few number of studies suggesting that nasal packing should not be used as its removal from the nose causes serious discomfort and is painful.^{10,11,12} Many surgeons use suturing techniques to obviate the need for packing after surgery.¹³ Suturing the septum after septoplasty has the advantage of eliminating discomfort for the patients, has minimal complications and the hospital stay is less when compared with the nasal packing.¹⁴ Several suturing techniques have been described to approximate the mucosal flaps after septal procedures in order to reduce the complication rate. A number of centres are practicing endoscopic techniques to perform septal surgery. Septal suturing under endoscopic guidance is more precise and reduces the risk of needle trauma to the turbinates.¹⁵

MATERIALS AND METHODS

Study design: Prospective, comparative and randomised

study

Place of study: GMS Memorial Academy of ENT & HNS, TUTH, Kathmandu, Nepal

Duration: 22 months from 1st October 2008 to 31st July, 2010

Informed consent : Informed consent was taken for the study from all the patients.

Ethical clearance: Ethical clearance for the study was obtained from the Institutional Review Board.

Inclusion and Exclusion criteria: Patients of both gender with age greater than or equal to 13 years undergoing septoplasty for symptomatic Deviated Nasal Septum were included in the study whereas those undergoing septoplasty along with other concomitant surgery such as rhinoplasty, turbinoplasty, FESS and those undergoing septal surgery for epistaxis were excluded.

Sample Size: The sample size was calculated taking the confidence level of 95% and the confidence interval of 5 in a population of 88 and it came out to be 72 - 36 patients were included in the Septal suture and 36 in BIPP Pack group.

SURGICAL PROCEDURE

Septoplasty was performed under Local Anaesthesia in the usual manner. Following removal of deviated cartilaginous and bony portion of the nasal septum and straightening of the maxillary crest, (where required) haemostasis was secured. A simple randomisation was done from a box of coupon kept in the Operation theatre. In the BIPP Packing group a hemitransfixation suture using vicryl 3.0 was applied. Closure of incision was done. Bilateral nasal cavity was packed with a ribbon gauge soaked in BIPP and Soframycin Ointment. Bolster was applied.

In the Septal suture group septum was quilted under endoscopic guidance using 3/0 Vicryl. Prior to quilting few knots were placed at the distal end of the suture. Shaft of the needle and its natural curve were kept in same plane as handle of the needle holder. Initial suture was placed at the cartilaginous part of septum just anterior to mid part of middle turbinate under Endoscopic guidance. Needle was passed through septum to opposite side and after a few cm needle passed again to opposite side through the septum creating a quilting effect. Suture was then brought forward to the caudal end, stitch was placed so that the incision was closed by the suture. Septal suture was tied on itself through

the skin of the nasal vestibule so that toughness of the skin prevented suture from tearing through the tissue. Sutures were placed so that when suture was tightened it plicated the septal flaps together thereby removing the dead space.

Figure 1

Fig.1 Endoscopic Quilting suture in progress

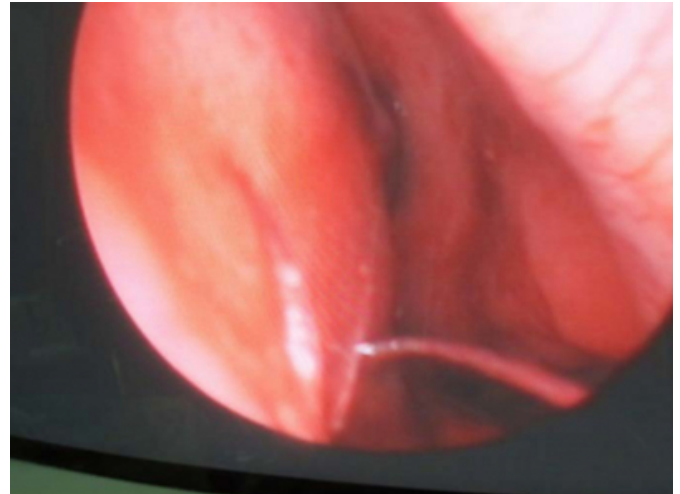

Figure 2

Fig.2,3 Endoscopic Quilting suture completed

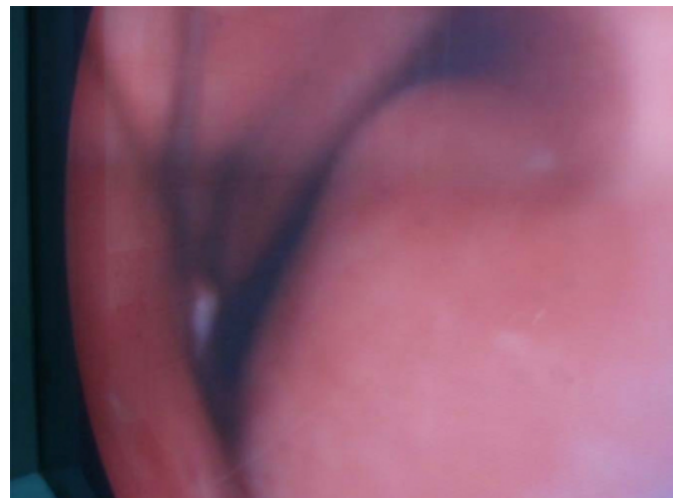
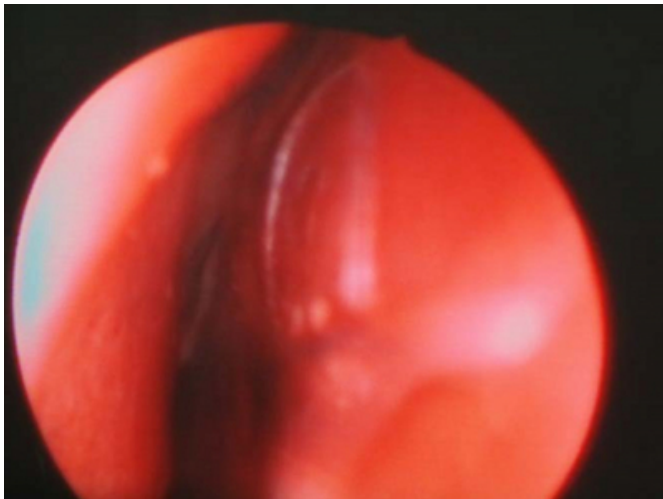


Figure 3



OUTCOME MEASURE

The patients were assessed for pain on the first and second postoperative day in the morning. Scoring was done after explanation of the Numerical Rating Scale. The demand of analgesia and in the BIPP pack group additionally pain experienced during pack removal was noted. Significant reactionary haemorrhage which required either repacking or blood transfusion was also noted. Analysis of the data was done using SPSS (Software Package for Social Sciences) 16 software. The p value of less than or equal to 0.05 was taken as significant in our study.

RESULTS

There were altogether 72 patients in our study which included 36 patients each in the Septal suture and the BIPP pack group. The age of the patients ranged from 13 years to 52 years. The mean age of the patients in the Septal suture group was 25.4 years whereas in the BIPP pack group was 23.8 years. There were 33 males and 3 females in the Septal suture group and 30 males and 6 females in the BIPP pack group. The mean post-operative pain of Septal suture group was 2.58 on the first post operative day and 2.20 on the second post operative day. The mean post-operative pain of BIPP pack group was 4.51 on the first post operative day and 3.40 on the second post operative day. Applying the unpaired t test p value was < 0.001 on first post operative day and p value was equal to 0.005 on second post operative day which is significant for both first and second post operative days.

Six patients in the Septal Suture group and 24 patients in the BIPP pack group required demand of analgesia over and above the regular dose of analgesics and applying the Chi

Square test, p value was < 0.001 and is significant.

Two patients in the Septal Suture group required packing in the post-operative period for 'significant haemorrhage'. None of the patients in the BIPP pack group had to be repacked. Applying the Fisher Exact test p value was 0.2464 and is > 0.05 and hence is not significant. Blood transfusion was not required in any of the patients in either the Septal suture or the BIPP pack group

DISCUSSION

The efficacy of post-operative nasal packing when compared with no packing has not been fully established. Its routine application because of the risk it carries and lack of firm evidence to support its efficacy, is called into question. No literature exists so far analyzing the outcomes using endoscopic guidance for quilting of nasal septum. In our study pain was significantly higher in the BIPP Pack group as compared to the Septal suture group on both the first and second post-operative days. This was in accordance with the results of Von Schoenberg and colleagues¹⁰ where the mean pain scores was significantly higher in the packed group (4.2) than the non-packed 48 group (2.8) in the first 24 hours, ($p < 0.001$) and Nunez et al¹¹ where the mean pain scores was 4.1 in the pack and 2.9 in the suture group, $p < 0.05$. The demand of Analgesia was significant in the BIPP Pack group as compared to the Septal suture group. ($p < 0.0001$). Though Von Schoenberg and colleagues¹⁰ have not evaluated the pain experienced on removal they state that the "removal of packing proved to be the most painful event during the postoperative period". This is also in accordance with our study where the average pain in BIPP pack group during removal was 5.83 which was highest as compared to the first and second post operative day. In our study haemorrhage requiring repacking was seen in 2 cases, both in the Septal suture group. 'p' value was equal to 0.246 and is not significant which means that even if the patients are not packed there is no significant risk of haemorrhage.

We had evaluated the early post-operative outcomes following Endoscopic quilting of the nasal septum as compared with the BIPP Pack group. As the other advantage of Endoscopic septal suturing technique is its precision and reduced risk of needle trauma to the turbinates, probably another study with a longer follow up and evaluation of other complications such as synechia and nasal perforation would be valuable.

CONCLUSION

Septoplasty can be safely performed with Endoscopic Septal suture without postoperative nasal packing. Pain is significantly lower in those with Septal suture group as compared to BIPP pack group. In Septal suture group following septoplasty and without postoperative nasal packing the patients do not have significant risk of haemorrhage as compared to the BIPP pack group. Endoscopic guided Septal suture without nasal packing is a valid alternative to nasal packing.

References

1. Yilmazer C, Sener M, Yilmaz I et al. Pre-emptive analgesia for removal of nasal packing: a double-blind placebo controlled study. *Auris Nasus Larynx* 2007;34:471–5.
2. Laing MR, Clark LJ. Analgesia and removal of nasal packing. *Clin Otolaryngol Allied Sci* 1990;15:339–42.
3. El-Silimy O. Inferior turbinate resection: the need for a nasal pack. *J Laryngol Otol* 1993;107:906–7.
4. Watson MG, Campbell JB, Shenoi PM. Nasal surgery: does the type of nasal pack influence the results? *Rhinology* 1989;27:105–11.
5. Lubianca-Neto JF, Sant'anna GD, Mauri M, Arrarte JL, Brinckmann CA. Evaluation of time of nasal packing after nasal surgery: a randomized trial. *Otolaryngol Head Neck Surg* 2000;122(6):899–901.
6. Kumar A, Omar B, Ajay N. Double-blind randomised controlled trial comparing Merocel with Rapid Rhino nasal packs after routine nasal surgery. *Rhinology* 2003;41:241–43. 56
7. Daneshrad P, Chin Gregory Y, Rice Dale H. Fibrin glue prevents complications of septal surgery: Findings in a series of 100 patients. *Ear Nose & Throat Journal* 2003;82:196–98.
8. Repanos C, McDonald S, Sadr AH. A survey of postoperative nasal packing among UK ENT surgeons. *European Archives of Oto-Rhino-Laryngology and Head & Neck* 2009;266(10):1575–77.
9. Fairbanks DNF. Complications of nasal packing. *Otolaryngol Head Neck Surg* 1986; 94:412–15.
10. Von Schoenberg M, Robinson P, Ryan R. Nasal packing after routine nasal surgery—is it justified? *J Laryngol Otol* 1993;107:902–5.
11. Nunez DA, Martin FW. An evaluation of post-operative packing in nasal septal surgery. *Clin Otolaryngol* 1991;16:549–50.
12. Illum P, Grymer L, Hilberg O. Nasal packing after septoplasty. *Clin Otolaryngol* 1992; 17: 158–62.
13. Lemmens W, Lemkens P. Septal suturing following nasal septoplasty, a valid alternative for nasal packing? *Acta Otorhinolaryngol Belg* 2001; 55(3):215–21.
14. Al-Raggad DK, El-Jundi AM, Al-Momani OS et al. Suturing of the nasal septum after septoplasty, is it an effective alternative to nasal packing? *Saudi Med J* 2007;28:1534–36. 58
15. Hari C, Marnane C, Wormald PJ. Quilting sutures for nasal septum. *J Laryngol & Otol* 2008;122:522–23.

Author Information

S. Shah

Senior Resident, B.P. Koirala Institute of Health Sciences

S. Kumari

Assistant Prof, B.P. Koirala Institute of Health Sciences

B. Pradhan

Professor & Head, Rhinology & Allergy Unit, TUTH

N.M. Thapa

Associate Prof, TUTH