

Isolated Granulocytic Sarcoma Of Head And Neck Region Without Any Marrow Involvement

A Patigaroo, S BANDAY, W RASHID, R MALIK, F Patigaroo, S Patigaroo

Citation

A Patigaroo, S BANDAY, W RASHID, R MALIK, F Patigaroo, S Patigaroo. *Isolated Granulocytic Sarcoma Of Head And Neck Region Without Any Marrow Involvement*. The Internet Journal of Otorhinolaryngology. 2010 Volume 13 Number 2.

Abstract

Granulocytic sarcoma is usually seen concomitantly with or subsequently to the appearance of leukemia but may rarely precede appearance of AML. Granulocytic sarcoma presenting as an isolated mass without any peripheral evidence of leukemia is very rare presentation and poses diagnostic and therapeutic challenges to the doctor. We report a case of fifty year old male presenting as isolated GS involving head and neck region without any marrow or peripheral evidence of leukemia.

INTRODUCTION

Granulocytic sarcoma (GS) is a localized tumour composed of immature cells of granulocytic series that infiltrate the extra medullary tissues. The most common sites of involvement are bone, lymph node and skin. Most cases of GS occur with acute or chronic leukemia but it can occur with other myeloproliferative or myelodysplastic syndromes. Rarely the tumour may be diagnosed before diagnosis of any hematological disorder; most of them are harbingers of existing or impending acute myeloid leukemia.

CASE REPORT

A 50 year old male, hypertensive, diabetic presented to SKIMS with complains of headache, vomiting, neck pain, and weakness of left lower limb. His examination revealed power of grade 1 in the left lower limb with left plantar extensor. The rest of the examination was normal. The baseline investigations of the patient including CBC, PBF, LFT, KFT, ECG and CXR were normal. MRI (fig 1), PET Scan (Fig 2) was done preoperatively.

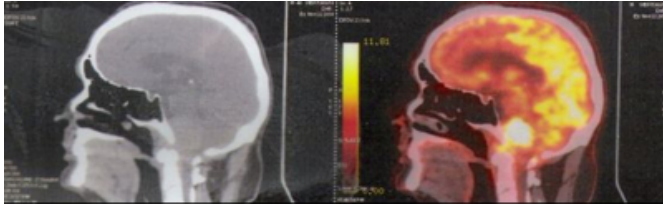
Figure 1

(Fig 1) MRI of the patient showed extra axial lesion in prepontine and premedullary region with extension into left CP angle superiorly and inferiorly up to the lower border of C2 level anteriorly with posterior extension below left occipital condyle and through left C2/C3 neural foramina

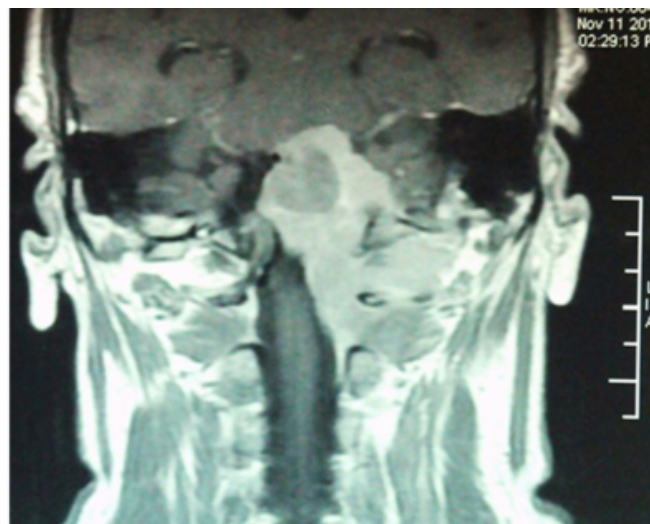

Figure 2

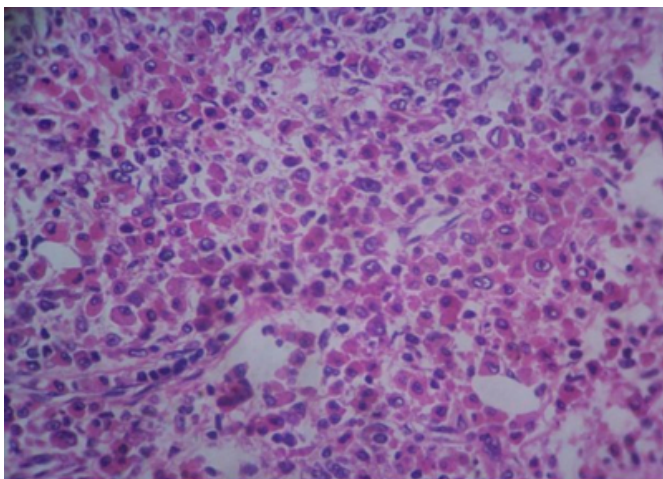
Fig 2 PET SCAN showed large lobulated FDG avid enhancing iso to hyperdense lesion in the prepontine and premedullary region measuring 3.4×2.6×3.8 cm with extensions, likely mitotic



Subsequently the patient was operated and underwent left posterior far lateral occipital craniotomy with removal of foramen magnum condyl and left posterior arch of C1 and left C2 hemilaminectomy and decompression of SOL was done. Histopathology(fig 3) was done

Figure 3

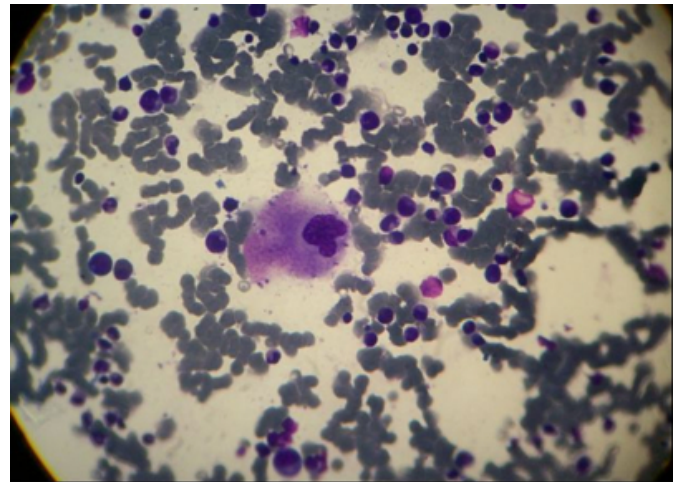
Fig 3. Histopathology showed Highly cellular tumour, diffusely infiltrating the meninges. It consisted of mixed population of large round cells with some with indented nuclei and numerous mature and immature eosinophils.



IHC revealed stain for CD43 strongly positive in most of the immature cells while smaller number of cells are positive for CD68and . Tumour cells are negative for CD1a and CD3.Tumour cells were positive for myeloperoxidase . A bone marrow examination (fig 4) was done .

Figure 4

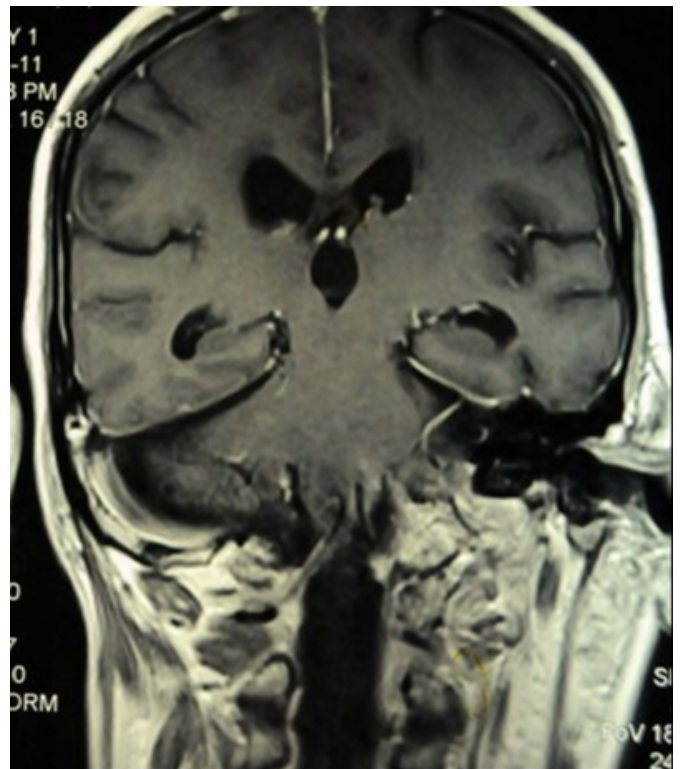
Fig 4. Bone marrow showing Cellular bone marrow with no increase in blasts



Thus a final diagnosis of isolated GS of head and neck region with no evidence of any leukemia was made. The patient received radiotherapy after surgery. He is doing well. Chemotherapy options are being discussed with the patient. MRI (Fig 5) after surgery and radiotherapy showed no definite evidence of residual or recurrent disease.

Figure 5

Fig 5. Post Op MRI with no residual disease



DISCUSSION

Granulocytic sarcoma was first described by the British physician A. Burns in 1811⁽¹⁾. This name is derived from the Greek word chloros (green), as these tumors often have a green tint due to the presence of myeloperoxidase. The link between chloroma and acute leukemia was first recognized in 1902 by Dock and Warthin⁽²⁾. However, because up to 30% of these tumors can be white, gray, or brown rather than green, the more correct term granulocytic sarcoma was proposed by Rappaport in 1967⁽³⁾. GS is a rare tumour composed of myeloid cells and has been commonly described in association with AML. It has been reported to occur concurrently with onset, during remission or at relapse⁽⁴⁾. It has also been described as an isolated lesion in non leukemic patients as described in our patients, however majority of these patients develop acute leukemia with a mean interval of 10.5 months from diagnosis⁽⁵⁾. GS can be located in soft tissue, breast, uterus, ovary, cranial or spinal dura, GI tract, lung, mediastinum, prostate, bone or other organs. Skin involvement (leukemia cutis) typically appears as violaceous, raised, nontender plaques or nodules. Gum involvement (gingival hypertrophy) leads to swollen, sometimes painful gums. In our patient it was located in the head and neck region which is a rare location. Symptoms of chloroma are related to their anatomic location; chloromas may also be asymptomatic and be discovered incidentally in the course of evaluation of a person with acute myeloid leukemia. There is often delay in diagnosis or even misdiagnosis due to equivocal histological features of disease. In fact in H/E stained histological sections the lesions are similar to large cell lymphoma and are frequently misdiagnosed as such.^(6,7) However, with advances in diagnostic techniques, the diagnosis of GS can be made more reliable. Traweek et. al described the use of a panel of monoclonal antibodies against myeloperoxidase, D68, CD43, CD20 to accurately diagnose chloroma⁽⁸⁾. Nowadays IHC using CD34 and Cd117 would be the mainstay of diagnosis. Cytogenetics analysis of AML patients with chloroma show that patients with t(8:21) are more prone than others to develop GS. Indeed 4.5 to 38

percent of patients with t(8:21) develop GS⁽⁹⁾. In their analysis of effect of early ant leukemic therapy in isolated GS IMRIE et.al showed that chemotherapy given at the diagnosis of GS delayed the onset of AML (medication-36 months vs. 6 months for non chemo) and was associated with better survival⁽¹⁰⁾. Our patient had undergone surgery followed by radiotherapy, showed good response clinically and radiologically. Chemotherapy options are being discussed with the patient.

CONCLUSION

Isolated GS is a rare tumour. Response to chemo therapy and prognosis is better in isolated GS than when associated with AML. Systemic chemotherapy should be given to all patients with isolated GS. Radiotherapy and surgery should be reserved for only palliative intent.

References

1. Burns A. Observations of surgical anatomy, in Head and Neck. London, England, Royce, 1811, p. 364.
2. Dock G, Warthin AS. A new case of chloroma with leukemia. Trans Assoc Am Phys 19:64, 1904, p. 115.
3. Rappaport H. Tumors of the hematopoietic system, in Atlas of Tumor Pathology, Section III, Fascicle 8. Armed Forces Institute of Pathology, Washington DC, 1967, pp. 241-247.
4. Litz CE, McClure JS, Brunning RD. Blood and bone marrow In : Damjanova I, Linder J, editors Anderson pathology. 10th edition, St Louis, MO: Mosby; 1996. P1063-1109
5. Tosi A, De Poli A, Fava S, et al. Undifferentiated granulocytic sarcoma: a case with epidural onset preceding acute promyelocytic leukemia, Haematologica 1995; 80:44-6
6. Meis JM, Butler JJ, Osborne BM, Maurtning JJ. Granulocytic sarcoma in non leukemic patient. Cancer 1986;58:2697-709
7. Aguiar RC, Pozzidh, Chamore DA. Granulocytic sarcoma of the ovary in non leukemic patient. Haematologica 1993;78:53-5
8. Traweek ST, Arber DA, Rappaport H, et al. Extramedullary myeloid cell tumors: an immunohistochemical and morphologic study of 28 cases. Am J Surg Pathol 17:1011-1019, 1993.
9. Tallman MS, Hakimian D, Shaw JM, Lissner GS, Russell EJ, Variakojis D. Granulocytic sarcoma is associated with t(8-21) in AML. Journal clinical oncology 1993;11:690-697
10. Imrie KR, Kovacs MJ, Selby D, Lipton J, Patterson BJ, Pantalon D, Paldre P, Ngar BY, Keating A. Isolated chloroma. the effect of early anti leukemic therapy

Author Information

Aamir Rashid Patigaroo, MBBS

Post Graduate Student, Department Of Medicine, SKIMS

SAKIB ZAFFAR BANDAY, MBBS

Post Graduate Student, Department Of Radiation Oncology, SKIMS

WASIM RASHID, MBBS MS (Ophthalmology)

Assistant Surgeon, Sub District Hospital

RAIS MALIK, MBBS

Post Graduate Student, Department Of Pathology, SKIMS

Fozia Amin Patigaroo, MBBS

Peoples Care Polyclinic

Suhail Amin Patigaroo, MBBS MS (ENT)

Dept Of ENT And Head And Neck Surgery, SKIMS