

First Transumbilical Transabdominal Preperitoneal Inguinal Hernia Repair in the Middle East

A Al-Dowais

Citation

A Al-Dowais. *First Transumbilical Transabdominal Preperitoneal Inguinal Hernia Repair in the Middle East*. The Internet Journal of Surgery. 2009 Volume 25 Number 1.

Abstract

Purpose: To report a case series of transumbilical transabdominal preperitoneal (TTAPP) inguinal hernia repair. **Materials and methods:** An initial study of 15 patients in King Khalid hospital - Najran - Saudi Arabia. All patients were subjected to Transumbilical Laparoscopic Transabdominal Preperitoneal (TTAPP) inguinal hernia repair using two ports (10mm & 5mm) inserted through the umbilicus. Hernia repair was performed with a typical TAPP technique with implantation of a polypropylene mesh.

Results:

The procedure was technically successful with placement of an additional third trocar transumbilically in five cases. Mean operative time was 80min. No blood loss and no intraoperative complications were observed. All patients were discharged on the 2nd postoperative day. Short follow-up demonstrated the patients to be without complaints or recurrence and with good cosmetic result.

Conclusion:

Transumbilical transabdominal preperitoneal (TTAPP) inguinal hernia repair is technically feasible and safe and yields good cosmetic result.

INTRODUCTION

Laparoscopic surgery has been focused on minimization of surgical trauma and improvement of cosmetic effect.

Since its development in the early 1990s, minimally invasive surgery has experienced substantial changes. Besides natural orifice transluminal endoscopic surgery (NOTES) and robotics, single-port laparoscopy (SPL) or laparoendoscopic single-site surgery (LESS) is part of the natural development of minimally invasive surgery.

This study was undertaken to evaluate our initial experience with transumbilical transabdominal preperitoneal (TTAPP) inguinal hernia repair.

MATERIAL AND METHODS

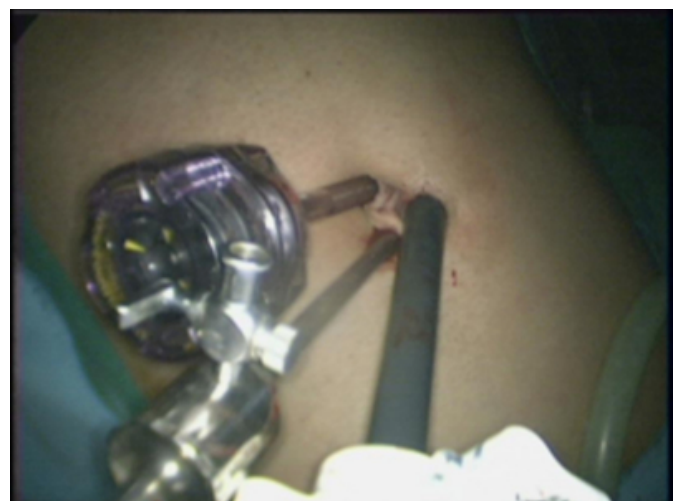This case series included 15 patients; all were males with a mean age of 25 years ranging from 22 to 35 years.

All the patients were referred for inguinal hernia repair during a 4-month period (Apr. 2009 – Aug. 2009) carried out by TTAPP by a single surgeon in King Khalid Hospital - Najran - Saudi Arabia.

A pneumoperitoneum was established. Two ports of 5mm and 10mm, parallel to each other with a bridge of skin between them, were introduced through the umbilicus, one port for the 10-mm 30-degree laparoscope and the other as working trocar (Fig. 1).

Figure 1

Figure 1: Ports in place.



The technical steps of a TTAPP inguinal hernia are very similar to that of a traditional laparoscopic TAPP inguinal hernia, and no special instruments are required.

The figures 2 & 3 show the creation of the peritoneal flap and the dissection medially to the pubic bone. The next step is to reduce the hernia sac from the inguinal wall. The indirect hernia sac is reduced and separated from the spermatic cord (Fig.4).

Figure 2

Figure 2: Incision of the peritoneum.

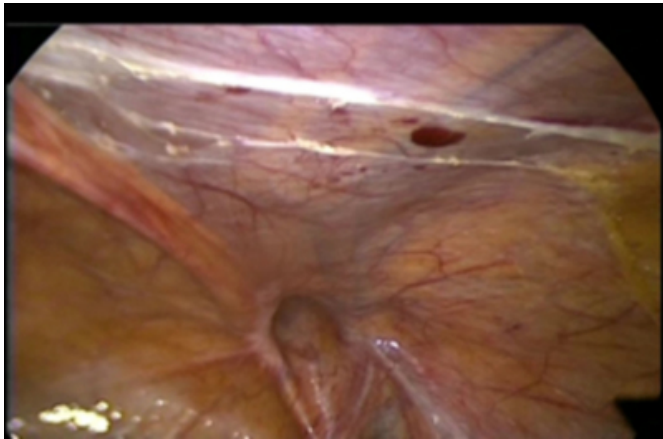

Figure 4

Figure 4: a- Left indirect inguinal hernia, b- Right direct inguinal hernia.

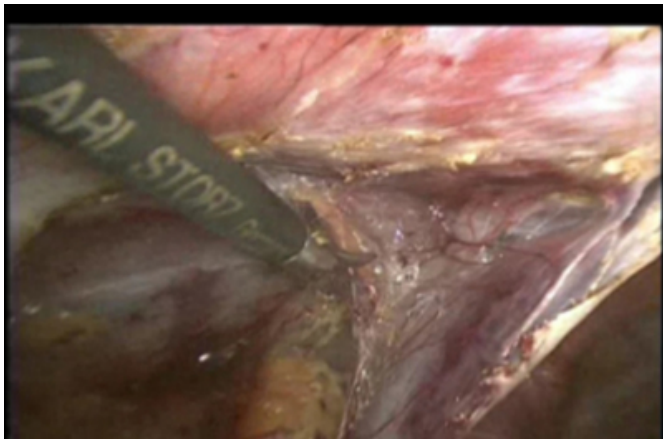
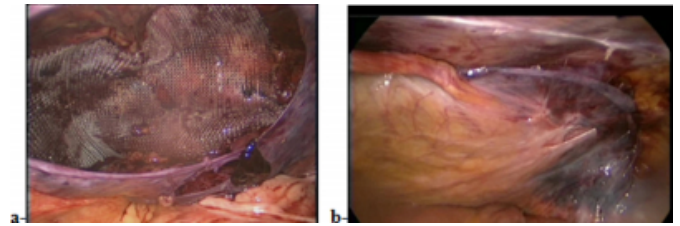


Figure 5

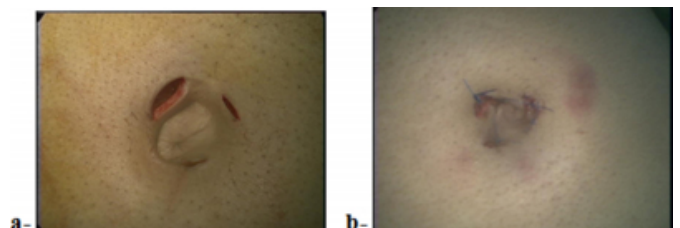
Figure 5: a- mesh in place, b- repositioning of the peritoneum.



After the entire posterior floor had been dissected, a (10cm x 15cm) polypropylene mesh was inserted through the 10-mm port and secured on each side using four to five spiral tacks (Fig. 5a). Then the peritoneal reflection was repositioned by spiral tacks (Fig.5b). At the end, the skin wounds were closed (Fig. 6).

Figure 6

Figure 6: a- transumbilical incisions, b- skin wounds.



{image:6}

RESULTS

All the surgeries were uneventful. Laparoendoscopic single-site surgery (LESS), in this case laparoscopic inguinal hernia repair, was successfully performed in all the patients.

In 5 cases, additional third ports were necessary for retraction to control the hernia sac, but all the ports were transumbilical.

The operating times ranged from 50 to 100min., with an average of 80 min.

No blood loss and no intraoperative complications were observed. All patients were discharged on the 2nd postoperative day. There was no wound infection and no mortality, and local analgesia with marcain was used in all patients. With short follow-up there was no recurrence and a good cosmetic result; the scar is hidden in the umbilicus (invisible or scarless surgery).

DISCUSSION

Many important advantages of laparoscopic surgery are

produced by preservation of the integrity of the abdominal wall, including less operative trauma and complications and better recovery and cosmetics [1]. The rapid improvement of laparoscopic techniques has evoked a surgery evolution. Scarless surgery is a rapidly progressing field as it combines cosmetic and minimally invasive advantages [2].

With the advent of natural orifice transluminal endoscopic surgery (NOTES), and the acknowledged limitations of the current technology, single port access (SPA) has emerged as available and more widely applicable minimally invasive technique.

Unfortunately, access to a single port that allows for SPA has been limited to small numbers of academic centers.

Nonetheless, single-incision cases were reported as early as in 1998 [3], and, recently, the term “single incision laparoscopic surgery” has been described for a large number of urologic, gynecologic, bariatric, and general surgical procedures, and its use seems to be rapidly growing. Annually, in the United States there are about 800,000 inguinal hernia operations performed, of which approximately 140,000 are performed laparoscopically by either the transabdominal (TAPP) or total extraperitoneal (TEP) approaches. While the indications and contraindications have yet to be described, the use of SILS techniques to perform laparoscopic inguinal hernia repairs has already been described [3].

Ger reported the first laparoscopic hernia repair in 1982 by approximating the internal ring with stainless steel clips [4]. The laparoscopic trans-abdominal preperitoneal (TAPP) repair was a revolutionary concept in hernia surgery and was introduced by Arregui [5] and Dion [6] in the early 1990s. Laparoscopic groin hernia repair can be done by TAPP approach and also by Total Extra Peritoneal (TEP) approach [7]. Both techniques of laparoscopic hernia repair reproduce the concept of Stoppa by placing a large mesh in the pre-peritoneal space to cover half of the abdominal wall and all the weak areas (myopectineal orifice of Fruchaud [8] including area of internal ring, Hasselbach's triangle and the femoral ring). The advantages of laparoscopic repair include the same decreased incidence of recurrence observed with the Stoppa technique with the added benefits of lesser pain, reduced discomfort, short hospital stay and early resumption of normal daily activities. Both techniques (TAPP and TEP) are safe, effective and have the same advantages. However, with TAPP a better view of the inguinal anatomy is achieved and the procedure also has a short learning curve [9]. TAPP

allows evaluation of opposite side as well. In patients with irreducible hernia contents, it is possible to reduce the contents under vision making the procedure simpler and easier [10].

In the literature, no paper was published before for transumbilical laparoscopic inguinal hernia repair in the Middle East. Single-port or single-incision laparoscopic inguinal hernia repair were reported by Jacob et al. [3], Menenakos et al. [12], Cugura et al. [13] and Matthew Kroh [14].

We believe, transumbilical laparoscopic inguinal hernia repair will be driven by consumer demand, and therefore, laparoscopic surgeons will need to become proficient with LESS procedures.

CONCLUSION

Transumbilical transabdominal preperitoneal (TTAPP) inguinal hernia repair is technically feasible and safe and yields good cosmetic results.

References

1. Cuesta MA, Berends F, Veenhof AA: The “invisible cholecystectomy”: A transumbilical laparoscopic operation without a scar. *Surg Endosc*; 2008; 22: 1211-3.
2. Guo W, Zhang ZT, Han W, Li JS, Jin L, Liu J, Zhao XM, Wang Y: Transumbilical single-port laparoscopic cholecystectomy: a case report. *Chin Med J (Engl)*; 2008 ; 121 (23): 2463-2464.
3. Jacob BP, Tong W, Reiner M, Vine A, Katz LB: Single incision total extraperitoneal (one SITE) laparoscopic inguinal hernia repair using a single access port device .*Hernia*; 2009; 13: 571-2.
4. Ger R: The management of certain abdominal herniae by intra-abdominal closure of the neck of the sac. Preliminary communication. *Ann R Coll Surg*; 1982; 64: 342-4.
5. Arregui ME, Davis CJ, Yucel O, et al.: Laparoscopic mesh repair of inguinal hernia using a pre-peritoneal approach: A preliminary report. *Surg Laparosc Endosc*; 1992; 2: 53-8.
6. Dion YM, Morin J: Laparoscopic inguinal herniorraphy. *Can J Surg*; 1992; 35:209-12.
7. McKernan B: Laparoscopic pre-peritoneal prosthetic repair of inguinal hernias. *Surgical Rounds*; 1992; 7: 579-610.
8. Fruchaud H: Anatomie chirurgicale des hernies de l'aïne. Doin, Paris, 1956; pp 299-303 and 336-342.
9. Cohen RV, Alvarez G, Roll S, et al.: Trans-abdominal or totally extra-peritoneal laparoscopic hernia repair? *Surg Laparosc Endosc*; 1998; 8: 264-8.
10. Bittner R, Leibl BJ, Jager C, Kraft B, Ulrich M, Schwarz J: TAPP - Stuttgart technique and result of large single center series. *J Min Access Surg*; 2006; 2(3): 155-159.
11. Menenakos C, Kilian M, Hartmann J: Single-port access in laparoscopic bilateral inguinal hernia repair: first clinical report of a novel technique. *Hernia*; 2009 Aug 7 [Epub ahead of print].
12. Cugura JF, Kirac I, Kulis T, Janković J, Beslin MB: First case of single incision laparoscopic surgery for totally

extraperitoneal inguinal hernia repair. Acta Clin Croat 2008, 47:249-252.

13. Kroh M, Rosenblatt S: Single-port, laparoscopic

cholecystectomy and inguinal hernia repair: first clinical report of a new device. J Laparoendosc Adv Surgical Tech A; 2009, 19(2): 215-217.

Author Information

Ali Mohammad Al-Dowais

Department of Surgery, King Khalid Hospital in Najran