

Cutaneous Nasal Nodule; a warning sign for Sinonasal Sarcoidosis

P Mekhail, M Abo-Khatwa, A El-Hawary, A Khan

Citation

P Mekhail, M Abo-Khatwa, A El-Hawary, A Khan. *Cutaneous Nasal Nodule; a warning sign for Sinonasal Sarcoidosis*. The Internet Journal of Head and Neck Surgery. 2008 Volume 3 Number 1.

Abstract

Sinonasal sarcoidosis can be associated with cutaneous sarcoid of the facial skin (lupus pernio). On this occasion we are reporting a case of lupus pernio with sinonasal involvement. A literature review is included, regarding the nature of sarcoidosis, (with special focus on the sinonasal involvement and lupus pernio), the clinical presentations, histological appearance and treatment modalities.

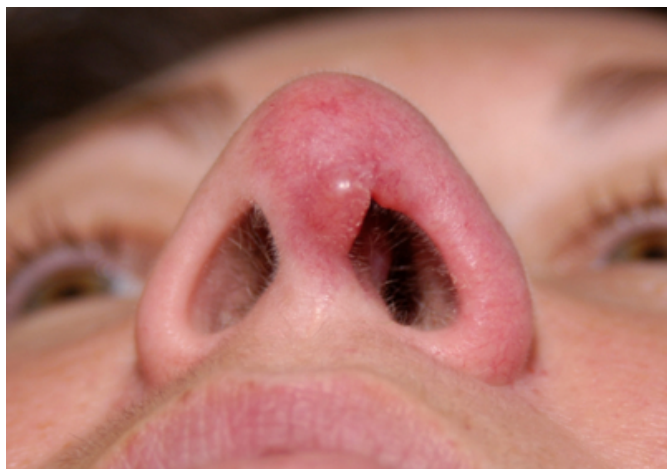CASE REPORT

A 40 year old caucasian female presented to the ear nose and throat department with sensation of nasal blockage, anosmia and recurrent sinusitis. The patient had a previous history of septoplasty four years ago and a further revision septoplasty, (in a different unit), one year later for continuing nasal blockage.

On examination of the patient, anterior rhinoscopy showed congested and swollen turbinates and an adhesion band between the right inferior turbinate and the septum. We observed a purplish nodule on the tip of her nose, (Figure 1).

Figure 1

Figure 1: "Lupus pernio" purplish nodule to the tip of the nose

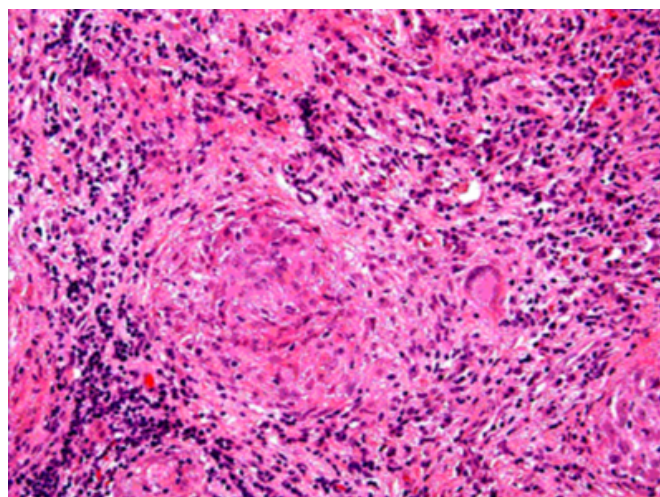


The patient stated that she had developed this lesion in the last six months. She was referred to the dermatology

department and following an incisional biopsy of the nodule, (Figure 2), the diagnosis of coetaneous sarcidosis "lupus pernio" was made.

Figure 2

Figure 2: Histological section of sarcoid tissue showing Langhans' multi-nucleated giant cells and Epithelioid cells with rounded and oval nuclei. (H&E;×200)



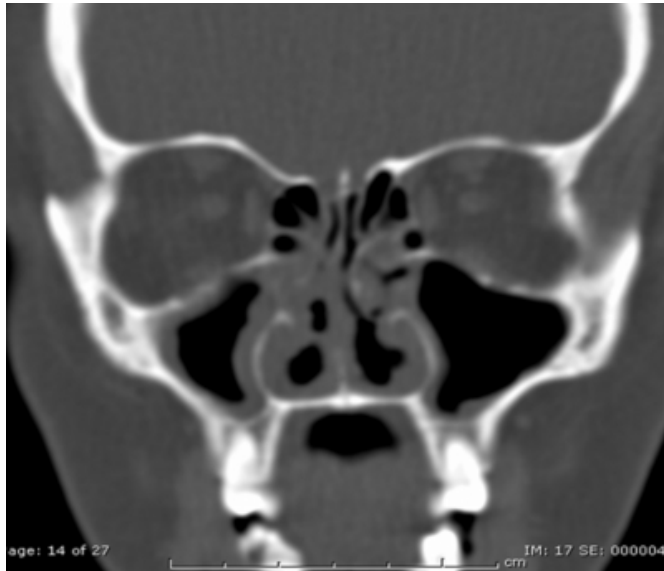Chest x-ray showed bilateral hilar lymphadenopathy. The patient was treated with Dermovate cream and Hydroxychloroquine 200mg twice daily for ten months. A follow up chest x-ray after completion of the course of treatment was normal as was the ACE level.

The lady was reviewed in the ENT clinic, and she reported worsening of her nasal symptoms. A CT of the para-nasal sinuses was done, and revealed mucosal thickening over the maxillary & ethmoidal sinuses and obstruction of both

osteo-meatal complexes, (Figure 3).

Figure 3

Figure 3: CT scan nasal sinuses showing blockage of the osteo-meatal complexes and mucosal thickening over the maxillary and ethmoidal sinuses



The patient was listed for functional endoscopic sinus surgery and had bilateral middle meatal antrostomies and antral washouts. Biopsies were taken from the hypertrophied inferior turbinates and these confirmed the diagnosis of sinonasal sarcoidosis.

DISCUSSION

Sarcoidosis is a chronic non caseating granulomatous disease, which has a slowly progressive nature and tends to involve multiple organs. About 90% of patients have chest involvement, most commonly in the lung parenchyma and hilar lymph nodes.^{12,13} Involvement of other sites such as liver, spleen, lymph nodes, larynx, salivary glands, bones, eyes, skin and central nervous system have also been reported.^{4,15,18}

The overall incidence of systemic sarcoidosis is 6-10 patients per 100,000 of the population; females are more affected than males.

The highest incidence of sarcoidosis has been reported in Sweden, where 64 persons per 100,000 of the population are affected.¹¹

The aetiology of sarcoidosis is unknown. It may represent a specific immunological disorder, as well as a non-specific response to bacterial, fungal or viral infections. Depression of T-Lymphocyte function and increase in the B-

Lymphocyte activity (high levels of IGA & IGG) is found in 50% to 75% of patients with sarcoidosis.³

Elevated titres of Epstein-Barr virus have been demonstrated in 79% of patients with sarcoidosis.⁸

Sarcoidosis of the nasal mucosa was first described by Boek in 1905.² Involvement of the sinonasal mucosa could be isolated or part of multi system involvement.¹⁰

Histopathology of sarcoidosis shows a non-caseating granuloma, consisting of epithelioid cells with pale, round or oval nuclei, macrophages and Langhans' giant cells. These giant cells appear larger than those seen in tuberculosis and contain more nuclei. Intracytoplasmic inclusion bodies such as asteroid and schaumann bodies may also be present in the giant cells.^{2,1}

Diagnosis of sarcoidosis relies on the physical examination, chest x-ray; the Kveim-Siltzbach skin test being 80-85% accurate with 2% false negative rate.¹⁹ Serological testing in the form of raised angiotensin converting enzyme is evident in approximately 60% of the patients with active sarcoidosis[[[.7, 11, 14]]] Biopsy of the clinically suspicious lesions is the most accurate diagnostic tool.¹⁴

Krespi introduced a new staging system for sinonasal sarcoidosis, which divided the disease into three categories according to the extent and the reversibility of the disease. Patients with stage I sinonasal sarcoidosis have limited, reversible involvement and often suffer from partial nasal obstruction as a result of hypertrophic turbinates and mucosal oedema. Stage II sinonasal sarcoidosis represent moderate but reversible disease with crustations, epistaxis, adhesions, limited single sinus involvement or mucoperiosteal thickening. Stage III sinonasal sarcoidosis is characterized with irreversible disease in the form of septal perforation, intranasal synechiae, nasal stenosis, saddle shape deformity or extensive sinus involvement.¹⁰

Lupus pernio is a cutaneous manifestation of chronic multi system sarcoidosis.⁹

Lupus pernio lesions are flat or minimally raised, violaceous in colour, and can affect nose, cheeks and ears. Around 50% of patients with upper respiratory sarcoidosis will develop lupus pernio of the skin.¹⁶

Sarcoidosis of the upper respiratory tract occurs in 6% of patients with generalized sarcoidosis. Sarcoid granuloma should be differentiated from tuberculosis, wegner

granulomatosis and leprosy.¹ Lupus pernio of the nose may also be so extensive that it could be mistaken for rhinophyma.⁵

Treatment of sarcoidosis depends on the extent of the presenting disease. Systemic manifestations such as lung involvement or arthritis require the use of corticosteroids or low dose of methotrexate. Sinonasal sarcoidosis requires prolonged use of steroid nasal sprays, nasal humidification, mucolytics and irrigation. Sinus drainage procedures may be necessary to manage acute or chronic sinusitis, not responding to medical treatment.⁵

Treatment of lupus pernio has been successful with hydroxychloroquine (antimalarial drug) and high potency topical steroid, (0.05% halobetasol propionate.)⁹ Intra lesion steroid injections have been reported with some success.²⁰

Treatment of lupus pernio with excision and split thickness grafting has been described but not recommended because of the possibility of graft loss, hyperpigmentation and cosmetic appearance.⁶ Carbon dioxide laser remodeling of lupus pernio has been reported in four patients with reasonable success.¹⁷

In this article, we are highlighting the strong correlation between lupus pernio of the facial skin and sinonasal sarcoidosis, as 50% of patients with upper respiratory sarcoidosis can develop lupus pernio. In this case report, our patient had two septal surgical procedures prior to attention being drawn to the lupus pernio on the dorsum of the nose.

We therefore recommend a thorough ENT examination in all patients with suspicious facial lesions, in order to prevent the potential for overlooking sarcoidosis of the upper respiratory tract.

References

1. Black JM (1966) Sarcoidosis of the nose. *J Laryngol Otol* 80:1065
2. Braun JJ, Gentine A, Pauli G (2004) Sinonasal sarcoidosis: review and report of fifteen cases. *Laryngoscope* 114:1960-3.
3. Casuccio JR, Yanagisawa E (1981) Diseases of obscure etiology: sarcoidosis, wegener's granuloma. *Otolaryngol Clin North Am* 14:331-45.
4. DeShazo RD, O'Brein MM, Justice WK, et al (1999) Diagnostic criteria for sarcoidosis of the sinuses. *J Allergy Clin Immunol* 103:789-95.
5. Goldenberg JD, Kotler HS, Shamsai R, Gruber B (1998) Sarcoidosis of the external nose mimicking rhinophyma: case report and review of the literature. *Ann Otol Rhinol Laryngol* 107:514-8.
6. Goldin JH, Jaward SMA, Reid AP (1983) Cutaneous nasal sarcoidosis-treatment by excision and split-skin grafting. *J Laryngol Otol* 97:1053-6.
7. James DG, Barker S, Jash D, et al (1982) Sarcoidosis of the upper respiratory tract. *J Laryngol Otol* 96:711-8.
8. James DG, Neville E, Walker A (1975) Immunology of sarcoidosis. *Am J Med* 59:388-93.
9. Khatri KA, Chotzen VA, Burrall BA (1995) Lupus pernio: successful treatment with a potent topical corticosteroid. *Arc Dermatol* 131:617-8.
10. Krespi YP, Kuriloff DB, Aner M (1995) Sarcoidosis of the sinonasal tract: a new staging system. *Otolaryngol Head Neck Surg* 112:221-7.
11. Lazarus AA (1982) Sarcoidosis. *Otolaryngol Clin North Am* 15:621-33.
12. Long CM, Smith TL, Loehrl TA, Komorowski RA, Toohill RJ (2001) Sinonasal disease in patients with sarcoidosis. *Am J Rhinol* 15:211-15.
13. Maillard AA, Goepfert H (1978) Nasal and paranasal sarcoidosis. *Arch Otolaryngol* 104:197-201.
14. Miglets AW, Vaill JH, Kataria YP (1977) Sarcoidosis of the head and neck. *Laryngoscope* 87:2038-48.
15. Milgram LM, Cohen AF (1996) Nonpulmonary sinonasal sarcoidosis with intracranial invasion. *Otolaryngol Head & Neck Surg* 114:163-5.
16. Neville E, Mills RGS, Jash DK, MacKinnon DM, Carstairs LS, James DG (1976) Sarcoidosis of the upper respiratory tract and its association with lupus pernio. *Thorax* 31:660-4.
17. O'Donoghue NB, Barlow RJ (2005) Laser remodeling of nodular nasal lupus pernio. *Clin Dermatol* 31:27-9.
18. Saboor SA, Johnson N (1992) Sarcoidosis. *Br J hospital Medicine* 48:293-302.
19. Siltzbach LE, Blaugrund SM (1963) Sarcoidosis of the mucosa of the respiratory tract. *Ann Otol Laryngol* 72:923-39.
20. Sullivan RD, Mayock RL, Jones R (1953) Local injection of hydrocortisone and cortisone into skin lesions of sarcoidosis. *JAMA* 152:308-12.
21. Urquhart AC, Bodenstein NP, McIntosh WA (1990) Sarcoidosis with nasal obstruction and deformity; a case report. *S Afr J Surg* 28:107-9.

Author Information

Peter I. Mekhail, MRCSEd

ENT Department, Glan Clwyd Department

Mohamed M. Abo-Khatwa, FRCS(ORL-HNS)

ENT Department, Glan Clwyd Department

Amr El-Hawary, MSc.

General Surgery Department, Glan Clwyd Department

Anwar Khan, FRCSEd

ENT Department, Glan Clwyd Department