Unsuspected Metastatic Choriocarcinoma Presenting As Gastrointestinal Bleeding

A Balci, S Eren, E Cebeci

Citation

A Balci, S Eren, E Cebeci. *Unsuspected Metastatic Choriocarcinoma Presenting As Gastrointestinal Bleeding*. The Internet Journal of Gastroenterology. 2000 Volume 1 Number 2.

Abstract

Although metastatic lung choriocarcinoma causes respiratory symptoms, it can be manifested with atypical signs. A 20 years old patient is reported who presented with features of gastrointestinal bleeding due to polypoid choriocarcinoma of the stomach. Bloody vomiting are usually caused by peptic disease but may also be secondary to metastasis to the lung. Failure to recognize this as being to choriocarcinoma may led to a delay in diagnosis and effective treatment.

ÖZET

Her ne kadar metastatik akciger koryokarsinomu respiratuar semptomlara neden olursa da, atipik bulgularla da kendini gösterebilir. Midenin polipoid karsinomu nedeniyle gastrointestinal kanamayla basvuran 20 yasindaki bir hasta takdim edilmektedir. Hematemez genellikle peptik hastaliklardan ötürü ortaya çikar. Ancak akcigere metastazdan dolayi da olabilmektedir. Bunun koryokarsionama nedeniyle olabilecegini düsünememek tanida ve etkin tedavide gecikmeye neden olabilir.

INTRODUCTION

Gestational choriocarcinoma is an epithelial malignancy of trophoblastic cells. This uncommon condition arises in 1 in 20.000 to 30.000 pregnancies in the USA and much more common in Asia and Africa, e.g. 1 in 2500 pregnancies in Ibadan. Preceding conditions: 50 % in hydatiform moles, 25 % in previous abortions, 22 % in normal pregnancies and the rest in ectopic pregnancies and genital and extragenital teratomas . The choriocarcinoma grows rapidly, with widespread hematogenous dissemination which may be fatal before the diagnosis of choriocarcinoma is even suspected . Our 20 years old patient with pulmonary metastatic choriocarcinoma had only stomach polypoid lesions that pointed to a suspected primary choriocarcinoma. To our knowledge, this is the first case report of a metastatic pulmonary choriocarcinoma presenting as gastrointestinal bleeding. A rare tumor, primary choriocarcinoma of the stomach occurs in postmenopausal females . Only a few articles in the English-language literature have discussed the role of thoracotomy in the management of patients with pulmonary metastatic choriocarcinoma .

CASE HISTORY

A 20 years old woman was given 8 units blood transfusion for gastrointestinal bleeding after she was referred with severe bloody vomiting. The general surgery team decided to perform immediate laparotomy. The stomach was opened with 4 cm gastrostomy and the surgical team found 1000 cc clotted blood in the stomach. The examination of the stomach lumen after the aspiration of clotted blood showed an oozing polypoid lesion at the antrum. The polyp was excised in the manner of wedge resection with an 1 cm intact tissue margin. Pathological examination of the excised polyp showed a choriocarcinoma with light microscope. The patient was transferred to the Obstetric and Gynecology Department. During pelvic ultrasonographic examination, minimally liquid was seen in uterine cavity. Beta HCG in the serum was 68 IU.

Endometrial biopsy pointed out chronic cervicitis. The diagnosis of non-specific endometritis was established with curettage. The patient had undergone an abortus at her third month two years ago. In the past year, she had been complaining frequently during menstruation. There was no respiratory suffering (dyspnea, coughing, hemoptysis) clubbing, jaundice, or lympadenopathy. Her temperature was 36.5 C. Jugular venous pressure was not raised, there was no peripheral edema. Abdominal ultrasound showed a normal liver and a normal sized non-gravid uterus, no mass. A chest radiograph showed a mass in right lower zone. The case was accepted as non - trophoblastic disease and referred to our

Thoracic Surgery Department. The mass in lower lobe was peripheral and no bronchoscopy was performed (FIGURE 1 and 2).

Figure 1

Figure 1: A chest X-ray of a young woman with metastatic lung choriocarcinoma in right lower lobe.

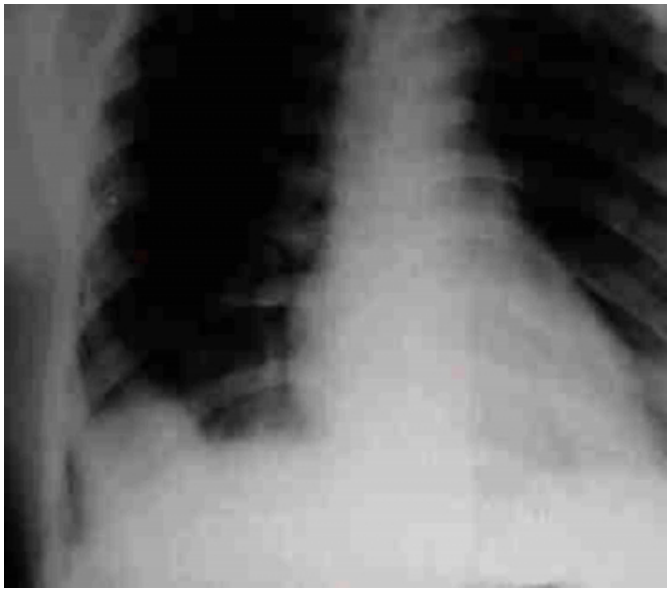

Figure 2

Figure 2: Thorax CT of the same patient. Peripheral lesion and no chest wall invasion.

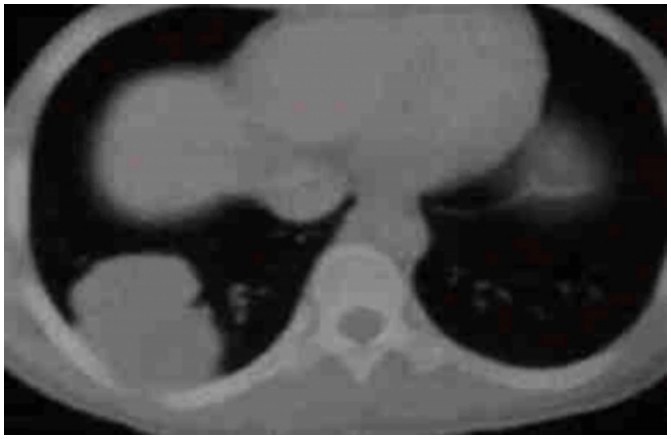

It was concluded that an excisional biopsy with lobectomy was appropriate instead of needle biopsy (due to a mass greater than 5 cm in diameter). Pathologic examination of right lower lobe showed a mass of about 8 x 7 x 5 cm diameters and 3 cm distance to the main bronchus. It was a choriocarcinoma in both, light microscopy and immuno-histochemical staining. No 8 and 12 lymph nodes were big due to reaction. No brain metastases in postoperative cranial CT were found. The patient was referred again to the Obstetric Department for cytotoxic therapy.

DISCUSSION

In patients with control of the primary tumor and metastases confined to lungs, surgery can be used to resect all visualized or palpable metastases . Pulmonary metastases occur in as many as 70 % of patients with trophoblastic tumors, and 90 % of those are cured with chemotherapy. Thus the indications for surgery are limited. Some patients undergo thoracotomy for diagnosis but the usual indication is therapeutic . Mazur reported two patients who presenting as different histological appearance of choriocarcinoma after treatment with chemotherapy metastatic to the lung. Surgical excision appeared to be curative in both patients . Most authorities agree that the patient should have received multiagent chemotherapy previously to thoracotomy. There should be no evidence of tumor elsewhere in the body, and the lung tumor should be a solitary lesion limited to one lung.

Jones demonstrated that the interval between the antecedent pregnancy and the start of chemotherapy was 2 years or more in the three patients who died. Also, at the time of thoracotomy, more than one tumor nodule was known to be present in two of the patients who died. He claimed that the thoracotomy can be curative in most of these patients with complete remission being achieved in some of them without the need for additional chemotherapy (6). In our patient there was a two-year interval between abortus and diagnosing time. However, the patient answered with a good response to both, operation and chemotherapy with no remission or metastasis during the following 7 months.

A third of patients may present with signs of metastases in the lung (80 %). Pulmonary choriocarcinoma can be manifested with increasing dyspnea, central chest pain and a dry cough occasionally accompanied by a little hemoptysis. It may rarely present as endobronchial carcinoma or unilateral spontaneous pneumothorax , while the vaginal bleeding the most common symptom in the genital system. In our case, there were no respiratory or genital symptoms excepting polymenorrhea.

For the diagnosis of choriocarcinoma, Liaw firstly applied color Doppler imaging and found some special ultrasound characters of lung choriocarcinoma but had to confirm the diagnosis with percutaneous ultrasonically guided needle aspiration.

In choriocarcinoma, serum human chorionic gonadotropin

levels are raised, but no increase could be found particularly in tumors that occurred a long time after pregnancy . In our case, HCG levels are 68 and 72 IU in serum pre and postoperatively.

Xu performed resections of pulmonary metastatic choriocarcinoma in 43 metastatic drug resistant patients. There were no deaths in the immediate postoperative period and overall 5-year survival was 50 % (4) .

Gastrointestinal bleeding in young women is rare and generally due to acid peptic disease of the stomach. One should keep in mind the possibility of gastrointestinal bleeding occurring secondary to stomach choriocarcinoma and its lung metastasis, as well as pneumothorax and endobronchial carcinoma.

Choriocarcinoma should be considered even when a primary tumor is not detectable and when serum HCG levels are normal (10).

CORRESPONDENCE TO

Dr. BALCI: Dicle University School of Medicine Dept of Thoracic & Cardiovasc Surg 21280 Diyarbakir TURKEY +904122620011 (home tel.) +904122488008 (16) / 4506 (business tel.) +904122488440 (fax) abalci@dicle.edu.tr

References

1. Robbins. Pathologic Basis of Disease. In: Gestational and Placental Disorders. Philadelphia: WB Saunders, 1989: 1170 - 80.
2. Liaw YS, Yang PC, Yuan A et al. Ultrasonography and color doppler imaging of metastatic pulmonary choriocarcinoma. Chest 1993; 104: 1600-1
3. Wurzel J, Brooks JJ. Primary gastric choriocarcinoma: immunohistochemistry, postmortem documentation, and hormonal effects in a postmenopausal female. Cancer 1981; 48:12, 2756-61.
4. Xu LT, Sun CF, Wang YE. Resection of pulmonary metastatic choriocarcinoma in 43 drug resistant patients. Ann Thorac Surg 1985; 39:3,257-9.
5. Shields TW. General Thoracic Surgery. In. Putnam JB, Roth JA. Secondary tumors in the lungs. Malvern: Williams & Wilkins, 1994: 1334 -52.
6. Jones BW, Romain Kathleen, Erlandson R et al. Thoracotomy in the management of gestational choriocarcinoma. Cancer 1993; 72:2175-81.
7. Mazur MT. Metastatic Gestational Choriocarcinoma. Unusual pathologic variant following therapy. Cancer 1989; 63: 1370 - 77
8. McLeod DT. Gestational choriocarcinoma presenting as endobronchial carcinoma. Thorax 1988; 43: 410-1.
9. Oullette Denise and Inculet Richard. Unsuspected metastatic choriocarcinoma presenting as unilateral spontaneous pneumothorax. Ann thorac surg 1992; 53: 144-5.
10. Nabers J, Splinter TAW, Wallenburg HCS et al. Choriocarcinoma with lung metastases during pregnancy with successful delivery and outcome after chemotherapy. Thorax 1990; 45: 416-8.

Author Information

Akin E Balci
Assistant Professor, Thoracic and Cardiovascular Surgery, School of Medicine, Dicle University

Sevva Eren

Erdogan Cebeci