

# Complication Of Venous Cut-Down: Migration Of Catheter That Remained In The Vein

M Edis, T Ege, E Duran

## Citation

M Edis, T Ege, E Duran. *Complication Of Venous Cut-Down: Migration Of Catheter That Remained In The Vein*. The Internet Journal of Emergency Medicine. 2004 Volume 2 Number 2.

## Abstract

The patient, who was followed up with a diagnosis of amyotrophic lateral sclerosis (ALS), was inserted a catheter with the approach of cephalic vein cut-down operation on left arm in order to enable parenteral nutrition and medical treatment. After the treatment, while the catheter was being pulled out, it was broken and a large part of it remained in the vessel. On the postero-anterior (PA) x-ray, the catheter was seen and it was taken out of the subclavian vein through venotomy in a surgical operation. The case was examined in accordance with the related literature.

## INTRODUCTION

Central venous catheters are commonly used safely for the patients who require nutritional support, hemodynamic monitorization, temporary transvenous cardiac pace-maker, plasmapheresis or hemodialysis in intensive care unit (ICU) and in operating room. While they provide the replacement of fluid and blood products in ICU, they are also the common way to supply the patients with total parenteral nutrition therapy. Internal and external jugular vein, subclavian vein, femoral vein, and brachial vein are frequently used for venous cannulation. Seldinger is the technique commonly preferred in the placement of central venous catheters. Venous cut-down technique is only possible when the application of percutaneous insertion of the catheters cannot be made. In this study, a rare complication in a patient who underwent central catheterization with venous cut-down technique was examined within the lights of findings in the related literature.

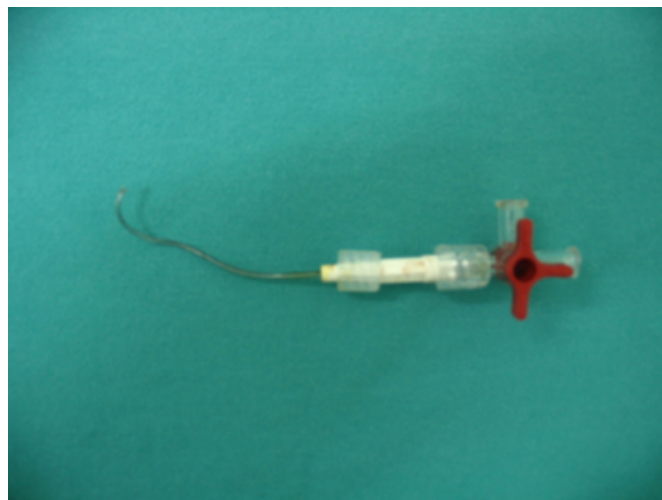
## CASE REPORT

32 years old male patient was brought to the emergency service with a severe complaint of serious dyspnea and we detected that the patient had ALS diagnosis twelve years ago, he was bed-dependant and could not swallow for three years. After his hospitalization, central catheterization had been used with the cephalic vein cut-down technique on his left arm for the medical therapy. Just before the completion of the treatment of the patient, the catheter had broken off and the large part of it had remained in the venous system of him. As a result, we were required to consultate the patient

(Picture 1).

## Figure 1

Picture 1: A outside part of Cava-fix catheter after it is broken down

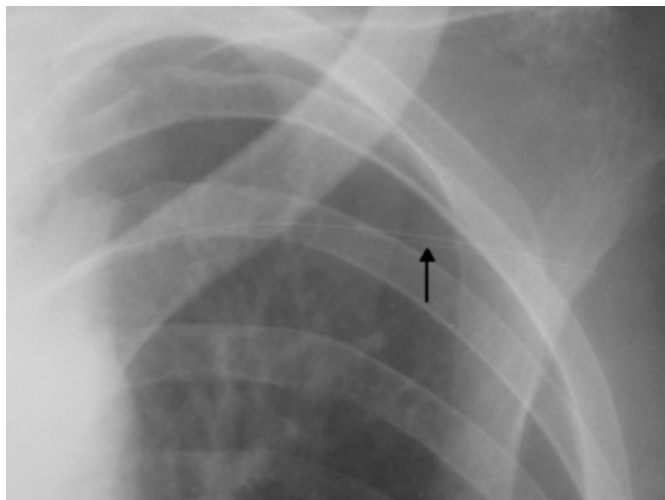


During his first physical examination, the patient was conscious, cooperative, and quadriplegic. He had also taken mechanic ventilator treatment via tracheostomy. There was an insertion area of venous cannula with the antecubital cut-down incision on the left arm. With an immediate anteroposterior chest graphy, it was detected that the catheter was lying from antecubital region to proximally into the vein. This area was explored with a different incision from the midline of the left arm but catheter was not in the cephalic vein. After taking a new chest graphy of the patient in his bed, it was seen that the broken part of the catheter had

been located in the axillary vein (Picture 2a and 2b).

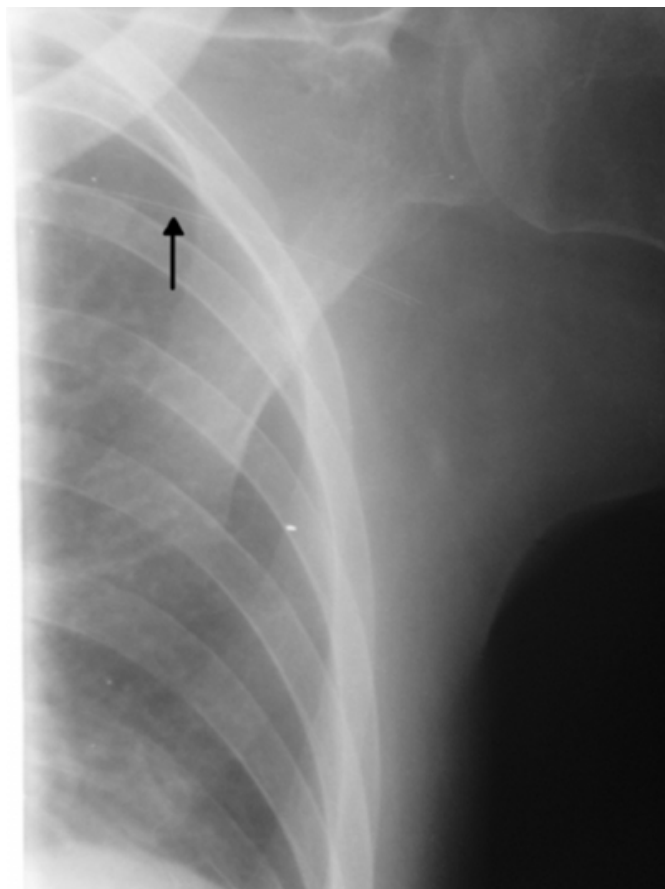
### Figure 2

Picture 2a: A view of the broken Cava-fix catheter on posteroanterior chest radiography



### Figure 3

Picture 2b: A view of the broken Cava-fix catheter on posteroanterior chest radiography

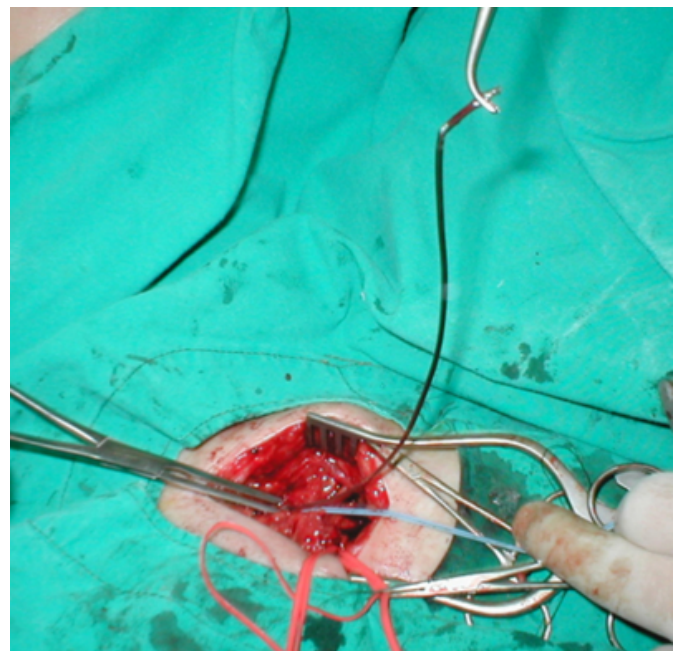


After that, with the local anesthesia to the left subclavian area, subclavian vein was found with a different incision and

the catheter was found within the subclavian vein when the subclavian vein was turned and hanged. Then transverse venotomy was performed to subclavian vein. The catheter with the surrounding fresh thrombus material was taken out with the help of a clamp from the vein( Picture 3a and 3b). Following that, the venotomy made to subclavian vein was mended by with polypropylen suture and the incision was routinely closed.

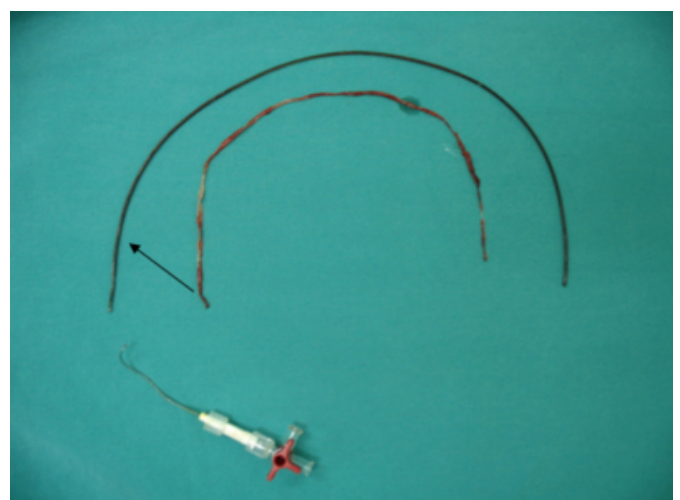
### Figure 4

Picture 3a: Taking out of the catheter with the help of a clamp



### Figure 5

Picture 3b: Parts of Cava-fix catheter and cover thrombus surrounding it (inside)



### **DISCUSSION**

Various complications such as thrombus, vascular trauma, hemothorax, pseudoaneurysm, arteriovenous fistula, local and systemic infection are witnessed among the ICU patients who have undertaken central venous catheterization- a common technique applied in the intensive care units- with the aim of parenteral nutrition or fluid replacement. To decrease these complications, this technique should be performed by the experienced individuals in sterile conditions under the local anesthesia.

Central venous catheters, most of the time, are inserted by the implementation of Seldinger technique. Internal jugular, external jugular, subclavian, femoral, and brachial veins are the most frequent chosen areas for the insertion of venous cannula. The area chosen for the insertion is dependant to the patient's situation, experience and the preference of the physician. The region of subclavian vein is cannulated more easily in the volume displacement with a high success rate. High pneumothorax risk and presence of bleeding are the disadvantages of this area. Internal jugular vein is cannulated with a high success rate just like subclavian vein. The main advantages of the internal jugular vein catheterization are the low probability of pneumothorax and being able to make compression during the time of bleeding. Formerly, when percutaneous insertion applications were so rare, catheters sent surgically through the cephalic and saphenous vein had been used in the aim of central catheterization. Despite the fact that this technique left its place to percutaneous insertion, some physicians still, though rarely, rely on cut-down technique. Percutaneous central venous insertion is much more preferred technique compared to the venous cut-down technique for the fact that it has more successful results, low infection rates and it needs a shorter time-span for its completion.

In our case, catheterization had been done to the cephalic vein surgically with the cut-down technique. In this technique, it is known that a slight ligation is made with the catheter and the vein by a suture that is sent to proximal after the venotomy and by this way the catheter is made stable. When the catheter usage becomes unnecessary and when it needs to be taken out, it should be taken out carefully and slowly. In our case, as the catheter had been pulled so hard during the taking out process, the catheter had been broken off within the ligatured area and a large part of it remained in the vein. With the chest diagraphy, it was realised that one edge of the catheter was lying in the mid-part of the arm. Upon that an exploration was made on the old incision area

however the catheter was not be able to found it the located area shown on the diagraphy. Then taking a new diagraphy, we detected the location of the catheter. The catheter which is expected to move so fast in lumen had moved too slowly and it remained there by holding on the vessel wall in the subclavian area. When the catheter was taken out from its location, it was seen that the major factor for the situation was the fresh thrombus material surrounding it ( Picture 3b).

Such complications in relation with the breaking off the catheter in percutaneous applications are fairly rare because during this procedure catheter is sutured and ligatured merely on the surface of the skin. Catheter can easily be removed from its place when this suture is taken out. If the catheter is thought to be broken off during its taking out process, the situation should be evaluated by chest graphy, the parts of the catheter and their locations should be identified and the following application should be planned. Meanwhile, it should not be forgotten that the catheter part inside the lumen will move in the same direction of the blood flow in the vein. In our case, we determined the fairly slight movement of the catheter proximally in the vein. In such a case, the catheter was taken out before it reached to pulmonary artery from the embolization and a worse surgical treatment was prevented.

As a result, it is very important that insertion of the central venous catheterization should be performed percutaneously, historically cut-down technique should be abandoned and more importantly government health officials should be educated more for a better care of catheter. The parts of catheter which have remained in the vein system should also be taken out either by surgical or percutaneous attempts.

### **CORRESPONDENCE TO**

Mustafa EDIS, MD Trakya University Medical Faculty,  
Department of Cardio-Vascular Surgery, 22030, Edirne,  
Turkey Tel: +90284 235 0665 Fax: +90284 236 1513 e mail:  
drmedis@trakya.edu.tr

### **References**

1. Mermel LA. Prevention of intravascular catheter-related infections. *Ann Intern Med* 2000;132:391
2. Seldinger SI. Catheter replacement of the needle percutaneous arteriography: A new technique. *Acta Radiol* 1953;39:368
3. Sznajder JJ, Zveibil FR, Bitterman H, et al. Central vein catheterization. Failure and complication rates by three percutaneous approaches. *Arch Intern Med* 1986;146:259
4. Newman BM, Jewett TC Jr, Karp MP, Cooney DR. Percutaneous central venous catheterization in children: first line choice for venous Access. *J Pediatr Surg* 1986;21:685

**Author Information**

**Mustafa Edis**

Department of Cardio-Vascular Surgery, Trakya University Medical Faculty

**Turan Ege**

Department of Cardio-Vascular Surgery, Trakya University Medical Faculty

**Enver Duran**

Department of Cardio-Vascular Surgery, Trakya University Medical Faculty