

# Hereditary Palmoplantar Keratoderma Areata

S Shamsadini, M Vazirian, A Shamsadini

## Citation

S Shamsadini, M Vazirian, A Shamsadini. *Hereditary Palmoplantar Keratoderma Areata*. The Internet Journal of Dermatology. 2005 Volume 3 Number 2.

## Abstract

Hereditary focal palmoplantar keratoderma is characterized by linear bands of hyperkeratosis that follow the midline of one or more digits, often continuing across the palm in a linear fashion, but plantar involvement usually are nummular shape (1). Men against women and blacks against whites are more susceptible in taking this diseases(2). The trait is inherited in an autosomal dominant manner and may not be expressed until late childhood or adulthood when is precipitated by mechanical stress(3). Punctuate keratoses with fine "music box" spines may show the full histopathology of porokeratosis ,cornoid lamella, or may only show a mound of parakeratosis.

## CASE REPORTS

A 23-year-old man reported with severe scaly fissured areas with progressive thickening of the skin of the hands and feet and an inability to flex his hand. It was largely asymptomatic; however, brisk walking caused excessive sweating, pain, and widening of the fissures on the soles of the feet. He was unable to walk barefooted. According to his mother, the first episode presented with blistering at 2moths of age. By the way, the condition has been steadily worsened to acquire the current status. He has three brothers and one sister. Two of his three brothers were affected, his parents and his sister with the fourth brother was non affected. Examination of the palms was marked by multiple focal lesions with severe hyperkeratoses with thickening of the skin resulting palmo plantar masking creases. Both localized keratoderma and thickened lesions were demarcated prominently so that their margins were surrounded by hue red erythema, on waxy yellowish skin color (Fig.1).

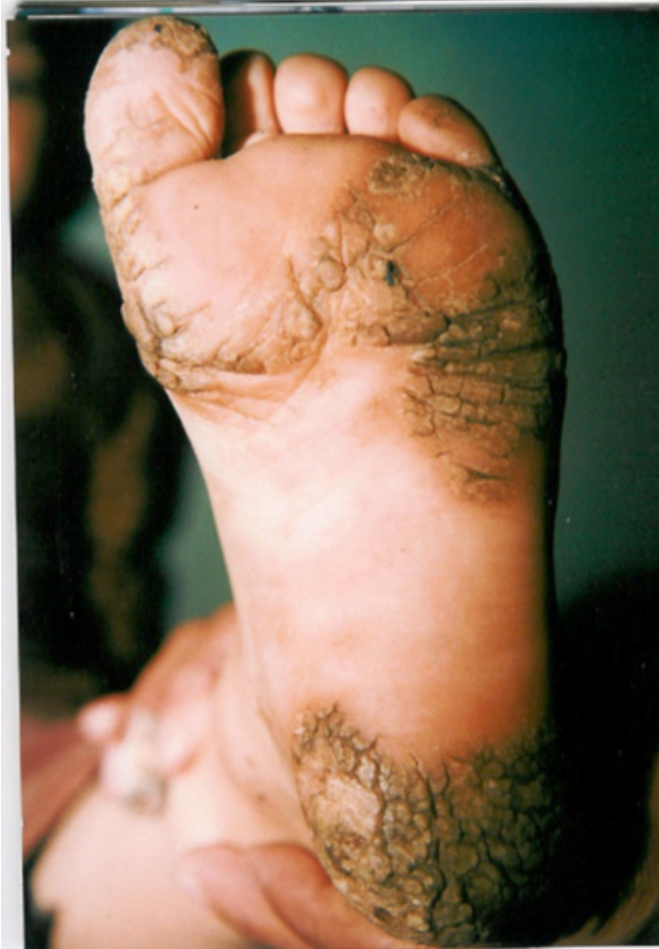Figure 1



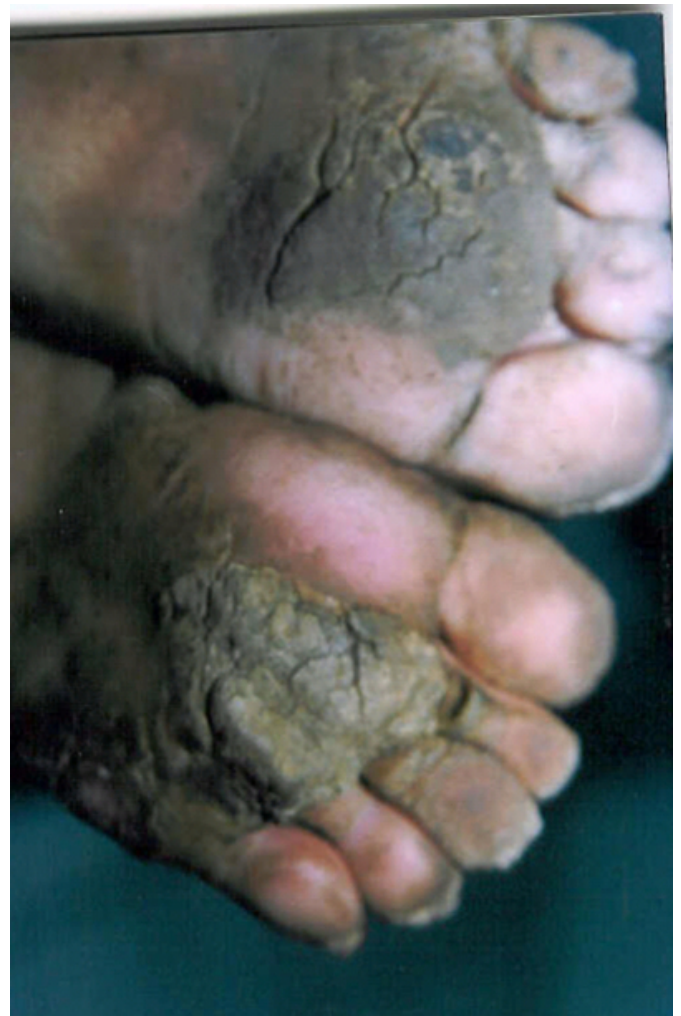All fingers have been contracted nevertheless, and the deformity of the middle and distal interphallangeal joints of the little finger was prominent. The soles of the feet had a similar morphology. In addition, marked fissuring was

obvious (Fig.2).

**Figure 2**



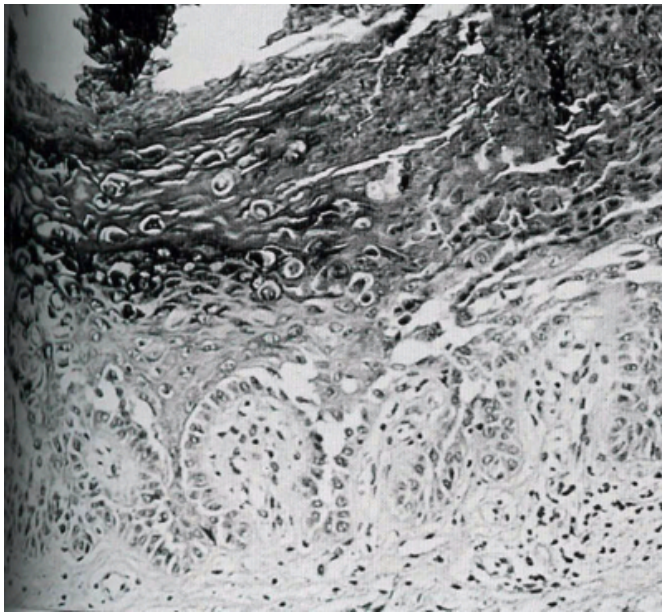
**Figure 3**



Both his brothers had an identical affection of the palms and soles. The texture and morphology of the nails were normal. Light microscopy performed on direct smear scrapings from the fissures, mounted on 10% potassium hydroxide, revealing many spores. Hematoxylin and eosin-stained microsections from the palms lesions showed exquisite changes in the epidermis characterized by considerable uniform orthohyperkeratosis. Hypergranulosis and acanthosis were other associated changes. In addition, perinuclear vacuolization and keratohyalin granules of varying sizes and shapes were located at the periphery of the cells. A sparse mononuclear infiltrate was located at the dermo-epidermal junction. Orally vitamin a acid or Etreinate (Teigason)<sup>®</sup> 25 mg two times daily , was administered with relative resting for 14 days. Supplemented therapy with using an ointment containing 1% Clobetasol<sup>®</sup> cream and 10% salicylic acid for night-time was used. This therapeutic plan was relatively more benefit in him and his brothers.



**Figure 4**



## DISCUSSION

Hereditary palms and plantar keratoderma areata or striate type is a recalcitrant painful disorder with fascinating clinical expression characterized by well-circumscribed extensive hyperkeratosis of both palms and soles. This is invariably accompanied by a yellow waxy appearance surrounded by an erythematous halo which increased in appearance prominently after bathing or washing. The credit for its initial description of diffuse palmoplantar variation “Vorner” type is shared by Thost and Unna in 1880 (<sub>4,5</sub>) and 1883, respectively. Hereditary palmoplantar keratoderma areata may require histopathological differentiation from that of the Vorner type (<sub>6,7</sub>) Cowden syndrome, and Darier's disease. Both ortho and hyperkeratoses were the main histology finding in the former one, while cornoid lamella and dyskeratosis are characteristic of the latter diseases (<sub>8,9</sub>). The current case exhibited features of the Hereditary palmoplantar keratoderma areata a variant of palmoplantar keratoderma. It is often complicated by fungal infection as our case (<sub>10,11</sub>).

Interestingly, of the 3 cases in a family 3 brothers were affected and disorder in him was more severe than the other two brothers. His parent was family with others and was not affected for hereditary palmoplantar keratoderma striate type. Fourth brother and the only their sister were not

affected also. This observation clearly indicates this think so the pattern of inheritance of this disease in this family is more compatible with autosomal recessive with variable penetrations that has not mentioned because of hereditary palmoplantar keratoderma is inherited usually as an autosomal dominant manner (<sub>9,10,11</sub>). The condition may be associated with an increased incidence of smoking as well as with bladder and lung cancer (<sub>12</sub>). An association between punctuate palmoplantar keratoderma focal form and gastrointestinal malignancies has been reported.

## CORRESPONDENCE TO

Shamsadini Sadollah MD Associate professor of dermatology. Kerman P.O.Box 76195 -1431 Iran. Tel (0341) 57272 & 58287 E-mail: shamsadini@yahoo.com

## References

1. Ortega M Quintana J Camacho F Keratosis palmoplantar striata (brunauer fuhs type). *Acta Derm Venereol* 1982;63:273-275.
2. Rustad OJ, Vanc JC Punctate keratoses of the palms and soles and keratotic pits of the palmar creases *J Am Acad Dermatol*. 1990;22: 468-476.
3. Baden HP, Bronstein BR, Rand RE. Hereditary callosities with blisters. *J Am Acad Dermatol* 1984;11:409-415..
4. Thost A. *Über das palmaris et plantaris*. *Corner Med Diss Heibelberg* 1880.
5. Hamm H, Happle R, Butterfass T, et al Epidermolytic palmoplantar Keratoderma of Vorner .Is it the most frequent type of hereditary palmoplantar keratoderma? *Dermatologica* 1988;177:138-145..
6. Unna PG. *Über das keratoma palmare et plantare.. Heredit Dermatolo* 1883;231-270.
7. Kuster W, Becker A. Indication for the identity of palmoplantar keratoderma type Unna-Thost with type Vorner: Thost's family revisited 110 years later. *Acta Derm Venereol* 1992;72:120-122.
8. Hamm H, Happle R, Butterfass T, et al. Epidermolytic palmoplantar keratoderma of Vorner: is it the most frequent type of hereditary palmoplantar keratoderma *Dermatologic* 1998;177:138-145.
9. Margo CM, Badebb LA, Growson AN, et al. A novel nonepidermolytic palmoplantar keratoderma: a clinical histopathologic study of six cases. *J Am Acad Dermatol* 1997;37:27-33.
10. Gamborg Nielsen P, Hofer PA, Lagerholm B. The dominant form of hereditary palmoplantar keratoderma in the northernmost county of Sweden (Norrbotten) *Dermatology* 1994;188-188-193.
11. Nielsen PG. Hereditary palmoplantar keratoderma and dermatophytosis in the northernmost county of Sweden (Norrbotten). *Acta Derm Venereol Suppl* 1994;188:1-60.
12. Maruyama R, Katoh T, Nishioka K. A case of Unna-Thost disease accompanied by *Epidermophyton floccosum* infection. *J Dermatology* 199;26:63-56. date 6 2001

**Author Information**

**Sadollah Shamsadini, M.D.**

Professor of dermatology, Kerman University of medical sciences

**Majid Vares Vazirian**

Pediatrician, Kerman University of medical sciences

**Ayeh Shamsadini, M.D.**

General Practitioner, Kerman University of medical sciences