

# Primary Pyogenic Liver Abscess: Current Treatment Options

J Carvajal Balaguera, J Archilla Estevan, J Camuñas Segovia, M Martín García-Almenta, S Martín Alcrudo, C Cerquella Hernández

## Citation

J Carvajal Balaguera, J Archilla Estevan, J Camuñas Segovia, M Martín García-Almenta, S Martín Alcrudo, C Cerquella Hernández. *Primary Pyogenic Liver Abscess: Current Treatment Options*. The Internet Journal of Surgery. 2008 Volume 18 Number 1.

## Abstract

Pyogenic liver abscesses (PLA) remain an important and life-threatening clinical problem. Although their causes and management have changed in the last years, the strategy for effective treatment has still not been established.

We present a case of primary pyogenic liver abscess, in a patient with signs of malnutrition and sepsis, caused by *Staphylococcus epidermidis*, in which it was not possible to identify the origin (the patient did not have diabetes, biliary tract disease, parasites, tumoral disease, history of biliary endoscopic maneuvers or infections at distance). Due to the critical clinical condition of the patient caused by the sepsis and by contained rupture of the abscess we opted for open surgical drainage, with an acceptable postoperative evolution. Clinical manifestations, diagnosis and current treatment options are discussed.

## INTRODUCTION

Liver abscess is an uncommon pathology in the developed world. However, it is an important cause of morbidity and mortality. Diagnosis is difficult, mainly because there is a significant overlap in the clinical and imaging test features of amebic abscess, infected hydatid cyst and pyogenic abscess, especially in tropical countries and endemic regions. Although management has changed in the last years thanks to advances in the imaging tests and in endoscopy and interventional radiology, the strategy for effective treatment has not been established at the present time (1,2).

Until today, treatment options of pyogenic liver abscess (PLA) have been antibiotics alone, needle aspiration, catheter drainage, endoscopic drainage (when the collection communicates with the biliary tree) or open surgical drainage. In this article we discuss aspects related with clinical manifestations, diagnosis, and current treatment options.

## CASE REPORT

A 72-year-old male presented with fever, inappetence, dyspepsia, loss of weight and constitutional syndrome for 6 months.

**Medical history:** The patient referred tobacco addiction, chronic hepatopathy due to hepatitis-B virus, and chronic anemia from iron deficiency.

**Surgical history:** The patient referred to have been treated surgically for a hydatid cyst in the right lung 20 years before.

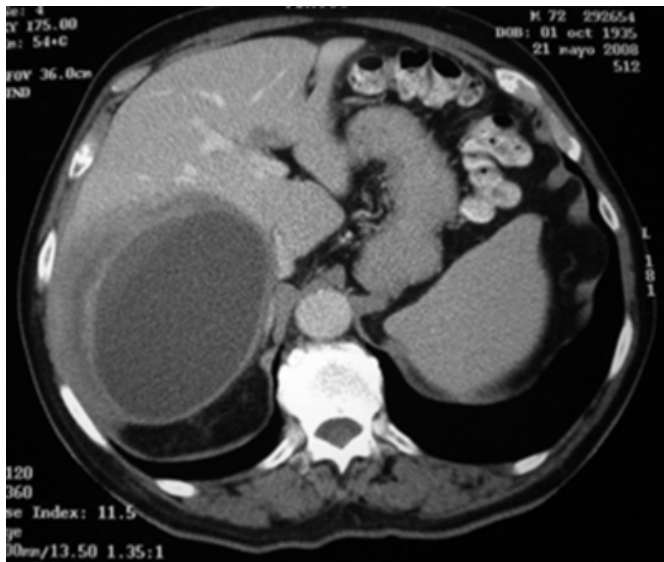
**Physical exploration:** The patient presented deterioration of her general state with signs of malnutrition, skin and mucous paleness, tooth decay, tachycardia, tendency to hypotension, hypoventilation in the base of the right lung, hepatomegaly to 10cm of the edge of the last right rib, left inguinal hernia and soft edema of the lower extremities.

**Laboratory analysis:** Total leukocyte count  $23 \times 10^3 / \mu\text{L}$  (marked shift to the left), erythrocytes  $3.5 \times 10^6 / \mu\text{L}$ , hemoglobin 9.6g/dL, hematocrit 29%, platelets  $467 \times 10^3$ , sedimentation speed 120mm in 1 hour and 126mm in 2 hours, glucose 102mg/dL, urea 34mg/dL, total protein 5g/dL, serum albumin 3g/dL, sodium 133mEq/L, serum bilirubin 0.65mg/dL, alkaline phosphatase 100 IU/L, aspartate aminotransferase 13 IU/L, alanine aminotransferase 10 IU/L, glutamyltransferase 41 IU/L, amylase 36 IU/L, creatine phosphokinase 12 IU/L, iron 3μg/dL, ferritin 1325ng/mL, prothrombin time 73.9%, cephalin time 26", lactate dehydrogenase 224 IU/L, thyroid

function normal, normal clotting factors except factor VII (24%). Carcino-embryonic antigen, alpha-fetoprotein and prostatic antigen were normal. The serologic study of amoebae, giardia, salmonella, brucella, and echinococcus was negative. Thorax x-ray showed elevation of the right diaphragm. Abdomen ultrasonography (USG) revealed a complex cystic lesion of 13x10cm located in the back segments of the right hepatic lobe. Computerized tomography (CT) of the abdomen showed a cystic lesion located in the right hepatic lobe (Figures 1, 2, 3).

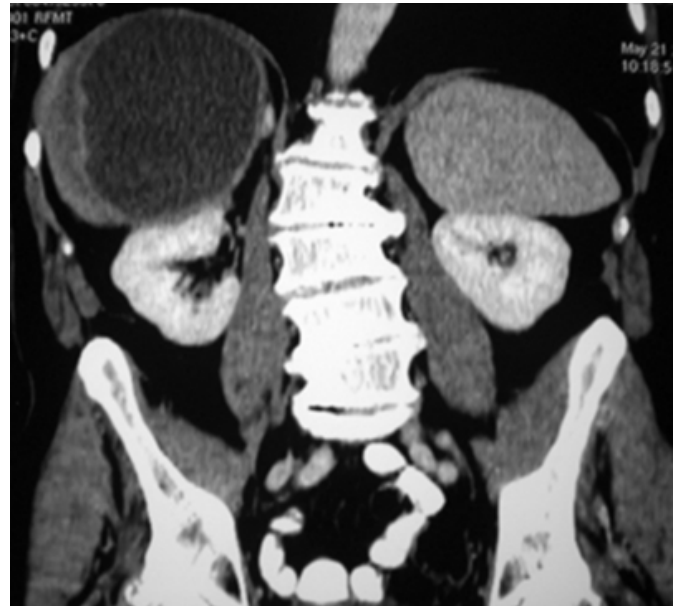**Figure 1**

Figure 1: Computerized tomography (CT) of the abdomen showed a complex cystic lesion of great size and with signs of intrahepatic rupture, located in the segments VI and VII of the liver, secondary to pyogenic abscess, complicated hydatid cyst or amebic abscess.



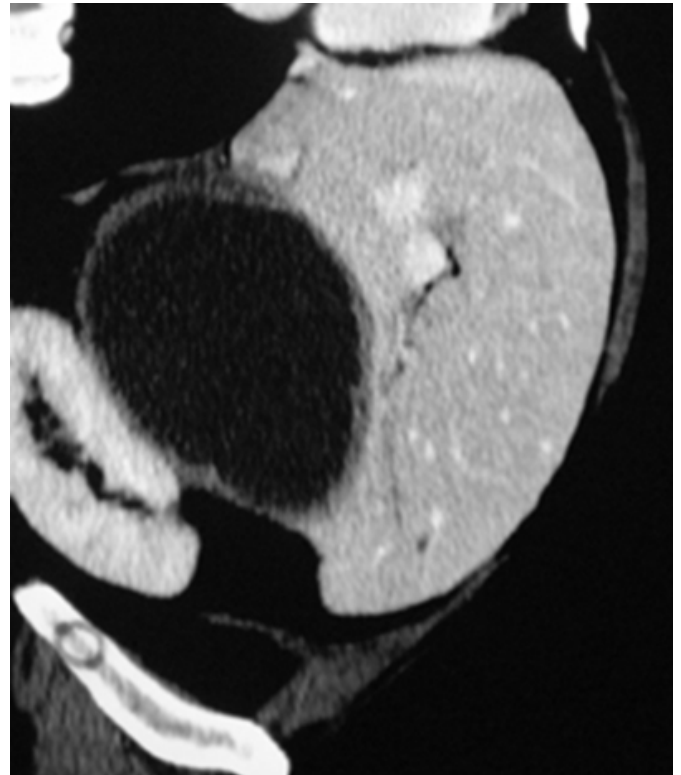**Figure 2**

Figure 2: Three-dimensional reconstruction of a CT scan illustrating the relationship of the hepatic lesion to the right kidney, vena cava and abdominal wall.



**Figure 3**

Figure 3: Abdominal CT (sagittal image) revealing that there is no infiltration to adjacent organs



Due to the septic state of the patient and to contained rupture of the abscess we opted for open surgical drainage. Thirty

minutes before the surgery, activated factor VII (Novoseven®) (30 µg/kg) was administered. Laparotomy revealed great hepatomegaly and a liver abscess of 20cm diameter in the right lobe with signs of contained rupture. After open surgical drainage, aspiration of pus, taking of samples for cultivation and cleaning of the cavity, wall biopsies were taken, and peritoneal toilet was done. An abdominal tube drain was placed in the abscess cavity. The patient was transferred to the intensive care unit (ICU) for postoperative control and remained there for one week.

After the hospital admission and due to the sepsis, the patient was started on empiric broad-spectrum antibiotics (Piperacillin/Tazobactam, 4g IV, four times daily). This was modified according to the bacterial culture report which was positive for *Staphylococcus epidermidis*, sensitive to linezolid. This antibiotic was given intravenously for 14 days (600mg IV, two times daily) and orally for 20 days. Blood cultures were negative.

Among the postoperative complications, the patient presented pseudo-membranous colitis secondary to *Clostridium difficile* that improved after treatment with Metronidazole (500mg IV, three times daily), acute anemia that needed three units of blood and erythropoietin, and diffuse bleeding through the surgical drainage which improved after administration of factor VII and vitamin K.

The catheter was removed when the patient showed relief of symptoms, normalization of the elevated leukocyte counts and catheter output was <10ml/day for at least 2 days. The patient was dismissed to her home 23 days later. After six months of follow-up the patient is asymptomatic and ultrasonography revealed a residual cavity of less than 3cm.

## DISCUSSION

There are three groups of liver abscesses based on serological and culture reports: amebic (sero-positive), pyogenic (culture positive, sero-negative) and indeterminate (serology and cultures negative). The majority of liver abscesses (51.2%) are amoebic, mainly in the tropical or subtropical countries, because of poor sanitation; 23.2% are pyogenic and 25.6% have unknown causes (1).

The mean age at presentation in all three groups is comparable (39, 41 and 45 years, respectively). There is a male preponderance in all three groups. This sex difference may be the result of differences in iron availability and storage. High levels of free iron in gut cause mucosal breakdown with increased risk of portal pyemia. Women

tend to be iron depleted because of the stress of menstruation and pregnancy. Also, chronic alcohol intake leads to increased injury to gut mucosa (1,3). Nevertheless, our patient had an anemia with very low iron and very high ferritin and he did not have a history of alcoholism.

Of the liver abscesses, 75.6% are solitary, with 62.2% confined to the right lobe (1). Diagnosis should be established based on the epidemic study, clinical manifestations, serological tests, sample culture and imaging tests. Occasionally, differentiation of amebic from pyogenic abscess or infected hydatid cyst is very difficult, especially in areas endemic for amoebiasis and hydatidosis (4).

Symptoms tended to be acute and localized to the right upper quadrant in amebic infection. In pyogenic disease, symptoms are nonspecific and chronic in nature, as in our patient. Fever is seen in almost all patients, irrespective of the type of the abscess. Usually, the patient with amebic abscess has a history of diarrhea (5). Our patient did not have this symptom.

A marked shift to the left of the leukocyte count occurs more frequently in pyogenic abscess and these patients also have abnormal values of hemoglobin, serum alkaline phosphatase, serum albumin, direct bilirubin, lactate dehydrogenase and aspartate aminotransferase. Low albumin could be related to malnutrition (as our case), increased alkaline phosphatase, bilirubin and transaminases to extrinsic compression of the biliary tract due to big abscesses (1,6,7). Deranged coagulation profile is an uncommon finding. Our patient presented altered prothrombin time due to deficiency of clotting factor VII. We think that this deficiency could have been worsened by the septic disease of the patient.

Hepatomegaly is more common in presence of amebic abscess (69%) (1); however, our patient presented great hepatomegaly. The identification and determination of the antibiotic sensitivity of organisms responsible for PLA is a crucial step. A positive culture of pus from the abscess has been achieved in the majority of cases (90%), whereas blood cultures are positive in 50% of cases (3).

Common organisms isolated include enterobacteria (*E. coli*, *Klebsiella*), non-hemolytic streptococcus and mixed infection. The presence of gram-negative bacteria is usually associated with biliary tract disease (6). The organism isolated in the liver abscess of our patient was *Staphylococcus epidermidis*, therefore we discard biliary origin.

Negative culture could be caused by the fact that many of the patients receive empirical antibiotic therapy before diagnosis, rendering the cultures sterile. Possibly, some patients would have yielded positive on repeat study.

Serological tests are the mainstay of diagnosis of liver abscesses. High titres of IgG are indicative of invasive amebiasis, with a sensitivity and specificity approaching 100%. However, a negative serology does not rule out amebic liver abscess and should be repeated after a few days ( <sub>156</sub> ). Our patient had antecedents of lung hydatidosis; nevertheless, he had negative serology.

Biliary pathology (gallstone disease and biliary fistula; 31.6%) and diabetes mellitus (26.3%) are the most common etiological factors associated with PLA, followed by peptic ulcer (5.3%) and pyelonephritis (5.3%); however, in a large number of patients (36.8%), the cause is not identified ( <sub>152,7</sub> ). We think that our case is primary, because it was not possible to find the etiology.

The communication between liver abscess and intrahepatic bile ducts is a common cause of significant bile leak. The presence of a biliary fistula can be suspected by jaundice and/or by the appearance of bile in drainage from a liver abscess. This suspicion should be confirmed by endoscopic retrograde cholangiopancreatography (ERCP) ( <sub>89,9</sub> ).

Hepatic abscess – amebic or pyogenic – can be diagnosed with great accuracy by either USG or CT scanning. USG is the modality of choice and will detect almost 100% of abscesses ( <sub>10</sub> ).

A number of authors have advocated treatment of liver abscess with antibiotics alone. However, medical therapy alone is beneficial in a few cases, above all in the group of patients with smaller initial abscess volume. A diameter above 8cm is associated with failure of medical treatment ( <sub>11</sub> ).

With the advancement of USG and CT imaging techniques, image-guided percutaneous aspiration and drainage have gained wider acceptance because they are less invasive and are associated with low morbidity. The majority of PLA will respond to percutaneous radiological aspiration ( <sub>2,12</sub> ).

USG-guided aspiration has largely replaced surgical drainage as the mainstay of treatment due to low morbidity and because it is less expensive, requires less medical and nursing care as well as shorter duration of hospital stay and shows excellent success rates (90%). Symptomatic

improvement may be faster, with quicker resolution rates, when antibiotics are combined with needle aspiration. Moreover, multiple aspirations can be attempted with little morbidity ( <sub>4,13,14</sub> ). The antibiotics should be administered intravenously during at least two weeks, continued by oral administration during one month ( <sub>10</sub> ). USG-guided percutaneous needle aspiration is safe, rapid and simple and now is the proposed first-line therapy for pyogenic abscesses ( <sub>12,13</sub> ).

Percutaneous placement of an indwelling catheter provides continuous drainage, avoiding the problem of incomplete evacuation and reaccumulation with high success rates. Mohan et al. ( <sub>1</sub> ) showed that patients on catheter drainage had a rapid reduction in initial abscess volume; however, the long-term results were comparable with needle aspiration.

USG-guided catheter drainage has been used with success in cases of imminent or localized rupture, subcutaneous rupture, subphrenic rupture or failure of needle aspiration when the pus is very thick ( <sub>1,12</sub> ). No major complications are attributable to needle aspiration or catheter drainage. Among the minor complications they are hemorrhage into the abscess cavity and pericatheter leak ( <sub>15</sub> ).

Open surgical drainage is now reserved for failure of needle aspiration or catheter drainage, in big abscesses, when there is a rupture risk to the pericardium, when there is contained rupture or when there is peritonitis. However, the surgical treatment has a bigger number of complications (respiratory infection, wound infection, ileus, intra-abdominal collections, wound dehiscence, hemorrhages, biliary fistula and mortality) ( <sub>16</sub> ). We opted for open surgical drainage due to the critical state of the patient and the contained rupture of the liver abscess.

Endoscopic therapy is an effective treatment when there is communication between the liver abscess and bile ducts. After ERCP and sphincterotomy, nasobiliary drainage or a biliary stent should be placed. The nasobiliary drain should be removed when bile leakage has stopped and the stent should be retrieved after an interval of 4-6 weeks. Closure of the fistula should be confirmed by cholangiography ( <sub>9</sub> ).

The study of Sersté et al. ( <sub>8</sub> ) revealed that ERCP can demonstrate communications between biliary tract and liver abscesses, and that an internal drainage of the cavity is feasible and safe. In the opinion of Sugiyama et al. ( <sub>17</sub> ), endoscopic biliary drainage is recommended if percutaneous drainage does not achieve a cure.

Mortality as result of hepatic abscess is around 10% ( 3 ).

In the treatment of an amebic liver abscess, metronidazole is the amebicide of choice. Open drainage is contraindicated.

For cases that fail to respond to therapy with amebicides, closed drainage guided by CT or USG is performed.

Secondary bacterial infection of an amebic liver abscess is an extremely rare event ( 18,19 ).

### CONCLUSION

Diagnosis and treatment of PLA have benefited from advances in imaging techniques and from interventional radiology and endoscopy; in particular, aspiration or drainage can be performed under ultrasonographic guidance in the majority of the cases. Endoscopic drainage is recommended (as complementary therapy), when there is communication between liver abscess and bile ducts. Open surgical drainage is suitable when minimal invasive techniques fail.

### CORRESPONDENCE TO

Josué Carvajal Calle Téllez, 30, Escalera 12, 2ª planta, puerta 3 28007 Madrid Spain Phone: +34915518018 - +34649078173 Hospital Fax: +34915345330 E-mail: Josuecarvajal@yahoo.es

### References

1. Mohan S, Talwar N, Cahdhary A, Andley M, Ravi B, Kumar A. Liver abscess: a clinicopathological analysis. *Int Surg* 2006;91:228-33.
2. Sharara AI, Rockey DC. Pyogenic liver abscess. *Curr Treat Options Gastroenterol* 2002;5:437-442.
3. Barnes PF, De Cock KM, Reynolds TN, Ralls PW. A comparison of amebic and pyogenic abscess of the liver. *Medicine (Baltimore)* 1987;66:472-83.
4. Benazzouz M, Afifi R, Ibrahimi A, Essaid FA, Sebti MF. Liver abscess: diagnosis and treatment of a series of 22 cases. *Ann Gastroenterol Hepatol* 1996;31:333-6.
5. Mohsen AH, Green ST, Read RC, McKendrick MW. Liver abscess in adults: ten years experience in a UK centre. *Q J Med* 2002;95:797-802.
6. Wong WM, Wng BC, Hui CK, Ng M, Lai KC, Tso WK. Pyogenic liver abscess: retrospective analysis of 80 cases over a ten year period. *J Gastroenterol Hepatol* 2002;17:1001-1007.
7. Barakate MS, Stephen MS, Waugh RC, Gallager PJ, Solomon MJ, Storey DW. Pyogenic liver abscess: a review of 10 years experience in management. *Aust N Z J Surg* 1999;69:205-9.
8. Sersté T, Bourgeois N, Vanden Eynden F, Coppens E, Devière J, Le Moine O. Endoscopic drainage of pyogenic liver abscesses with suspected biliary origin. *Am J Gastroenterol* 2007;102:1209-15.
9. Sharma BC, Agarwal N, Garg S, Kumar R, Sarin SK. Endoscopic management of liver abscesses and cysts that communicate with intrahepatic bile ducts. *Endoscopy* 2006;38:249-53.
10. Donovan AJ, Yellin AE, Ralls PW. Hepatic abscess. *World J Surg* 1991;15:162-9.
11. Graillet R, Sanches M, Morán A, Hernández JF, Gordillo A, Tapia H. Análisis de factores asociados al fracaso del tratamiento médico del absceso hepático amibiano. *Cir Esp* 2008;84:83-6.
12. Rajak CL, Gupta S, Jain S, Chawla Y, Gulati M, Suri S. Percutaneous treatment of liver abscesses: needle aspiration versus catheter drainage. *AJR* 1998;170:1035-1039.
13. Yu SC, Ho SS, Lau WY, Yeung DT, Yuen EH, Lee PS. Treatment of pyogenic liver abscess: prospective randomized comparison of catheter drainage and needle aspiration. *Hepatology* 2004;39:932-938.
14. Blessman J, Binh HD, Hung DM, Tannch E, Burchad G. Treatment of amebic liver abscess with metronidazole alone or in combination with ultrasound-guided needle aspiration: a comparative, prospective and randomized study. *Trop Med Int Health* 2003;8:1030-1034.
15. Petri A, Hohn J, Hodi Z, Wolfard A, Balogh A. Pyogenic liver abscess: 20 years of experience: comparison of results of treatment in two periods. *Langenbecks Arch Surg* 2002;387:27-31.
16. Kurland JE, Brann OS. Pyogenic and amebic liver abscesses. *Curr Gastroenterol Rep* 2004;6:273-6.
17. Sugiyama M, Atomi Y. Pyogenic hepatic abscess with biliary communication. *Am J Surg* 2002;183:205-8.
18. Goessling W, Chung RT. Amebic liver abscess. *Curr Treat Options Gastroenterol* 2002;5:443-9.
19. McGarr PL, Madiba TE, Thomson SR, Corr P. Amebic liver abscess. Results of a conservative management policy. *S Afr Med* 2003;93:132-6.

**Author Information**

**J. Carvajal Balaguera**

Surgeon Assistant, Service of General and Digestive Surgery, Hospital Central de la Cruz Roja San José y Santa Adela

**J. Archilla Estevan**

Physician Assistant, Anesthesiology Service, Hospital Central de la Cruz Roja San José y Santa Adela

**J. Camuñas Segovia**

Surgeon Assistant, Service of General and Digestive Surgery, Hospital Central de la Cruz Roja San José y Santa Adela

**M. Martín García-Almenta**

Surgeon Assistant, Service of General and Digestive Surgery, Hospital Central de la Cruz Roja San José y Santa Adela

**S. Martín Alcrudo**

Physician Assistant, Anesthesiology Service, Hospital Central de la Cruz Roja San José y Santa Adela

**C.Ma. Cerquella Hernández**

Chief, Service of General and Digestive Surgery, Hospital Central de la Cruz Roja San José y Santa Adela