

# Dumbbell-shaped mesenteric liposarcoma: A case report with review of the literature

J Burgohain, N Kathiresan, B Satheesan

## Citation

J Burgohain, N Kathiresan, B Satheesan. *Dumbbell-shaped mesenteric liposarcoma: A case report with review of the literature*. The Internet Journal of Surgery. 2007 Volume 15 Number 2.

## Abstract

Primary mesenteric liposarcoma (PML) is a rare entity. Radiological diagnosis is difficult though few features suggest so. Management depends on aggressive surgical resection with adequate margins. In this case report, a dumbbell-shaped PML is presented for its rarity and radiological appearance.

## INTRODUCTION

Although liposarcoma is one of the most common primary retroperitoneal malignancies, intraperitoneal liposarcoma is rare [1]. Primary mesenteric liposarcoma (PML) is a rare malignant tumor of mesenchymal origin. It is a tumor of adults that has characteristic clinicopathological and radiological features. In contradistinction from the retroperitoneal liposarcoma, the PML is eminently resectable, and requires aggressive surgical management [2]. The treatment strategy for mesenteric liposarcoma is, if no distant metastases are detected, surgical resection with a wide surgical margin. The role of adjuvant therapy is not clear due to the rarity of the tumor. We report a case of dumbbell shaped primary mesenteric liposarcoma.

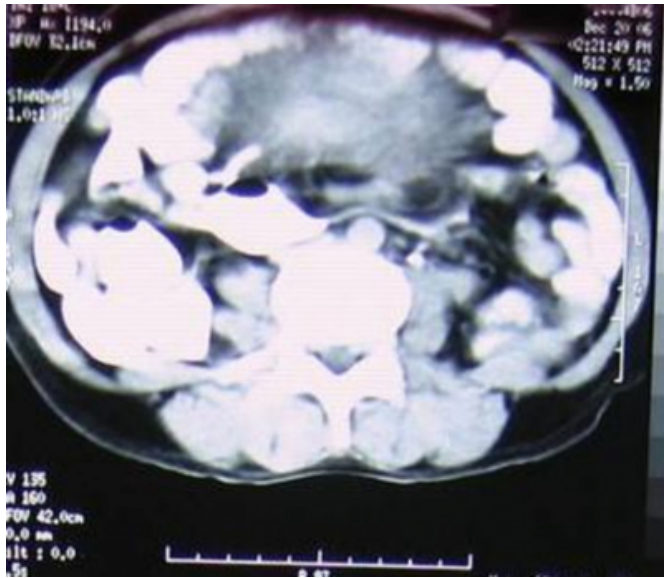
## CASE REPORT

A 32-year-old lady with no concomitant illness or previous surgery, presented with abdominal pain for one-month duration to our center. The non-radiating pain was mainly in the right iliac fossa and it was of mild to moderate intensity and intermittent in nature without any aggravating or relieving factor. There was no history of anorexia or weight loss. She did not have any other symptom. Clinical examination revealed a large intraabdominal mass measuring 18x12cm extending from the right iliac fossa to left iliac fossa. The lower limit could not be reached. The surface appeared smooth with firm consistency. There was side-to-side mobility. On per vaginal examination, the mass was felt through the anterior fornix, pressing the uterine cervix down. Digital rectal examination revealed a mass palpable through the anterior wall of the rectum. Hematological and biochemical evaluation including serum tumor markers were

within normal limits. Ultrasonography (USG) of the abdomen and pelvis revealed a complex mass in the hypogastrium extending to both iliac regions. Computed tomography scan of abdomen and pelvis revealed a large soft tissue mass measuring 17.2x9.1cm arising in the lower abdomen and extending up to the upper pelvis. The mass showed inhomogeneous enhancement and necrotic areas with intravenous contrast study. The bowel loops were distributed across the tumor between the tumor and the anterior abdominal wall (Figure 1) (Straddling sign). This indicated the probable mesenteric location of the tumor. There was a fat plane between the tumor and the great vessels, more than usual for a retroperitoneal tumor. There was no retroperitoneal lymphadenopathy.

**Figure 1**

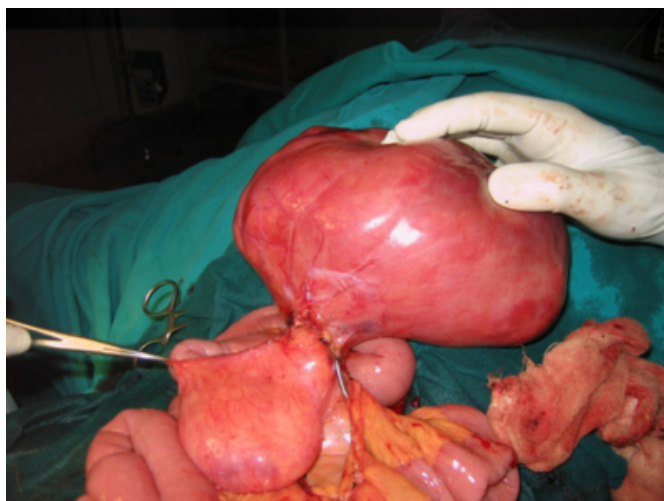Figure 1: CT scan showing a bowel loop straddling over the tumor



Exploratory laparotomy was performed on her. There was a bilobed, dumbbell-shaped, soft to firm tumor straddling across the lower part of the small intestinal mesentery in the mid-ileal region (Figure 2). There were no other swellings or peritoneal nodules or significant intra-abdominal lymphadenopathies. The tumor was resected with part of the mesentery preserving the segment of the ileum. The margins at the level of the mesentery were free on frozen-section study. The abdomen was closed after closing the rent in the mesentery.

**Figure 2**

Figure 2: Dumbbell-shaped tumor

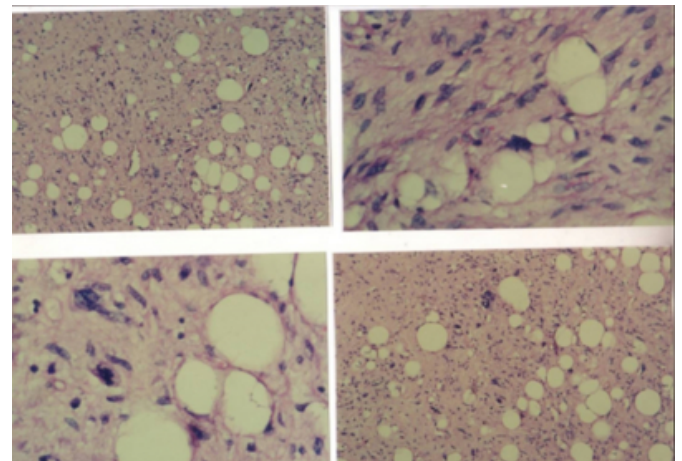


Grossly, the tumor measured 20x18x13cm. The dumbbell actually comprised two tumors of the same histology with

intervening mesentery. Hence the possibility of multicentricity or of a satellite nodule was considered. The histological features were suggestive of a liposarcoma grade II, nuclear grade: intermediate (Figure 3).

**Figure 3**

Figure 3: Histopathological slides of liposarcoma



## DISCUSSION

The lower extremity is the most common location for liposarcoma to occur, accounting for 56% of all liposarcoma [3]. The retroperitoneum is the next most frequent location with 15% to 20% of all liposarcomas. Liposarcoma arising from the mesentery of the bowel is rare [2]. Liposarcomas arising from mesocolon are also described [4]. The most common malignant mesenteric tumor is malignant lymphoma followed by leiomyosarcoma and liposarcoma.

Primary mesenteric liposarcomas typically occur during the fifth to seventh decades of life. The incidence is slightly higher in males than females [2]. Some of the most common presenting symptoms of primary mesenteric liposarcoma include: increasing abdominal girth, weight loss, abdominal pain, abdominal discomfort with meals, and the presence of a freely movable abdominal mass or masses.

Radiological imaging provides a clue regarding the diagnosis. CT scan and MRI may demonstrate the typical liposarcomatous features [5,6]. Mesenteric lipodystrophy is an important differential diagnosis, which is a self-limiting disease with the feature of spontaneous regression. Sometimes, mesenteric liposarcoma may appear as cystic tumor on imaging (7). Rarely, mesenteric liposarcoma produces humoral factors (8). In this case, the possibility of a mesenteric tumor was considered preoperatively because of the radiologic appearance of straddling of bowel loops across the tumor.

The treatment of choice for primary mesenteric liposarcoma is surgical resection with clear margins. Neither radiotherapy nor systemic chemotherapy has been proven to be of benefit in increasing long-term survival. The efficacy of pre-operative chemotherapy is still unclear [9].

Prognosis is based upon the extent of completeness of resection, histological grade and histological variant. The prognostic significance of size and adjuvant therapy is not clear.

## **CORRESPONDENCE TO**

Dr. B. Satheesan MS, DNB, MCh Associate Professor  
Division of Genito-Urinary Oncology Department of  
Surgical Oncology Cancer Institute (W.I.A.) Sardar Patel  
Road, Adyar Chennai 600036 Phone: 044-22350131,  
044-22350241 Cell no: 9840514427 E-mail:  
gabas9@rediffmail.com

## **References**

1. Sato T, Nishimura G, Nonomura A, Miwa K. Intra-abdominal and retroperitoneal liposarcomas. *Int Surg* 1999; 84:163-7.
2. Moyana TN. Primary mesenteric liposarcoma. *Am J Gastroenterol* 1988; 83:89.
3. Takagi H, Kato K, Yamada E, Suchi T. Six recent liposarcomas including the largest to date. *J Surg Oncol* 1984; 26:260-7.
4. Winn B, Gao J, Akbari H, Battacharya B. Dedifferentiated liposarcoma arising from the sigmoid mesocolon. *World J Gastroenterol* 2007; 13:4147-4148.
5. Triller J, Robotti G. Computed tomography in primary mesenteric tumors. *Rofo* 1984; 140:40-45.
6. Hirokoba M, Kume K, Yamasaki M, Kanda K, Yoshikawa I, Otsuki M. Primary mesenteric liposarcoma successfully diagnosed by preoperative imaging studies. *Intern Med* 2007; 46:373-5.
7. Nunez FMJ, Garcia BA, Lopez RA, Garcia GJC, Castro PB et al. Primary mesenteric liposarcoma: presentation like a cystic mass. *Minerva Med* 2005; 96:425-8.
8. Nakamura A, Tanaka S, Takayama H, Sakamoto M, Ishii H et al. A mesenteric liposarcoma with production of granulocyte colony stimulating factor. *Intern Med* 1998; 37:884-90.
9. Ishiguro S, Yamamoto S, Chuman H, Moriya Y. A case of huge ileocolonic mesenteric liposarcoma which responded to pre-operative chemotherapy using doxorubicin, cisplatin and ifosfamide. *Jpn J Clin Oncol* 2006; 36:735-8.

**Author Information**

**Jadunath Burgohain, MS**

Post-Graduate Student, Department of Surgical Oncology, Cancer Institute (W.I.A.)

**N. Kathiresan, MS, DNB, MRCS, MCh**

Associate Professor, Division of Genito-Urinary Oncology, Department of Surgical Oncology, Cancer Institute (W.I.A.)

**B. Satheesan, MS, DNB, MCh**

Associate Professor, Division of Genito-Urinary Oncology, Department of Surgical Oncology, Cancer Institute (W.I.A.)