

Rapidly Progressive Malignant Chylous Ascites Due To Metastatic Adenocarcinoma Managed With Denver Shunt: A Case Report.

S Frcs, O Adeyemi

Citation

S Frcs, O Adeyemi. *Rapidly Progressive Malignant Chylous Ascites Due To Metastatic Adenocarcinoma Managed With Denver Shunt: A Case Report.* The Internet Journal of Gynecology and Obstetrics. 2007 Volume 9 Number 2.

Abstract

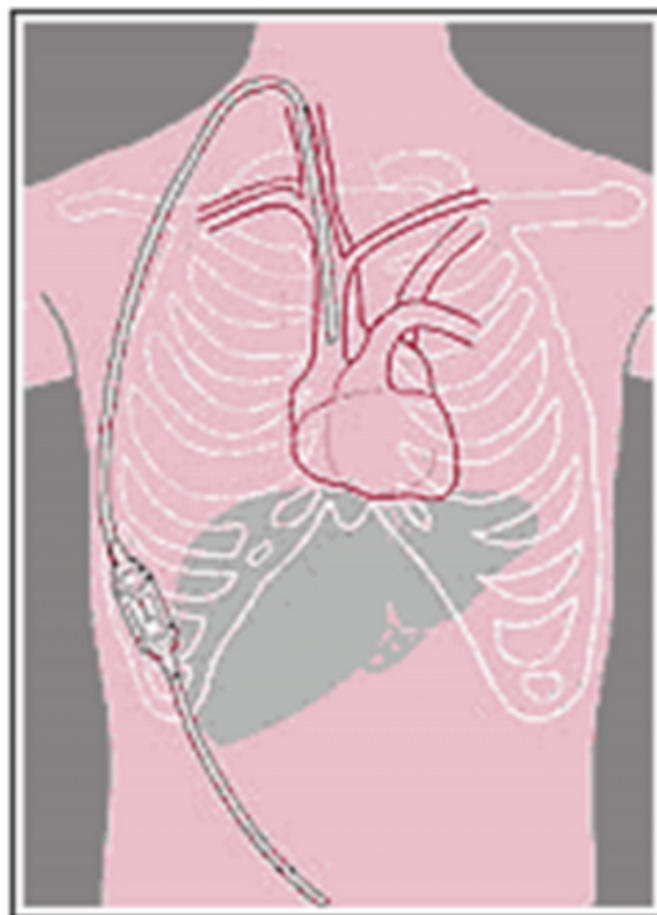
We report a rare case of chylous ascites due to metastatic adenocarcinoma with a pelvic mass, treated with Denver shunt, which achieved symptomatic relief.

INTRODUCTION

Chylous ascites is a rare condition in which there is accumulation of milky fluid inside the peritoneal cavity rich in fat content. It is often associated with malignancy and refractory to medical treatment. Peritoneo-Venous shunting relieves massive, refractory ascites. It promotes several physiologic benefits like an increase in effective blood volume, increase in renal blood flow, retention of nutrients and improving nutritional status, increase in diuresis and improving mobility and respiration. The shunts' pump chambers fit subcutaneously over the ribs, they require only minimal surgical intervention for placement. The Denver Ascites Shunt can be left in place for weeks, months or even years. Pressing down on the pump chamber removes fluid from the abdomen and fills the pump chamber. Continued pumping moves fluid through the chamber into the bloodstream.

Figure 1

Figure: Denver Ascites Shunt.



CASE REPORT

An eighty three year old lady was referred to gynaecological oncology unit with rapidly progressive abdominal swelling for two months and worsening bilateral pedal oedema.

Ascitic fluid tap showed metastatic adenocarcinoma cells probably of primary bowel or ovarian origin. Both CT and MRI of abdomen, pelvis and thorax was done which showed a five centimetre ill defined mass in the pelvis with signs of mesenteric infiltration, gross ascites, bilateral pleural effusion and a two centimetre lytic bony lesion on the right sacro iliac joint. No obvious retroperitoneal lymph nodes were noted.

On examination, she appeared cachectic, anaemic and mildly dyspnoeic. Mobilisation was becoming increasingly difficult. Mammography of the breasts was normal. Her laboratory results revealed elevated serum urea (11.4 mmol/litre) and alkaline phosphatase (126 u/l), hypoalbuminaemia (22g/l) and anaemia (8.3 g/dl). Her serum CEA (108 u/l), CA125 (377u/l) and CA19.9 (48u/l) levels were raised.

Abdominal paracentesis produced a milky fluid confirmed histologically and biochemically as chylous ascites with malignant cells. The cells stained strongly positive for CEA, Ber Ep4, EMA and mucin but were negative for oestrogen receptors and CA125 on laboratory analysis. Diagnosis of a metastatic mucinous adenocarcinoma with a consideration of a primary gastro-intestinal origin was made based on this report. Drainage through paracentesis was about 600 - 900 millilitres daily on average.

A CT guided biopsy was unsuccessful to obtain sample. Palliative care was planned in view of the advanced nature of the disease, her strong refusal for any active treatment but urgent need for symptomatic relief.

Total parental nutrition of low fat intake was initiated to reduce the chylous flow. A Denver shunt was inserted successfully which improved her condition dramatically and relieved her symptoms. She was trained to pump the shunt effectively which keeps the unidirectional flow of the fluid uninterrupted and was discharged home soon thereafter.

DISCUSSION

Chylous ascites occurs as a result of extravasation of milky chyle into the peritoneal cavity. True chylous ascites fluid will have more than 200mg/dl triglyceride in it or ascitic fluid/plasma triglyceride ratio of >2. Incidence in recent years varies from 1 case per 12,000 to 20,000 hospital admissions.

Causes include abdominal surgery, blunt trauma, malignant neoplasm, Spontaneous bacterial peritonitis, cirrhosis, pelvic

irradiation or surgery, constrictive pericarditis, pancreatitis, abdominal tuberculosis (1), Kaposi sarcoma and liver transplant (2). Chylous ascites is a rare complication following abdominal radiation or para aortic lymph node dissection in management of gynaecological malignancies (3). The commonest association in adults is malignancy while that in children is trauma or surgery. Lymphatic channel obstruction or rupture is the ultimate leading cause.

Sepsis is a common complication of this condition. Other complications include bleeding, adult respiratory distress syndrome and disseminated intravascular coagulopathy (4). Sudden death has also been reported. Prognosis depends on primary pathology. Diagnostic tests include CT scan, lymph node biopsy, barium study of gastrointestinal tract, bone marrow examination, Intravenous pyelography and laparotomy.

Treatment should be specified to primary pathology. Supportive management include repeated paracentesis, diuretic therapy, salt and water restriction, elevation of legs and stockings. Low fat diet with medium chain triglyceride supplement and complete bowel rest by total parenteral nutrition (TPN) can reduce the intestinal chylous flow.

Complete resolution occurred in a case of chylous ascites developed as a postoperative complication after retroperitoneal tumour treated with TPN (5). Post operative chylous ascites responds well to supportive treatment while early re-operation is indicated if leaking site is apparent.

Octreotide has been used successfully in both malignant (6) and cirrhotic chylous ascites or effusions (7). In refractory cases, peritoneal venous shunting gives moderate Success (8). This is safe, easy, quick, least invasive and equally effective as other methods (9). In this particular patient it has proved beneficial.

CONCLUSION

Chylous ascites is a rare clinical entity. In elderly patients malignancy should be always suspected. A thorough examination and investigations including CT, MRI and biopsies should be attempted wherever possible. Treatment should be directed to the primary cause particularly for malignant cases. Total parenteral nutrition, repeated paracentesis and octreotide are all recognised treatment for chylous ascites with variable success. Cases where an established cause is unidentifiable or untreatable, Denver shunt is an excellent option for relieving symptoms and

improving quality of life. This paper demonstrate the effectiveness of Denver shunt in improving symptoms related to refractory malignant chylous ascites.

CORRESPONDENCE TO

Dr. S.Sarkar. 9,Lime Lawn Court. Aspenwood, Clonsilla.
Dublin-15. E-mail: gargisarkar@hotmail.com

References

1. Arsurs E L, Ismail Y, Johnson R H et al . Chylous ascites associated with tuberculosis in a patient with AIDS. Clin Infect Dis 1994;19:973-973.
2. Asfar S, Lowndes R, Wall N J. Chylous ascites after liver transplantation. Transplantation 1994;58(3):368-369.
3. Manolotsas T P, Abdessalam S, Fowler J M. Chylous ascites following treatment for gynaecologic malignancies. Gynaecol Oncol.2002 sept;86(3)370-4.
4. Scholz DG, Nagorney DM, Lindor KD. Poor outcome from peritoneovenous shunts for refractory ascites. Am J Gastroenterol 1989; 84: 540-543.
5. Dewdney S , Sokoloff M, Yamada S D et al . Conservative management of chylous ascites after removal of a symptomatic growing retroperitoneal teratoma. Gynaecol oncol. 2005oct 12.
6. Mincher L, Evans J, Jenner M W et al. The successful treatment of chylous effusion in malignant disease with octreotide.Clin Oncol(R Coll Radiol).2005 Apr ; 17(2):118-21.
7. Berziotti A, Magalotti D, Cocci C et al . Octreotide in the outpatient therapy of cirrhotic chylous ascites : A case report. Dig Liver Dis . 2005 Dec 30;(e pub ahead of print).
8. Varos D, Hadziyannis S. Successful management of post operative chylous ascites with a peritoneal jugular shunt . J Hepatol. 1995 Mar;22(3): 380.
9. Clara R, Rishe D, Bartodaini M et al . Role of different techniques for the placement of Denver's peritoneovenous shunt in malignant ascites.Surg Laparoscopic Endosc Percutan Tech. 2004 Aug;14(4):222-5.

Author Information

S. Sarkar Frcs, MRCOG, MRCPI

Specialist Registrar, Obstetrics & Gynecology, Derby City Hospital

O.A. Adeyemi, MRCOG

Consultant, Obstetrics & Gynecology, Pilgrim Hospital