

# Video-assisted Tracheal Intubation Through The Fastrach-Ima Using A Video-optical Intubation Stylet

M Weiss, K Goldmann, U Schwarz

## Citation

M Weiss, K Goldmann, U Schwarz. *Video-assisted Tracheal Intubation Through The Fastrach-Ima Using A Video-optical Intubation Stylet*. The Internet Journal of Anesthesiology. 1998 Volume 3 Number 2.

## Abstract

Blind endotracheal intubation through the Intubating Laryngeal Mask Airway (ILMA) has been reported to be successful up to 99.3 % using several intubation attempts and carries some advantages over conventional laryngoscopy. We report the successful use of video-assisted endotracheal intubation through the ILMA in two children using a video-optical intubation stylet. The video-view from the stylet tip allowed to direct the endotracheal tube through the glottic opening in the first attempt whereas in both cases blind advancing would have been unsuccessful. Visualized tracheal intubation through the ILMA is potentially faster and safer than blind probing for the glottic opening. Using a video-optical intubation stylet, tracheal intubation through the ILMA remains the same technique and can be performed in a simple and comfortable manner.

Video-assisted tracheal intubation may become a valuable method to improve safety and success rate of the intubating laryngeal mask airway for endotracheal intubation.

Please check the Web Site of Video-Assisted Airway Management at <http://www.vaama.net/>

## INTRODUCTION

Blind endotracheal intubation using the Intubating Laryngeal Mask Airway (ILMA) has been reported to be a successful way to intubate the trachea (1). In the first clinical report on the ILMA, Dr. Brain's group reported that tracheal intubation was possible in 93 of 100 patients, 72 were successful at the first attempt (2). Later on the same group has reported that 149 of 150 (99.3 %) patients were intubated successfully, whereas 50 % were intubated in the first attempt (3). A group from Singapore has recently reported successful intubation using the ILMA in 97 of 100 (97%) patients; once again, 50 % were successfully at the first attempt. (4)

Tracheal intubation using the ILMA has shown to be successful and safe and offers some advantages over direct laryngoscopic tracheal intubation, such as no need for distortion of pharyngeal anatomy, no need for head and neck manipulations, possibility for ventilation during tracheal intubation. Because of these features the ILMA may become a valuable tracheal intubation tool.

However, tracheal intubation using the ILMA is still a blind

procedure and has a high degree of unsuccessful intubation at the first attempt. It is not a totally reliable method and therefore the "normal" or "non-enthusiastic" anesthetists are likely to be less successful than the reports from the "LMA/ILMA-specialists" suggest (5).

Video-transmission of the view from the endotracheal tube (ETT) tip onto a bedside monitor screen using an ultralight, malleable video-optical intubation stylet has been reported to be a valuable, simple and safe aid to monitor and to guide the endotracheal tube during conventional laryngoscopy (6,7).

We report the successful use of video-assisted endotracheal intubation through the ILMA using a video-optical intubation stylet.

## CASE REPORTS

### CASE 1

A 9 year old girl (26 kg) was scheduled for skin surgery requiring endotracheal intubation. After inhalational induction of anesthesia with sevoflurane/N2O/O2 and muscle relaxation with mivacurium, an ILMA size 3 was easily inserted and the cuff was inflated with 20 ml air. Ventilation was possible without air leak. An ultrathin flexible video-optical intubation stylet (OD 3.0 mm / Volpi AG Switzerland) was inserted into a conventional endotracheal

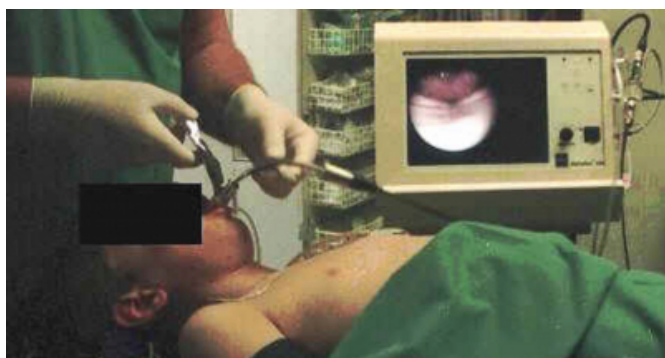tube with Cuff (ID 6.0 mm / Ruesch, Germany ) not protruding the ETT tip. The ETT was lubricated and advanced through the ILMA. First endoscopic view from the ETT tip shown on the monitor was indicating, that the ETT would pass into the upper oesophagus. The ILMA was slightly drawn back and levered anteriorly using the ILMA handle, so that the glottic opening was seen on the monitor. Then, the ETT was advanced through the vocal cords into the trachea without problems and endotracheal tube position was confirmed on the monitor screen. The video-optical stylet was removed from the ETT and the ILMA was slid over the ETT using the stabilising rod.

### CASE 2

A 10 year old boy (38 kg) presented for general anesthesia for ear-surgery. Anesthesia was induced with thiopental and maintained with sevoflurane/N20/O2 and atracurium. An ILMA Size 3 was inserted for endotracheal intubation. A standard endotracheal tube with cuff (ID 6.0 mm / Ruesch, Germany ) was prepared with the video-optical intubation stylet as described above. The ETT was advanced through the ILMA and the endoscopic view early reveals, the ETT tip directing towards the aryepiglottic folds (Fig. 1). Then the ILMA was slightly elevated by manipulating the ILMA handle, so that the whole glottis was seen on the monitor screen (Fig . 2). The ETT was inserted into the trachea under visual guidance (Fig. 3a/b). Final endotracheal tube position was verified on the video monitor and the stylet as well as the ILMA were removed (Fig. 4).

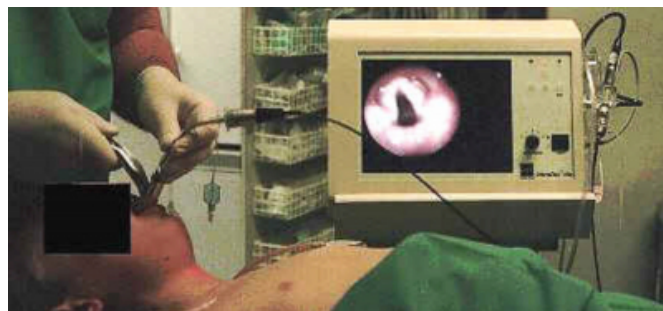
#### Figure 1

Fig. 1: The initial video-view from the stylet tip indicates that the ETT blindly inserted, would advance towards the aryepiglottic folds



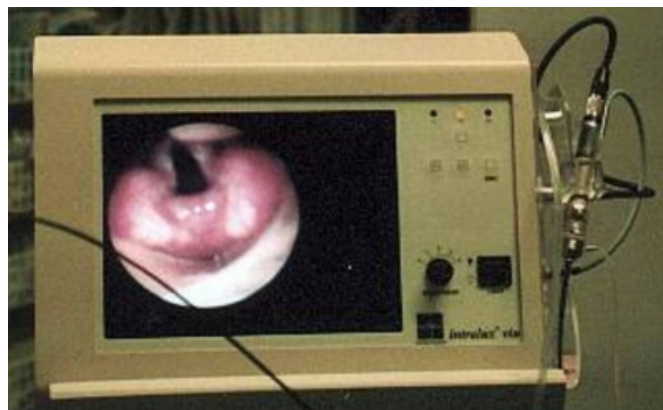
#### Figure 2

Fig. 2: The position of the ILMA is adjusted by manipulating the ILMA handle according the endoscopic findings



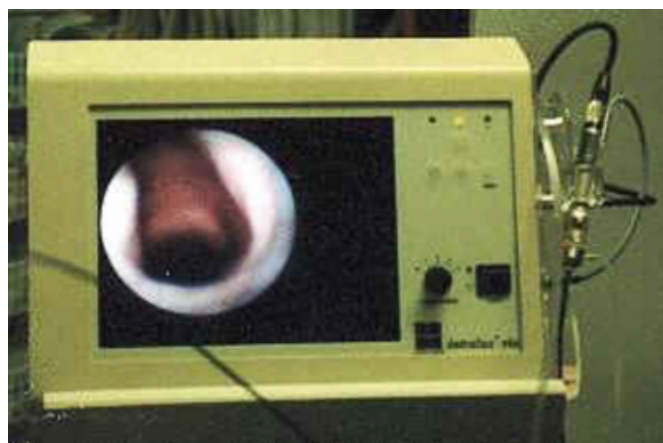
#### Figure 3

Fig. 3a: ETT passage through the cords into the trachea



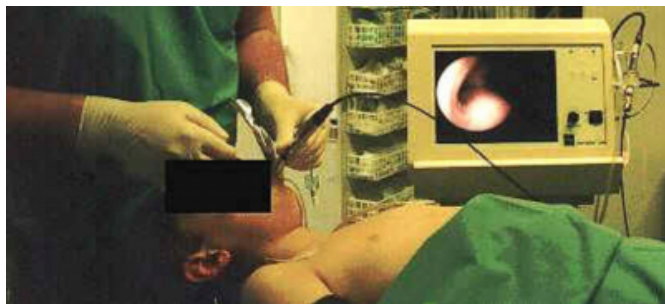#### Figure 4

Fig. 3b: ETT passage through the cords into the trachea



**Figure 5**

Fig. 4: Confirmation of final tracheal tube position



## DISCUSSION

In both patients video-assisted tracheal intubation through the ILMA was successful in the first attempt. The video-view from the ETT tip clearly showed that in both cases blind advancing of the ETT would have been unsuccessful in the first attempt and that more than one would have been required using the blind method.

Using a video-optical intubation stylet to assist endotracheal intubation through the ILMA has the potential advantage over blind insertion, that the ETT is directed into the glottis according the endoscopic findings and not according feelings and estimated distances. Especially for the “non-ILMA specialist”, endoscopic control allows reliable recognition of inadequate vocal cords relaxation, downfolded epiglottis or malpositioned ILMA.

Instead of blind probing for the glottic opening, the ETT is directed through the vocal cords by replacing the ILMA (rough tuning) and/or by manipulating the ILMA-handle (fine tuning) using the video-view from the ETT tip.

Recently, a fatal oesophageal perforation has been reported by Branthwaite as a serious complication of using the ILMA for endotracheal intubation (8). Monitoring the ETT tip helps to avoid such adverse intubation events and makes endotracheal intubation through the ILMA potentially safer, faster and less traumatic which has to be confirmed by further clinical investigations.

In addition, endoscopic intubation control allows detection of laryngeal pathologies, preexisting vocal cords diseases and subglottic pathologies and provides immediate confirmation of final ETT position.

The use of standard curved plastic endotracheal tubes is not recommended for intubation through the ILMA as this may be associated with a higher likelihood of laryngeal trauma (9). Visual control of the ETT tip allows the atraumatic use

of conventional plastic endotracheal tubes with high volume – low pressure cuffs in contrast to the silicone wire-reinforced endotracheal tube with high pressure cuff, which are not suitable for tracheal intubation in the intensive care unit or during surgery of long duration.

Endoscopic assistance using a fiberoptic bronchoscope (FOB) to verify the position of the larynx and the passage of ETT through the glottis during endotracheal intubation through the ILMA is recommended by the ILMA-Manufacturer whenever possible.(9) However, using a FOB interferes with the standard ILMA procedure, requires additional personal assistance, skills and is associated with high costs and extensive preparation work.

Tracheal intubation through the ILMA using a video-optical intubation stylet remains almost the same technique compared to the use of a FOB. The lightweight video-optical intubation stylet has no disadvantages for advancing the ETT through the ILMA and the video-view from the stylet tip is used for monitoring or directing the ETT tip or both. Because the anesthetist does not have to look into an eyepiece, the video monitor, the patient and monitors can be simultaneously observed by the operator in a comfortable and efficient position for intubation. Future developments in video-stylet technology will allow to use video-optical intubation stylets in a cost-effective manner for routine application.

## CONCLUSION

In our experience, video-assisted endotracheal intubation through the ILMA using a video-optical intubation stylet is a simple, reliable and safe technique and may become a standard technique when using the ILMA for endotracheal intubation. In addition, it provides an excellent teaching and supervising tool.

Clinical studies are required to confirm superiority of video-assisted compared to blind endotracheal intubation through the intubating laryngeal mask airway.

## References

1. Brain AIJ, Verghese C, Addy EV, Kapila A.: The intubating laryngeal mask. I. Development of a new device for intubation of the trachea. *British Journal of Anaesthesia* 1997;79:699-703
2. Kapila A, Addey EV, Vergehesse C, Brain AIJ.: The intubating laryngeal mask - An initial assessment of performance. *British Journal of Anaesthesia* 1997;79:710-713
3. Brain AIJ, Verghese C, Addy EV, Kapila A, Brimacombe J.: The intubating laryngeal mask. II. A preliminary clinical report off a new means of intubating the trachea. *British*

Journal of Anaesthesia;1997;79:704-709

4. Chan YW, Kong CF, Kongs CS, Hwang NC, IP-Yam PC.: The intubating laryngeal mask airway (ILMA): Initial experience in Singapore. British Journal of Anaesthesia;1998;81:610-611

5. Baskett PJ.: The intubating laryngeal mask. Result of a multicentre trial with experience of 500 cases. Anaesthesia 1998;53:1174-1179

6. Weiss M.: Video-intuboscopy - A new aid to routine and difficult tracheal intubation. British Journal of Anaesthesia,

1998;80:525-527

7. Weiss M, Schwarz U, Gerber ACh.: Safety and simplicity of intubation management - Comparison of the Bullard laryngoscope with the video-optical intubation stylet. British Journal of Anaesthesia, 1998;80,Suppl I:A77

8. Branthwaite MA.: An unexpected complication of the intubating laryngeal mask. Anaesthesia 1999;54:166-167

9. The Laryngeal Mask Company Limited: LMA Fastrach. Instruction Manual, 1998: p12

**Author Information**

**M. Weiss, M.D.**

Department of Neonatal and Paediatric Intensive Care, University Children's Hospital

**Kai Goldmann, M.D.**

Department of Anaesthesia, Klinikum Kassel

**U. Schwarz**

Department of Anaesthesia, University Children's Hospital