

Foregut duplication cyst of the stomach with pseudostratified columnar ciliated epithelium masquerading as leiomyoma.

K Mardi, S Gupta

Citation

K Mardi, S Gupta. *Foregut duplication cyst of the stomach with pseudostratified columnar ciliated epithelium masquerading as leiomyoma.* The Internet Journal of Gastroenterology. 2008 Volume 8 Number 2.

Abstract

Foregut duplication cyst of the stomach with pseudostratified columnar ciliated epithelium is extremely rare. However the documented cases of foregut duplication cyst are even rarer to find. Because of the highly variable clinical presentation of the foregut duplication cyst, they are usually diagnosed incidentally and intraoperatively in adults. We report a case of foregut duplication cyst of stomach in 42 year old male ,who presented with pain in the left lumbar region. Radiological features were suggestive of leiomyoma. Intraoperatively cyst arising from the lesser curvature of the stomach was identified. Microscopic examination of the cyst wall revealed pseudostratified ciliated columnar epithelial lining and smooth muscle bundles in the wall.

INTRODUCTION

Foregut duplication cysts are rare but well documented. Even more exceptional are those occurring in the stomach¹. These malformations are believed to be congenital and are formed before differentiation of the lining epithelium and, therefore, are named for the organs with which they are associated². They are known to be the cause of a variety of symptoms, some of which may not present until later childhood, or even beyond. As a result their diagnosis in adults is usually delayed because of the non-specific symptoms. Morbidity is associated with complicated and infected foregut duplications and their resection can be a surgical challenge. In majority of the reported cases, the diagnosis is established during surgical exploration³. We herin report a case of foregut duplication cyst arising from te stomach in a 42 year old male which clinically and radiologically mimicked leiomyoma.

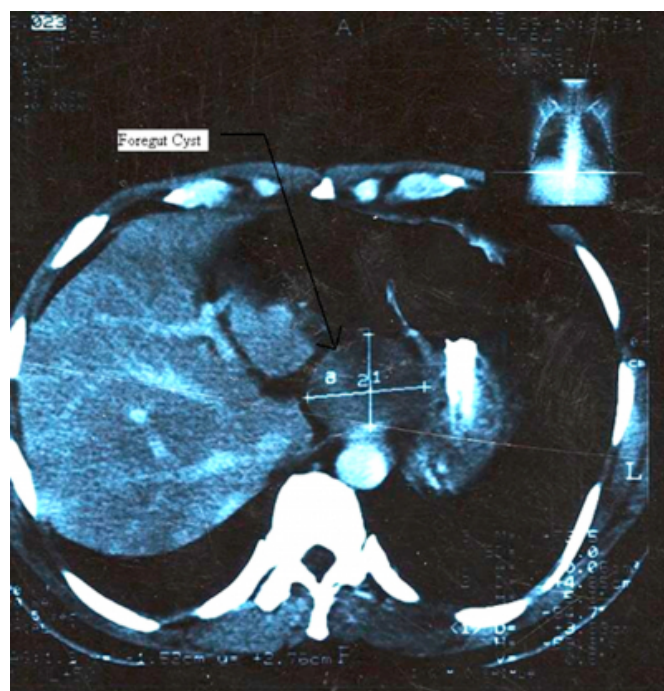
CASE REPORT

A 42 year old male presented to the hospital with pain in the left lumbar region. His past medical history were unremarkable. Abdominal examination and routine laboratory tests were normal. Upper GI Endoscopy revealed an extrinsic compression at lower end of esophagus without any mucosal abnormalities. Abdominal Computed tomography revealed a 4.5 to 5.2cm sized well defined soft tissue density, with mild contrast enhancement, situated

adjacent to anterior aspect of gastrointestinal junction and cardia of the stomach (figure 1.). Radiologically it was diagnosed as gastric leiomyoma .

Figure 1

Figure1: CT Scan showing well defined soft tissue density situated adjacent to anterior aspect of gastrointestinal junction and cardia of the stomach



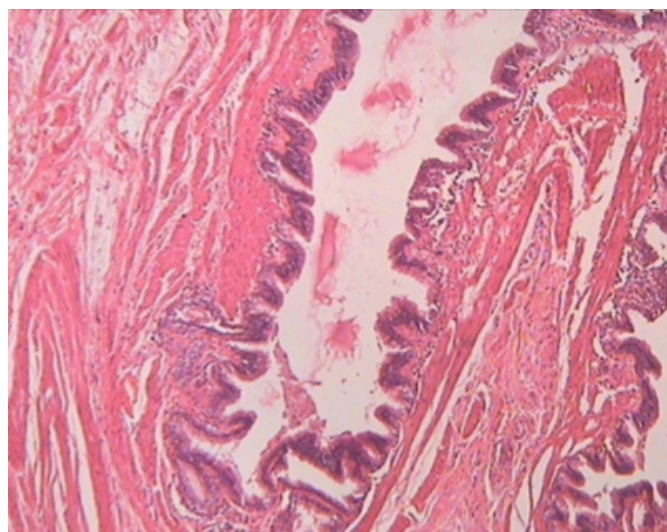
An exploratory laprotomy was performed and complete

excision of the mass lesion was performed. Peroperatively there was a cystic lesion at the lesser curvature of the stomach compressing the gastrointestinal junction. The rest of the stomach was normal. Postoperative course was uneventful and the patient has been asymptomatic since then.

Gross examination of the surgical specimens revealed a unilocular cyst with a grey-white, rubbery wall, measuring 2.5cm in diameter and 0.3 cm thick. The histopathological examination showed a cyst lined by pseudostratified ciliated, columnar epithelium with a complete lining of smooth muscle bundles.(Fig2).

Figure 2

Figure 2:Photomicrograph showing cystwall lined by pseudostratified ciliated, columnar epithelium.(H&E,40x)



DISCUSSION

The term ‘‘gastric duplication’’ implies the presence of gastrointestinal mucosa (usually gastric, but may be small intestinal or colonic), whereas the term ‘‘foregut duplication’’ is preferred when pseudostratified ciliated epithelium predominates. Duplication cyst of the stomach with pseudostratified columnar ciliated epithelium is extremely rare.⁴ Gastric duplications account for between 3% and 20% of gastrointestinal duplications^{1,5,6} and occur twice as frequently in females as in males.

Controversy exists over the embryological origin of these anomalies. These malformations are believed to be formed before differentiation of the lining epithelium and, therefore, are named for the organs with which they are associated. Foregut duplications are considered to be due to abnormal cannulization of the gastrointestinal tract and may be

communicating or non-communicating, cystic or tubular. Duplications of the stomach are typically single, noncommunicating with the gut, less than 12 cm in diameter, and located on the greater curvature or on the anterior or posterior gastric wall². It has been seen that in 80% of the cases, gastric duplication cysts does not communicate with the gastric lumen.¹

However foregut duplication cysts of the stomach are usually diagnosed intraoperatively in adults.¹ The clinical presentation of a foregut duplication cyst of stomach can be highly variable and non specific, ranging from vague abdominal complaints, nausea, vomiting, epigastric fullness, weight loss, anemia, dysphagia, dyspepsia, etc. Therefore a foregut duplication cyst can be easily misdiagnosed. The upper gastrointestinal series in cases of foregut duplication cyst demonstrates external pressure on the stomach and because of that can be mistaken for a soft tissue tumor at the gastroesophageal junction. The preoperative workup mainly includes abdominal ultrasonography and computed tomography scans, as well as endoscopic ultrasonography and magnetic resonance imaging^{8,9}. Due to the risk of malignant transformation and the report of gastric cancer arising in duplications of the stomach¹⁰, surgical excision is considered to be the best treatment. Complete resection of the cyst is the ideal technique achieved with both open and laparoscopic approaches¹¹. Unsuccessful approaches including percutaneous or endoscopic aspiration of cystic fluid have been reported¹², but are associated with complications, such as fistula formation and hemorrhage.

In conclusion foregut duplication cyst of stomach can easily be mistaken for a soft tissue tumor of the gastrointestinal tract and the clinician as well as the radiologist must maintain a high degree of suspicion .Although these lesions are very rare, gastric bronchogenic cyst should be included in the differential diagnosis of gastric wall mass.

References

1. Theodosopoulos T, Marinis A, Karapanos K et al. Foregut duplication cysts of the stomach with respiratory epithelium. *World J Gastroenterol* 2007; 13: 1279-81.
2. Cunningham SC, Hansel DE, Fishman EK, Cameron JL. Foregut duplication cyst of the stomach. *J Gastrointest Surg* 2006; 10: 620-21.
3. Perek A, Perek S, Kapan M, Goksoy E. Gastric duplication cyst. *Dig Surg* 2000; 17: 634-36.
4. Murakami S, Isozaki H, Shou T, Sakai K, Toyota H. Foregut duplication cyst of the stomach with pseudostratified columnar ciliated epithelium. *Pathol Int*. 2008 Mar;58(3):187-90
5. Pruksapong C, Donovan RJ, Pinit A, Heldrich FJ. Gastric duplication. *J Pediatr Surg* 1979; 14: 83-85

6. Chawla A, Gadaleta D, Kenigsberg K, Kahn E, Markowitz J. Erosion through the posterior gastric wall by a pancreatic pseudocyst secondary to gastric duplication. *J Pediatr Gastroenterol Nutr* 1991; 13: 115-118.
7. Laraja RD, Rothenberg R E, Champan J, Imran ul haq, Sabatini MT. Foregut duplication cyst : a report of a case. *The American surgeon* 1995; 61: 840-41 .
8. Tanaka M, Akahoshi K, Chijiwa Y, Sasaki I, Nawata H. Diagnostic value of endoscopic ultrasonography in an unusual case of gastric cyst. *Am J Gastroenterol* 1995; 90: 662-63.
9. Takahara T, Torigoe T, Haga H, Yoshida H, Takeshima S, Sano S, Ishii Y, Furuya T, Nakamura E, Ishikawa M. Gastric duplication cyst: evaluation by endoscopic ultrasonography and magnetic resonance imaging. *J Gastroenterol* 1996; 31: 420-24.
10. Kuraoka K, Nakayama H, Kagawa T, Ichikawa T, Yasui W. Adenocarcinoma arising from a gastric duplication cyst with invasion to the stomach: a case report with literature review. *J Clin Pathol* 2004; 57: 428-31.
11. Machado MA, Santos VR, Martino RB, Makdissi F, Canedo L, Bacchella T, Machado MC. Laparoscopic resection of gastric duplication: successful treatment of a rare entity. *Surg Laparosc Endosc Percutan Tech* 2003; 13: 268-70.
12. Ferrari AP Jr, Van Dam J, Carr-Locke DL. Endoscopic needle aspiration of a gastric duplication cyst. *Endoscopy* 1995; 27: 270-72 .

Author Information

Kavita Mardi, MD, DNB

Associate Professor, Deptt of Pathology Indira Gandhi Medical College Shimla, Himachal Pradesh.

Saurabh Gupta, MBBS

Junior resident, Deptt of Pathology Indira Gandhi Medical College Shimla, Himachal Pradesh.