

Stunted tail sperm defect: An Ultrastructural Study Of An Atypical Case

E Sánchez, C Mardomingo, J Fernández

Citation

E Sánchez, C Mardomingo, J Fernández. *Stunted tail sperm defect: An Ultrastructural Study Of An Atypical Case*. The Internet Journal of Urology. 2006 Volume 5 Number 1.

Abstract

Objective: Atypical case of infertility associated with severe tail sperm abnormalities.

Methods: Familiar history, physical examination, semen analysis including scanning electron microscopy

Clinical Case: A 29-year-old man with four years of primary infertility. He had no history of significant illness and in his family was no cilia respiratory pathology nor male infertility. Physical examination of the patient showed no pathological findings. The analyses of four semen samples showed: sperm count 67-83 106/ml, and 0% motility. The morphological analysis showed mainly tail disturbances: absence of flagellum: 14-16%; short tail spermatozoa: 45-64%; coiled tails: 12-17%; and an abnormal proportion of spermatids and spermatocytes. Normal spermatozoa were found in a 11-16%. Endocrine profile was found within the normal range. Testicular biopsy revealed impaired spermatogenesis. Scanning electron microscopy revealed sperm heads with intact nuclei and acrosomal regions. To our surprise, the 12% of the stunted tails evaluated had biflagellate arrangement while the other ones had uniflagellate tail.

Conclusion: To our knowledge, this is the first human sperm with coexisting uniflagellate and biflagellate stunted tails.

INTRODUCTION

Many cases of male infertility are associated with severe tail sperm abnormalities. The first reports of a syndrome characterized by stunted tails and sperm immobility was reported in rabbits₁, and in bulls₂. Electron microscopy demonstrated that the tail defect results in a blocked formation of the flagellum generating the absence of axonema and accessory fibres₃. This syndrome was known like 'stump defect'. Baccetti et al. described a tail defect in humans₄, in which sperm immobility was also due to stunted tails, but this case was mainly characterized by the presence of biflagellate stunted tails. This abnormality was then called 'short tail' defect. Subsequently, Baccetti et al₅, reported eight human sperm cases of stunted tails, in which half of them were classified as stump defect and the other half as short tail defect. This classification was fundamentally based on two characteristics: the presence of an extremely low sperm number ($11 - 19 \times 10^6 \text{ ml}^{-1}$) and biflagellate tails in 'short tail defect'; and on the other hand, low sperm ($4 - 52 \times 10^6 \text{ ml}^{-1}$) and one stunted tail in 'stump tail defect'. To our knowledge, only two another new cases of stunted sperm tails have been further reported_{6,7}. Indeed,

there are not enough cases described in humans that allow classified these syndromes clearly and the origin of these shunted tails remains unknown. We report a new case of this extraordinary unusual defect in human sperm tail, which presents some peculiarities as regard to previous cases. This case will contribute to characterize these syndromes in a better way.

CASE REPORT

A 29-year-old man was presented in our reproduction department in order to be investigated of a four year primary infertility. He had no history of significant illness and neither the patient, nor anyone else in his family, had cilia respiratory diseases. His parents were not consanguineous and he had six brothers and three sisters with children. Physical examination of the patient showed no pathological findings.

SERUM AND SAMPLE ANALYSIS

Two serum samples were analyzed for follicle stimulating hormone (FSH), luteinizing hormone (LH), and testosterone (T) and were assayed by routine radioimmunoassay.

SEMEN ANALYSIS

Four semen samples were collected by masturbation after 3 days of sexual abstinence and were analyzed within 1h of collection. PH, sperm counts, motility, live forms, morphology were appraised with standardized methods (World Health Organization recommended procedure 1999). Sperm morphology was assessed after Papanicolaou staining on 100 spermatozoa according to the classification of World Health Organization.

TESTES ANALYSIS

A biopsy was performed on both testes, and samples were fixed in Bouin's solution, embedded in paraffin, and sections stained with haematoxylin-eosin.

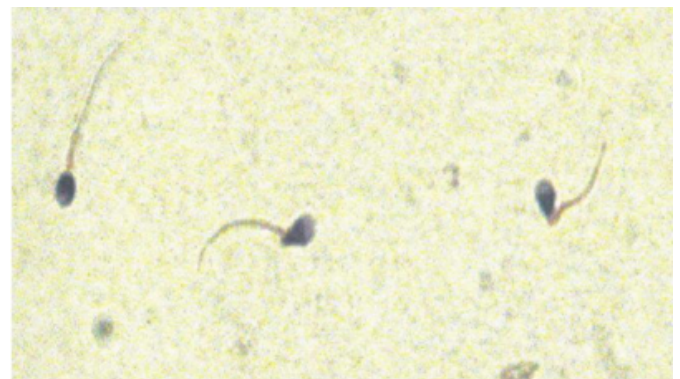ELECTRON MICROSCOPY PROCEDURE

The semen sample was diluted (1:3) with Ham's F10 medium and spermatozoa were separated by centrifugation. The pellets were fixed for 2-4 h with 3% glutaraldehyde and postfixed for 2h in 1,3% osmium tetroxide. The spermatozoa were fixed in suspension with buffer washes between and after fixation steps. Sperm cells were subsequently sedimented on poly-L-lysine coated glass slide fragments and were dehydrated in a graded series of ethanol followed by absolute acetone, dried in Balzers CDP 030 (Balzers Union Ltd, Balzers, Liechtenstein) critical point drying apparatus using CO₂ as transmission fluid, coated with gold-palladium in a Balzers Union CDP 040, and observed in a scanning electron microscope.

RESULTS

The analyses of four semen samples showed the following results: sperm count 278 10⁶/ml (>20x10⁶/ml), 35 % (>50%) alive forms and 0% (>50%) motility. No abnormality was found in biochemical parameters in seminal plasma. The morphological analysis revealed mainly tail disturbances: Absence of flagellum: 14-16%; short tail spermatozoa: 45-64% (Fig 1); coiled tails: 12-17%; and an abnormal proportion of spermatids and spermatocytes. Normal spermatozoa were found in 11-16% (> 30%).

Figure 1



Endocrine profile was found within the normal range FSH: 6.4 (2-8 mUI/ml), LH: 7.2 (2-12 mUI/ml), T: 28 (10-35 nmol/L).

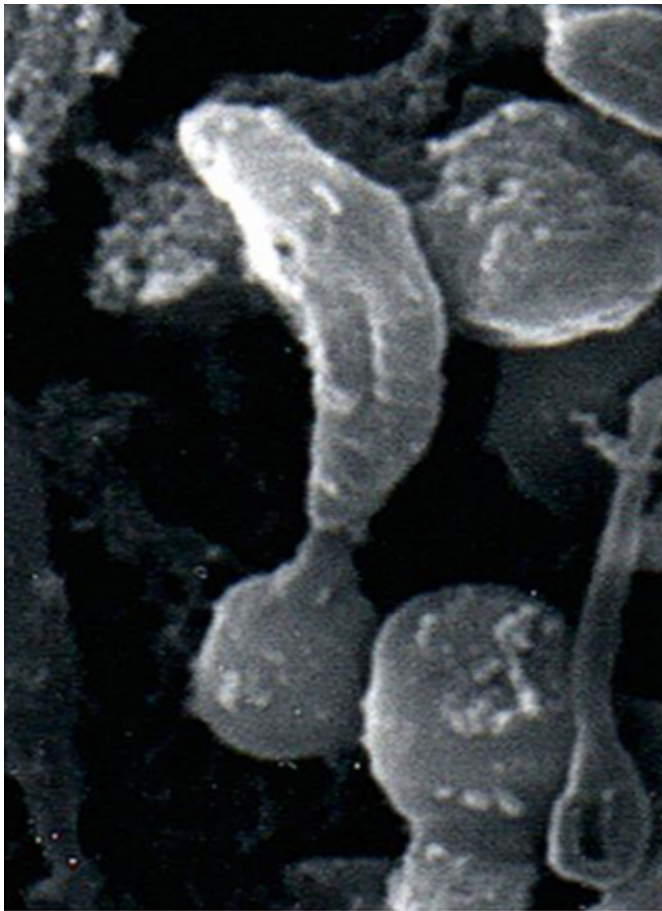
Testicular biopsy revealed impaired spermatogenesis. It was also found reduced length tail spermatozoa in the seminiferous tubules lumen with a high percentage of degenerative spermatocytes and spermatids.

Scanning electron microscopy confirmed the abnormalities observed with optic microscopy (Fig. 2), and revealed sperm heads with intact nuclei and acrosomal regions. Surprisingly, around the 10% of the stunted tails which had been evaluated had biflagellate (Fig. 3) arrangement while the other ones had uniflagellate tail.

Figure 2

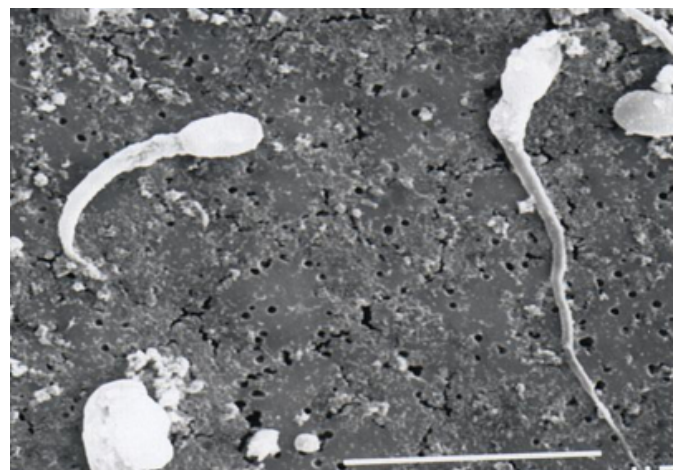

Figure 3



DISCUSSION

The semen analysed showed some, but not all the morphological defects described by Baccetti^{4,5} for the 'stump tail syndrome'. The spermatozoa showed a complete immobility and most of them had a reduced tail. However, it was found that the number of spermatozoa was not reduced and that the total sperm population was not affected by the extremely reduced length of the tails. Besides, in contrast to the 'stump tail syndrome' which is characterised by the presence of only uniflagellate spermatozoa, our sample revealed the coexistence of uniflagellate and biflagellate stunted tails. Due to this observation, the morphological defect observed cannot be exactly classified either as 'tail stump syndrome' or as 'short tail syndrome' according to Baccetti's criteria^{4,5}. To our knowledge, this is the first

human sperm in which uniflagellate and biflagellate stunted tails coexist.

Our case confirms the testicular dysfunction of spermiogenesis as the origin of these kind of tail abnormalities. However the true origin of this defect remains unknown. Sperm and cilia disturbances are often reported to be associated and genetically determined; in fact, familial cases have been described in brothers⁸. Conversely, our patient had no familial history, neither others cilia disturbance, nor male infertility. Therefore, this observation would suggest the possibility of an acquired defect or mosaics of genes that determine ciliary and flagellar axonemes.

This is an atypical case stunted tail sperm which has not been previously described and more cases will be necessary to describe properly these syndromes and to elucidate their origin.

CORRESPONDENCE TO

Ernesto Sánchez Sánchez Avda. Juan de Mata Carriazo 6, 4º
C 41018 Sevilla (Spain) ernesto@pulso.com +34-609566292

References

1. Masquood M. An abnormality of mammalian spermatozoa. *Experientia* 1951; 7:304.
2. Coubrough RI, Barker CAV. Spermatozoa: an unusual middle piece abnormality associated with sterility in bulls. *Proc 5 Int Congr animal Reprod (Trento)* 1964; 5:219-229.
3. Blom E, Birch-Andersen A. Ultrastructure of the tail stump sperm defect in the bull. *Acta Pathol Microbiol Immunol Scand [A]* 1980; 88: 397-405.
4. Baccetti, B, Burrini AG, Pallini V, Rosati F, Menchini-Fabris F: The short-tailed human spermatozoa. Ultrastructural alterations and dynein absence. *J. Submicr. Cytol.*, 1975; 7: 349.
5. Baccetti B., Burrini AG, Capitani, G, Collodell, E, Moretti, E, Piomboni P, Renieri T. *Notulae semiologicae*. 2. The 'short tail' and 'stump' defect in human spermatozoa. *Andrologia*. 1993; 25: 331.
6. Stalf T, Sánchez R, Köhn FM, Schalles U, Kleinstein J, Hinz V, Tielsch J, Khanaga O, Turley H, Gips H, et al. *Hum Reprod* 1995; 10(8): 2112-4.
7. Barthelemy C, Tharanne MJ, Lebos C, Lecomte P and Lansac J. Tail stump spermatozoa: morphogenesis of the defect. An ultrastructural study of sperm and testicular biopsy. *Andrologia* 1990: 417-425.
8. Afzelius, B.A., and Eliasson, R.: Flagellar mutants in man: on the heterogeneity of the immotile cilia syndrome. *J. Ultrastructure. Res.* 1979; 69: 43.

Author Information

Ernesto Sánchez Sánchez, MD, PhD

Urologist, Department of Urology, University Hospital “Virgen Macarena”

Carmen Tejedor Mardomingo, MD, PhD

Biochemistry, Department of Urology, University Hospital “Virgen Macarena”

Jesús Castiñeiras Fernández, MD, PhD

Urologist, Department of Urology, University Hospital “Virgen Macarena”