

# Hypertrophy of ligamentum flavum mimicking lumbar disc herniation.

S Mourgela, A Sakellaropoulos

## Citation

S Mourgela, A Sakellaropoulos. *Hypertrophy of ligamentum flavum mimicking lumbar disc herniation..* The Internet Journal of Neurosurgery. 2008 Volume 6 Number 2.

## Abstract

The most common cause of a spinal root compression is intervertebral disc herniation. Although there are patients with clinical and radiological findings of disc herniation, no disc pathology is found at operation. We present the case of a 38-year old man who was admitted in our clinic because of right fifth lumbar (L5) nerve root compression symptoms. Magnetic resonance imaging (MRI) of the lumbar spine revealed a lumbar disc herniation at the four-fifth intervertebral lumbar level (L4-L5). During operation a fold of the ligamentum flavum was found to compress nerve root, which was excised. After the operation the patient had fully recovered. We describe herein this case in order to denote that an image on MRI studies of disc herniation may represent a fold of ligamentum flavum. Thin slices MRI studies of the affected area may be could scrutinize the imaging misdiagnosis.

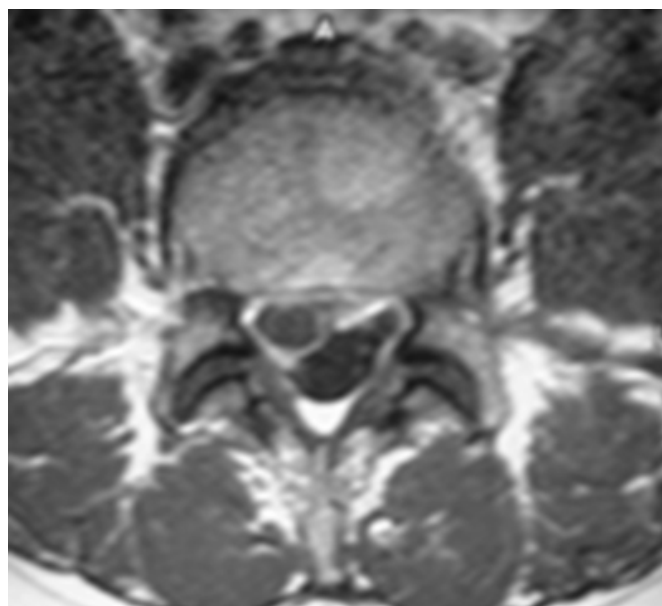
## CASE PRESENTATION

A 38-year-old man, a worker in building companies, was admitted in our clinic because of low back pain with radiation to the right leg, which was lasting for about two months before his admission, followed by leg weakness. The patient in the physical examination showed only limitation of straight leg raising test on the affected side. The symptoms were these of L5 nerve root involvement. The patient related the onset of his symptoms to a specific episode of trauma caused by lifting of a heavy object. The initial symptom was hip pain.

Lumbar MRI revealed L4-L5 intervertebral disc herniation (Figure 1, 2). Plain x-rays and myelography were not performed.

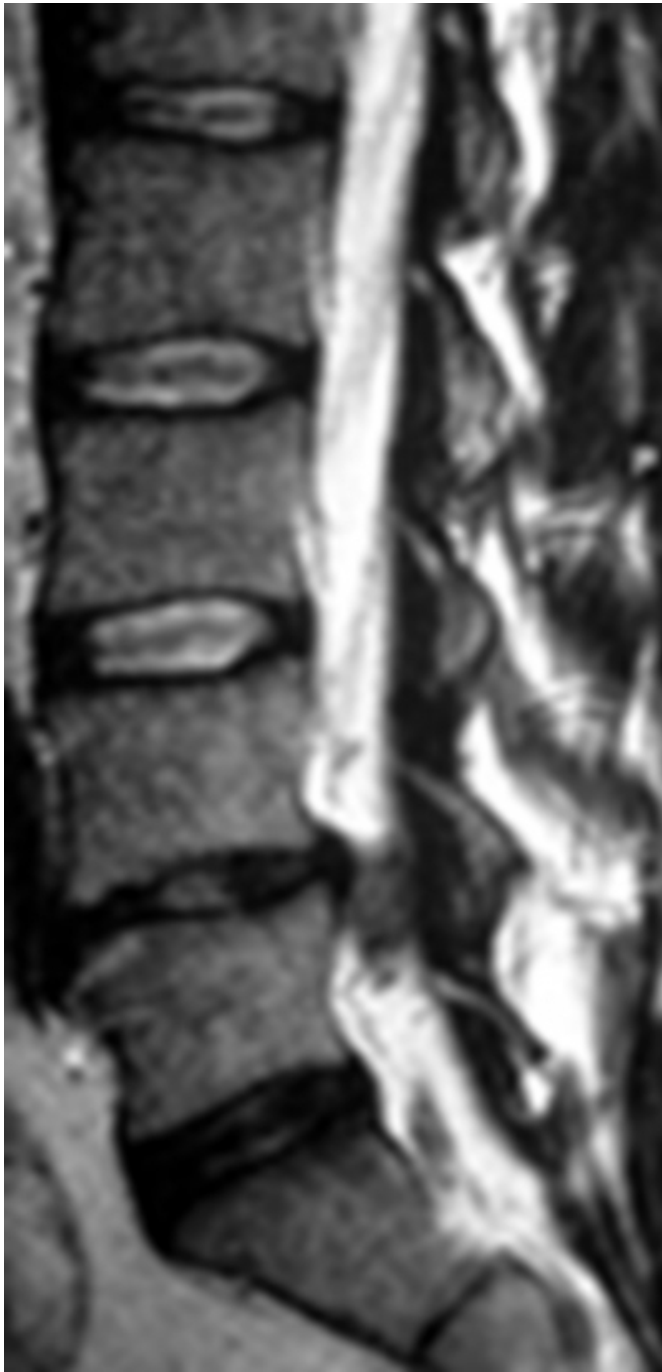
## Figure 1

Fig.1: Axial T2 MRI image showing disc herniation



**Figure 2**

Fig 2: Sagittal T2 MRI image depicting disc herniation. Attention should be paid in the different coloration of disc and lesion



During the operation hypertrophic ligamentum flavum was found and excised. Further exploration of the intervertebral disc space and the neighbouring lumbar spinal canal revealed no disc herniation, fragmentation or sequestration. Postoperatively the patient was markedly improved.

## DISCUSSION

Although intervertebral disc herniation accounts mostly for a

cause of low back pain and sciatica it is nowadays generally accepted that posterior structures play also an important role in this pathology<sup>1</sup>. In cases of posterior spinal elements symptomatology the pain is referred pain originating from the posterior ramos of the spinal nerve.

Various explanations have been proposed to account for radicular symptoms in the absence of a protruded disc. Most explanations have blamed structures which might narrow the nerve root foramen such as thickened ligamentum flavum<sup>2,3</sup>, subluxation of the facet joints<sup>4,5</sup>, retropulsion of one vertebral body on its neighbouring<sup>6</sup>, adhesions between the nerve root and the posterior ligaments<sup>7</sup>, general bulging of the whole edge of the disc<sup>8</sup> and protrusion of the posterior longitudinal ligament<sup>9</sup>.

In the literature there are a few reports concerning ligamentum flavum hypertrophy simulating lumbar disc protrusion<sup>10,11</sup>. It was shown that degeneration of lumbar ligamentum flavum can cause lumbar stenosis and root pain and that resection of it can relieve the symptoms<sup>11</sup>.

Fibrosis is believed to be the main cause of ligamentum flavum hypertrophy, which is caused by the accumulation of mechanical stress, with or without the aging process, especially along the dorsal aspect of the ligamentum flavum<sup>12,13</sup>. Our patient was a worker in house building companies and heavy mechanical stress was an everyday situation for him.

MR images in the sagittal plane are important in demonstrating hypertrophy of the ligamentum flavum and can provide accurate measurements of its thickness<sup>14</sup>. In our case it was not easy to recognise from MR images hypertrophy of the ligamentum flavum. May be acquisition of thin slices MR images of the affected area could pose the diagnosis in such a case.

## References

1. Resnick D. Degenerative disease of the vertebral column. *Radiology* 1985;156(1):3-14
2. Elsberg CA. Observations up on a series of forty-three laminectomies. *Ann Surg.* 1912;55(2):217-26.
3. Young HH, Love JG, Svien HJ, Price RD, Kroll HG. Low back and sciatic pain: long term results after removal of protruded intervertebral disk with or without fusion. *Clin Orthop.* 1955;5:128-37.
4. Hadley LA. Constirction of the intervertebral foramen: a cause of nerve root pressure. *J. Amer. Med. Ass.* 1949;140(5):473-6
5. Hadley LA. Intervertebral foramen studies. Foramen encroachment associated with disc herniation. *J Neurosurg.* 1950;7(4):347-51

6. Friberg S. The lumbar disc degeneration. Bull Schweiz Akad Med Wiss. 1948 Apr;3(4-5):269-79.
7. Dandy WE. Recent advances in the diagnosis and treatment of ruptured intervertebral discs. Ann Surg. 1942 Apr;115(4):514-20
8. Mixter WJ. Rupture of the lumbar intervertebral disk: an etiologic factor for so called 'sciatic' pain. Ann. Surg. 1937;106(4):777-787.
9. Beatty RA, Sugar O, Fox TA. Protrusion of the posterior longitudinal ligament simulating herniated lumbar intervertebral disc. J. Neurol. Neurosurg. Psychiat. 1968;31(1):61-66
10. Pollard WS, Svien HJ. Hypertrophy of the ligamentum flavum simulating the protruded lumbar disc syndrome: report of a case. Proc Staff Meet Mayo Clin. 1956;31(25):654-8
11. Liu LM, Song YM, Gong O. Treatment of lumbar stenosis and root pain resulting from simple hypertrophy of lumbar ligamentum flavum. Zhongguo Xiu Fu Chong Jian Wai Ke Za Zhi 2003;17(1):50-1
12. Sairyo K, Biyani A, Goel V, Leaman D, Booth R Jr, Thomas J, Gehling D, Vishnubholta L, Long R, Ebraheim N. Pathomechanism of ligamentum flavum hypertrophy: a multidisciplinary investigation based on clinical, biochemical, histologic, and biologic assessments. Spine 2005;30(23):2649-56
13. Fukuyama S, Nakamura T, Ikeda T, Takagi K. The effect of mechanical stress on hypertrophy of the lumbar ligamentum flavum. J Spinal Disord 1995;8(2):126-30
14. Grenier N, Kressel HY, Schiebler ML, Grossman RI, Dalinka MK. Normal and degenerative posterior spinal structures:MR imaging. Radiology 1987;165(2):517-25.

**Author Information**

**Sofia Mourgela, M.D.**

Neurosurgical Department, “Agios Savas” Anticancer Institute

**Antonios Sakellarpoulos, M.D.**

Pulmonary and Critical Care Medicine, Division of Endoscopy and Sleep Medicine