

An Electric Cable As A Foreign Body In The Urethra

M Horstmann, M Kuczyk, A Stenzl, K Sievert

Citation

M Horstmann, M Kuczyk, A Stenzl, K Sievert. *An Electric Cable As A Foreign Body In The Urethra*. The Internet Journal of Urology. 2005 Volume 4 Number 1.

Abstract

Foreign bodies are often introduced into the urethra for auto-eroticism. Although most foreign bodies can be removed easily, some cases require endoscopic or open surgical treatment. Primary treatment goal should be extraction of the foreign body using minimally invasive techniques to reduce penile trauma.

In the presented case, the urethral foreign body, an electric cable, could neither be removed via the urethra nor endoscopically, due to a knot in the bladder. At the attempt of removal the knot slipped from the bladder into the bulbar urethra. Finally the cable had to be removed by open surgery (perineal urethrotomia).

Discussion: To avoid damage in the lower urinary tract, the initial attempt should be endoscopic removal of the foreign body. If open surgery becomes necessary sectio alta should be preferred to perineal urethrotomia.

INTRODUCTION

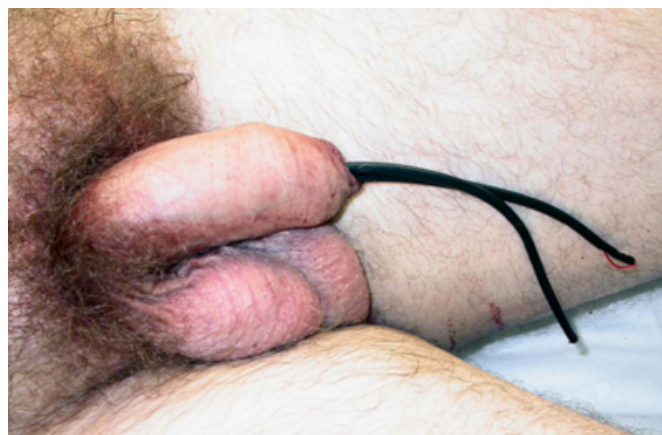
Most self-inflicted foreign bodies of the urethra and bladder can be removed endoscopically^{1,2,3}. The primary goal is extraction of the foreign body and preservation of the urinary tract function: urinary voiding and erectile function using the most minimally invasive techniques. However, in some cases open surgery becomes necessary. We present a rare case where a doubled electric cable loop was inserted into the urethra. Due to a knot in the bladder, extraction via the urethra was impossible. Therefore, the foreign body was removed by open surgery (perineal urethrotomia).

CASE REPORT

A 24-year-old male presented himself at the urology emergency room with a foreign body in the urethra (Figure 1).

Figure 1

Figure 1: A doubled electric cable was inserted in the urethra.



A doubled electric cable was inserted in a loop into the urethra through the isolated end. Both cable ends were still outside the meat of the urethra. The patient was not able to remove the cable because it seemed to be obstructed in the bladder.

The patient's reason for introducing the electrical cable into the urethra was erotic stimulation. At the time of admission to the hospital, the patient was fully oriented, with clear reasoning and thinking. There was no sign of mental or emotional disturbance. Further review of his medical history indicated no psychiatric disorders or other diseases. No

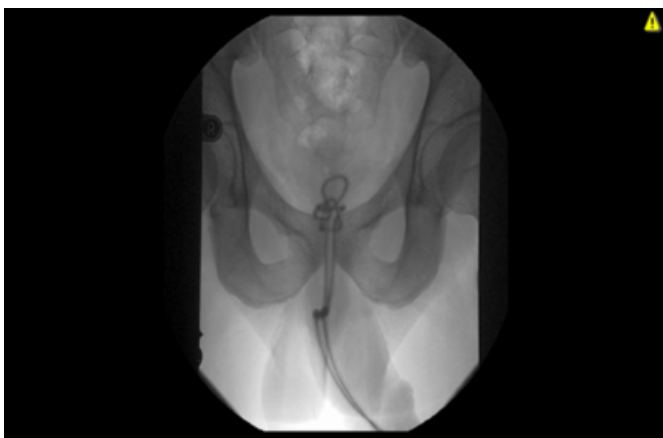
previous surgery of the urinary tract had been performed.

A physical examination revealed a soft belly and no sign of a distended bladder. There was no injury in the anal and scrotal region. The patient had recently tried to remove the cable as there was a small amount of fresh blood visible at the meat of the urethra. During a rectal and perineal region examination, the cable was palpable.

X- rays of the pelvis showed the electric cable in the urethra with a knot in the bladder (Figure 2).

Figure 2

Figure 2: X- rays of the pelvis show the electric cable in the urethra with a knot in the bladder.



In an attempt to remove the cable from the urethra, the cable knot had slipped into the bulbar urethra passing the diaphragma urogenitalis. At this point, no further mobilization could be achieved and the patient was prepared for surgery. After performing a perineal incision, the urethra was liberated and opened. The cable was extracted completely.

After surgery, a suprabubic catheter was put into the bladder for urinary drainage during the healing process.

Postoperatively there were no major problems during the healing process and the patient was discharged with the suprapubic catheter. The patient reported no voiding problems or erectile dysfunction in further follow-up. No urethral stricture was seen by the urethrogram performed in the follow-up.

DISCUSSION

Self-inflicted foreign bodies in the urethra are rare cases of urologic emergency. Most patients are ashamed and do not come to the emergency room until removal is not possible or they experience severe voiding problems⁴. As described in the past literature most foreign bodies are inserted into the

urethra by psychiatric, intoxicated, confused or sexually curious patients. The most common reason still seems to be auto-eroticism^{5,6}. In order to preserve uro-genital function, the removal should be performed endoscopically⁷.

Depending on the size of the objects and the location, this type of removal is possible in most cases¹. Still in some rare cases, open surgery becomes necessary⁸.

In this case the electric cable made a knot in the bladder during the manipulation so that removal by pulling on the distal ends that were depressing into the meat of the urethra was impossible. Due to the fact that the diameter of the electrical cable was 5 mm, introduction of any endoscopical instruments was considered impossible. A removal attempt was made, however, the knot slipped from the bladder over the urogenital diaphragm into the bulbar urethra. At this point, no further mobilisation was possible and the cable had to be removed by open surgery.

The primary goal of the urologic treatment should be removal of the foreign body with as little damage to the urinary tract as possible. In this case, in retrospect, it might have been a better option in order to protect the urethra to take out the cable by section⁹. Nevertheless, after pulling the knot into the urethra there was no other way to remove this foreign body. Fortunately, the patient reported no voiding problems after this operation.

In conclusion, depending upon the location, size and form of the foreign body, the least invasive way to remove the foreign body should be chosen. Although most foreign bodies can be currently removed endoscopically, in some cases open surgery cannot be avoided.

CORRESPONDENCE TO

Dr. med. Marcus Horstmann, MD Hoppe-Seyler-Str. 3 D – 72076 Tuebingen, Germany Tel.: 011 49 7071 29 86565

Fax: 011 49 7071 29 5092 E-mail:

Marcus.Horstmann@med.uni-tuebingen.de

References

1. Aliabadi H, Cass AS, Gleich P, Johnson CF: Self-inflicted foreign bodies involving lower urinary tract and male genitals. *Urology* 1985;26(1):12-6.
2. van Ophoven A, deKernion JB: Clinical management of foreign bodies of the genitourinary tract. *J Urol* 2000;164(2):274-87.
3. Sukkarieh T, Smaldone M, Shah B: Multiple foreign bodies in the anterior and posterior urethra. *Int Braz J Urol* 2004;30(3):219-20.
4. Walsh P, Moustafa M: Retention of urethrovesical foreign bodies: case report and literature review. *J Emerg Med* 2000;19(3):241-3.

5. Kenney RD: Adolescent males who insert genitourinary foreign bodies: is psychiatric referral required? *Urology* 1988;32(2):127-9.
6. Bichler KH, Deppe HU, Mewe F, Schenck K: [Foreign body injuries of urethra and bladder in the young. Their psychosexual background]. *Urol Int* 1971;26(2):161-70.
7. Bulow H: [Juvenile urologic foreign body extraction]. *Fortschr Med* 1980;98(18):687-9.
8. Houlgatte A, Fournier R: [Stones and foreign bodies of the urethra]. *Ann Urol (Paris)* 2004;38(2):45-51.
9. Najafi E, Maynard JF: Foreign body in lower urinary tract. *Urology* 1975;5(1):117-8.

Author Information

Marcus Horstmann

Department of Urology, University of Tuebingen

Markus Kuczyk

Department of Urology, University of Tuebingen

Arnulf Stenzl

Department of Urology, University of Tuebingen

Karl-Dietrich Sievert

Department of Urology, University of Tuebingen