

A Comparison Of The Efficacy Of Enoxaparin With Oral Metronidazole In Idiopathic Lichen Planus

A Mansur, S Yasar

Citation

A Mansur, S Yasar. *A Comparison Of The Efficacy Of Enoxaparin With Oral Metronidazole In Idiopathic Lichen Planus*. The Internet Journal of Dermatology. 2004 Volume 3 Number 1.

Abstract

Background: Enoxaparin and oral metronidazole have been reported to be effective in the treatment of patients with various types of idiopathic lichen planus (LP). However, a comparative trial with these drugs has not been performed before. The aim of this study was to compare the efficacy and safety of these drugs in the treatment of idiopathic LP.

Methods: Two groups of patients were randomly taken into an open, comparative trial. In the first group, 15 patients received 3 mg enoxaparin subcutaneously once weekly, for 10-12 weeks. Included in the second group were 20 patients who received oral metronidazole, 500 mg twice daily, for 10-12 weeks.

All patients were followed up for a period of 12-18 months. Evaluation included clinical grading for pruritus, erythema and induration.

The changes in scores from baseline to the last visits were evaluated statistically.

Results: Fourteen patients (93.3%) improved with enoxaparin treatment. Complete response was observed in 9 patients (60%); whereas 5 patients (33.3%) responded partially. One patient (6.7%) showed no response to therapy. In addition to skin lesions, oral involvement was found in 9 patients and in 4 of them (45%) lesions showed improvement.

Eighteen patients (90%) improved with oral metronidazole treatment. While complete response was observed in 10 patients (50%), 8 patients responded partially (40%). Two patients (10%) were unresponsive to metronidazole. Of the 4 patients with oral involvement, only one (25%) responded to therapy, moderately.

Statistically significant difference was not seen between the two groups in respect to response to therapy at the end of treatment period ($p > 0.05$, $p = 0.830$) and at 52 weeks follow-up period ($p > 0.05$, $p = 0.388$).

Both agents were well tolerated, with no serious adverse events reported.

Conclusions: This comparative study of systemic enoxaparin and metronidazole showed that both drugs were effective and safe in the treatment of cutaneous and oral idiopathic LP. No significant difference was found in the efficacy or in adverse effects between enoxaparin and metronidazole therapies.

INTRODUCTION

Lichen planus is an inflammatory mucocutaneous condition which accounts for 0.1 to 1.2 % of outpatients seen by dermatologists. Although the etiology is still unknown, current concepts of pathogenesis include immunological and genetic factors. Histologically the lesions show a dense, band-like T lymphocytic infiltrate at the dermoepidermal junction. It has been proposed that T cells attach to keratinocytes, which abnormally express HLA-DR and

ICAM-1 antigens on their surfaces.¹

The most prescribed agents for LP include topical and systemic steroids and isotretinoin. In addition to these agents, calcipotriol ointment, antimalarials, dapsone, azathioprine, griseofulvin, IFN- γ , cyclosporine, PUVA and extracorporeal photochemotherapy have been used for LP with variable success rates^{1,2,3}.

Administration of low dose heparin, devoid of anticoagulant

activity, inhibits experimental T lymphocyte-mediated autoimmune disease and allograft rejection in mice.⁴ Furthermore, it has been shown that in humans, a low-molecular-weight heparin (LMWH), in low doses, inhibites the elicitation of allergic contact dermatitis.⁵ Recently, there have been reports about the use of low-dose LMWH in the treatment of LP with favorable results.^{6,7}

In early studies, oral metronidazole was found to be effective in patients with LP who had concomitant intestinal amebiasis or giardiasis.⁸ It was assumed that in these patients the eradication of the infections was responsible for these cures. In a recent report, oral metronidazole was also found to be effective in patients with idiopathic LP who had no associated protozoal infections.⁹

Though the efficacies of both enoxaparin and metronidazole have been reported in open studies, to our knowledge, up to date, there is not a report on the comparison of these agents. In this study we investigated and compared the efficacy and tolerability of metronidazole and enoxaparin in idiopathic LP.

MATERIALS AND METHODS

A comparative, open, prospective study included 35 patients with idiopathic LP. The clinical diagnosis of LP was confirmed histologically in 28 patients. Exclusion criteria for participation were pregnancy, lactation, alcoholism, congenital or acquired hemostatic defect, risk of hemorrhage due to uncontrolled hypertension, severe renal insufficiency, liver disease, active peptic ulcer, history of thrombocytopenia, simultaneous use of nonsteroidal anti-inflammatory drugs and oral anticoagulant drugs. None of the patients were taking any medication known to induce LP-like reactions. The patients stopped any topical or systemic therapy for at least 4 weeks before being enrolled in the study. Informed consent was obtained from all patients.

Patients were randomly selected and allocated to one of the two groups. Enoxaparin group included 15 patients (12 female, 3 male, mean age $35,93 \pm 15,22$). Eleven patients had generalized LP, 2 patients had hypertrophic LP and 2 patients had lichen planus pemphigoides. Nine patients had also oral mucosal LP with bilateral buccal reticular lesions. The duration of disease ranged from one month to 17 years. In all patients, laboratory tests including complete blood cell count, liver, renal, and coagulation function tests were performed before therapy and throughout the study period

once weekly or biweekly.

Enoxaparin was administered at a dose of 3 mg subcutaneously once each week. Patients were examined weekly and clinical status and drug tolerability were assessed.

Demographic data of the patients and clinical findings are summarized in Table 1.

Figure 1

Table 1: Patient characteristics and clinical outcome (enoxaparin group)

PATIENTS	AGE/SEX	SKIN	ORAL	DOSE	DISEASE DURATION	CR	MI	NR	RC	FOLLOW-UP
no	years			week	month					month
1	51/M	GEN	+	12	7	-	+	-	-	12
2	18/F	GEN		12	5	+	-	-	-	16
3	32/F	GLPP	+	10	1	+	-	-	-	18
4	26/F	GEN	+	12	2	+	-	-	-	15
5	30/F	GEN		12	8	+	-	-	-	16
6	50/F	HYP	+	12	7	-	+	-	-	13
7	22/M	GEN	+	12	1	+	-	-	-	12
8	24/F	GEN	+	12	2	+	-	-	-	12
9	48/F	GEN	+	12	10 years	-	+	-	-	12
10	32/M	GEN		12	12	+	-	-	-	15
11	45/F	GEN		11	12	+	-	-	+	18
12	50/F	GEN+HYP		11	17 years	-	+	-	-	15
13	17/F	GEN	+	11	2	-	+	-	-	12
14	69/F	GEN		11	12	-	-	+	+	18
15	25/F	GLPP	+	12	1	+	-	-	-	18

HYP: Hypertrophic, GEN: Generalized, GLPP: Generalized lichen planus pemphigoides, CR: Complete response, MI: Moderate improvement, NR: No response, RC: Recurrence

Second group included 20 patients treated with metronidazole (10 female, 10 male, mean age $41,90 \pm 15,07$). Sixteen patients had generalized, 3 patients had hypertrophic, 1 patient had actinic LP. There were 4 patients who also had oral reticular LP on buccal mucosa and/or tongue. Two patients had lichen planopilaris. The disease duration ranged from 1 to 24 months. Each patient underwent a laboratory investigation including complete blood cell count, routine blood chemistry and urinalysis, before treatment. No patient had gastrointestinal and genitourinary symptoms. All patients received metronidazole 500 mg, twice daily. Patients were examined with 15 days intervals and blood tests were carried out at the same time. At each visit, the clinical appearance of the lesions and subjective complaints of the patients were noted. Demographic and clinical data are summarized in Table 2.

Figure 2

Table 2: Clinical data and treatment results (metronidazole group)

PATIENTS no	AGE/SEX	SKIN	ORAL	DOSE week	DISEASE DURATION month	CR	MI	NR	RC	FOLLOW-UP month
1	40/F	GEN		8	2	+	-	-	-	15
2	48/F	GEN	+	12	6	+	-	-	-	18
3	33/F	GEN		12	3	+	-	-	-	18
4	28/M	GEN		8	3	-	+	-	-	12
5	60/F	GEN		8	5	+	-	-	-	12
6	43/M	GEN		8	2.5	+	-	-	-	14
7	37/F	GEN		3	3	+	-	-	-	12
8	35/M	GEN		8	3	-	+	-	-	15
9	56/M	GEN LPP	+	10	5	+	-	-	-	12
10	25/M	HYP		8	1	-	+	-	-	12
11	60/F	GEN		8	6	-	-	+	-	12
12	35/M	GEN	+	8	1	+	-	-	-	15
13	72/M	HYP		8	3	-	+	-	-	18
14	21/M	GEN		8	2	+	-	-	-	12
15	69/F	GEN LPP	+	10	6	-	+	-	-	12
16	36/F	GEN		8	3	+	-	-	-	15
17	34/F	GEN		10	12	-	+	-	+	12
18	39/F	Actinic		10	24	-	+	-	-	12
19	19/M	HYP		8	12	-	-	+	-	12
20	48/M	GEN		8	3	-	+	-	-	15

HYP: Hypertrophic , GEN: Generalized , GEN - LPP: Generalized lichen planopilaris , CR: Complete response, MI: Moderate improvement, NR: No response, RC: Recurrence

The treatment groups were similar in terms of mean age and gender ($p > 0.05$, $p = 0.257$, $p = 0.281$ respectively) (Table 3).

Figure 3

Table 3: Gender and age of the patients

		Enoxoparin	Metronidazole	p
Age		35,93 ± 15,22	41,90 ± 15,07	0,257
Gender	Male	3 (% 20,0)	8 (% 40,0)	0,281
	Female	12 (% 80,0)	12 (% 60,0)	

The degrees of pruritus, erythema and infiltration were visually assessed according to a four-point scale always by the same physician and were rated on a scale of 0-3 (0= absent, 1= little, 2= moderate, 3= severe).

After the end of the treatment periods, the pre- and post-treatment total scores were evaluated for each drug. The difference between pre- and post-treatment total scores was defined as the "Improvement ratio" (pretreatment total score-posttreatment total score / pretreatment total score X 100 = improvement ratio, %). The treatment was accepted successful, unsuccessful, moderate improvement if the

improvement ratio was 100%, >50, 50-90%, respectively.

Statistical analysis was performed by Student-t test for age-sex distribution, Mann Whitney U test and Wilcoxon for assesment of initial and last scores using SPSS Windows 10.0 programme. Comparing of qualitative data was performed by Chi-Square and Fisher's Exact Chi-Square tests. Differences were considered to be significant when $p < 0.05$, in confidential interval 95%.

RESULTS

As shown in Table I, 15 patients who received enoxaparin were observed for an avarage of 14,6 months (range 12-18 months). Complete response was obtained in 9 patients (60 %) . Moderate improvement was observed in 5 patients (33,3%) . One patient showed no response to enoxaparin therapy (6.7%). Four of the 9 patients with reticular oral LP responded to enoxaparin (45%). The therapeutic benefit in pruritus, erythema and infiltration was obtained after 4 cycles of treatment or even later in some late responders. The differences of pre- and posttreatment total scores were found to be significant by Wilxocon test (6.33 ± 1.11 ; 0.73 ± 1.09 ; $p < 0.05$, $p = 0.001$).

In Table II the demographic data, therapeutic results, follow-up periods and remission rates of metronidazole group are shown. Twenty patients who received metronidazole were observed for a mean of 13,75 months (range, 12-18 months). Ten of 20 patients achieved CR (50 %). Moderate improvement was obtained in 8 patients (40%). Two patients (generalized LP and lichen planopilaris) showed no change (10%). Of the four patients who had reticular oral LP, only 1 of them responded to therapy (25%). The differences of pre- and posttreatment total scores were found to be significant, using Wilxocon test (6.40 ± 1.90 ; 1.45 ± 1.82 ; $p < 0.05$, $p = 0.0001$)

No side effects were reported in either groups.

The overall response rates were not statistically different between the groups at the endpoint of therapy (Table 4). The efficacies of enoxaparin and metronidazole at the end of the treatment are shown in graphics in Figure 1 .

Figure 4

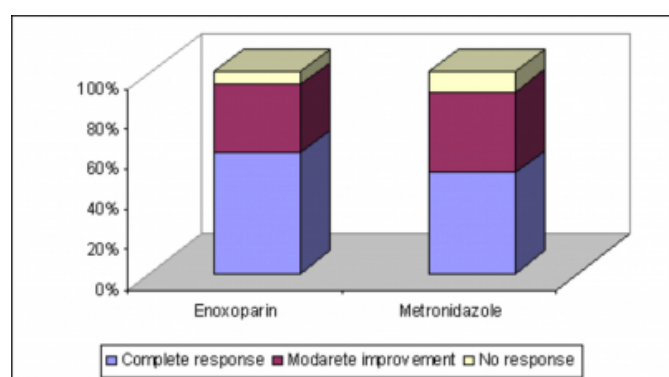
Table 4: Distribution of improvement ratio in enoxaparin and metronidazole groups

	Groups		P =
	Enoxaparin	Metronidazole	
Complete Response	9 (% 60,0)	10 (% 50,0)	0,830
Moderate Improvement	5 (% 33,3)	8 (% 40,0)	
No Response	1 (% 6,7)	2 (% 10,0)	

Statistically significant difference was not seen between the two groups in respect to response to therapy ($p>0.05$, $p=0.830$).

Figure 5

Figure 1: Distribution graphics of improvement ratio (%) in two groups



In enoxaparin group, lesions reappeared in 2 patients at the end of the first year (patient 11 and 14). Twelve patients remained in remission during the follow-up period and the only sequella was hyperpigmentation. In only 1 of the patients treated with metronidazole, new lesions reappeared after 9 months. Nineteen patients remained in remission during the follow-up period. Statistically significant differences were not seen between the two groups in respect to response to therapy ($p>0.05$, $p=0.830$) and at 52 weeks-follow up period ($p>0.05$, $p=0.388$).

No significant difference was found between the two groups, in terms of recurrence rates ($p>0.05$, $p=0.565$).

DISCUSSION

Lichen planus is characterized with violaceous, polygonal, flat-topped papules and plaques that affect the skin, mucous membranes, nail and hair. Many studies have investigated and supported the role of immune system in its pathogenesis. The most striking histological feature of LP is a dense, band-like mononuclear cell infiltrate in the upper dermis which mainly consists of CD4+ lymphocytes.^{1,10} T lymphocytes go through vascular barriers, penetrate the extracellular matrix,

and migrate to target tissues. All these events are thought to be related to their expression of an endoglycosidase, namely heparanase. Activated T lymphocytes produce heparanase, capable of degrading heparan sulfate side chains, which allows the penetration of the lymphocytes into the subendothelial basal lamina. The release of heparanase appears to be an early response of T cells to an antigenic stimulus.¹¹ It has been shown that administration of low doses of heparin into mice and rats inhibits the T lymphocytic heparanase, resulting in the prevention of T cell migration and T cell-mediated immunity in the delayed type hypersensitivity reactions.^{7,12}

Lider et al reported that low dose of heparin both in vitro and in vivo blocked the expression of T lymphocyte heparanase.⁴ On the other hand, it appears that the immunomodulatory effects of heparin might be due to sulfated disaccharides which inhibit the production of tumour necrosis factor- β . Low-molecular-weight heparin preparations are produced by fractionation of standart heparin and are composed of different sulphated sugar molecules. These molecules may rather act as immunomodulatory factors than inhibit blood coagulation.^{6,7} Higher doses of heparin were found to be less effective for LP.⁷ Recently , it was found that a small dose (3 mg subcutaneously) of enoxaparin suppressed the standard patch test reaction in patients with allergic contact dermatitis.⁵

Recent studies indicate the favorable effects of enoxaparin in low doses in the treatment of LP.^{6,7,13} Hodak et al was the first group who reported the efficacy of low dose LMWH in LP. They found that 9 out of 10 patients achieved clinical response.⁷ Stefanidou et al found that enoxaparin was effective in LP with complete response in 61% of their patients, whereas marked improvement was observed in 11%.⁶ Pacheco and Kerdel reported that enoxaparin provided improvement in 5 of 7 patients.¹³ Forsea et al showed that in 63% of cutaneous LP and in 38% of oral LP were treated succesfully with enoxaparin .¹² However there is a recent report which contradicts with these results; Rai et al found that enoxaparin was ineffective in LP.¹⁵ In all reports, LMWH is well tolerated with minimal local side effects.

Cytotoxic T lymphocytes and cytokines may mediate epidermal damage, basal cell liquefaction and T lymphocyte infiltration. T cell activation may be the result of induction of helper T cells by keratinocytes and Langerhans cells, which interact with some types of viral, bacterial, cellular or

pharmacological antigens.^{1,13} According to this hypothesis, the eradication of the source of these antigens may provide a cure: success with penicillin, sulfonamide and griseofulvin have been reported.¹¹ Metronidazole, a nitroimidazole derivative, is a unique antimicrobial agent that is active against both bacterial and parasitic organisms. It has been used for the treatment of *Trichomonas vaginalis*, *Entamoeba histolytica* and *Giardia lamblia* infections.¹⁶

Shelley and Shelley are the first authors who reported of metronidazole as a treatment agent for LP associated with urinary tract infection.⁸ They thought that efficacy of metronidazole for LP was by eradication of focal infection. Thereafter, Wahba-Yahav treated one patient with generalized LP and chronic amebiasis with metronidazole.¹⁷ The same author later published a study indicating that metronidazole treatment was effective for patients with idiopathic LP who did not have concomitant protozoal infections in their intestinal or genital tracts. They suggested that the inhibition of the cell-mediated immunity might be involved additional to anti-bacterial activities.¹⁸ Büyük and Kavala reported that metronidazole was effective in idiopathic cutaneous and oral LP with response rates of 78.9 % and 44% respectively.¹⁹

Oral metronidazole suppresses granuloma formation around the parasitic eggs which suggests that it might have an effect on the cell-mediated immunity.²⁰ The immunological activity of metronidazole has been supported by the findings that it suppresses delayed type of hypersensitivity reactions.²¹ Metronidazole may be an effective therapy for rosacea, acne, rheumatoid diseases and psoriasis by the inhibition of neutrophil-generated inflammatory mediators.^{22,23}

In our study both enoxaparin and metronidazole were highly effective. Not only cutaneous but also oral lesions showed improvement. However, the response rate of therapy in oral lesions were lower than in the cutaneous lesions. This observation is consistent with the reports that oral LP has a higher tendency for chronicity and is more recalcitrant than cutaneous LP. In both drug groups, the highest rate of improvement was seen in cases with generalized cutaneous eruption. The bullous lesions were also quite responsive; 2 cases of GLPP responded very well to enoxaparin. In 2 hypertrophic LP patients who received enoxaparin, only marked improvement was achieved. Similarly, 2 out of 3 cases of hypertrophic LP treated with metronidazole showed marked improvement; the other one was unresponsive. The

lesions of lichen planopilaris were also more recalcitrant than lesions that did not involve follicular unit, showing no response or only partial healing with metronidazole. While chronic lesions (12-17 years of duration) responded partially to enoxaparin, newer lesions responded better. There was no relation between the duration of the lesions and efficacy of metronidazole therapy.

Conventional treatment for CLP is often with topical steroids and if the lesions are extensive, systemic corticosteroids are preferred. Though steroids seem to be a standard therapy in cutaneous lesions of LP, in a review of evidence-based analysis of treatment of LP, surprisingly, there was no convincing evidence of their efficacy in the literature.² We therefore, didn't aim to compare the effectiveness of metronidazole and enoxaparin with topical steroids, and only tried to see the differences, if present, between the efficacy and tolerability of the study drugs. Although there are reports about the efficacy of enoxaparin and metronidazole in LP, a comparative trial with these drugs has not been performed before. The results of such comparative trials are useful for dermatologists in their management of difficult cases, especially if an alternative therapy of CLP should be chosen because of drug resistance or adverse effects. In our study both drugs showed similar efficacy and safety profiles.

Lichen planus is a long-standing inflammatory disorder which proceeds with improvement and relapse periods. In our groups, the disease might have resolved spontaneously, but this seems unlikely, since spontaneous resolution is usually a slow and gradual process and our patients recovered more rapidly than the natural course of the disease.

CONCLUSION

In conclusion, though in a small group, enoxaparin and metronidazole both appears to be effective and safe agents in the treatment of idiopathic LP and there seems to be no difference in success rates and tolerability.

CORRESPONDENCE TO

A.T. Mansur, Selamiçeşme, Güzel sok., No:16/15, 34730, Kadıköy, Istanbul, Turkey. Tel +90 216 3566050 Fax +90 216 4113893 E-mail: tulinmansur@hotmail.com

References

1. Daoud MS, Pittelkow MR. Lichen planus. In Fitzpatrick TB, Eisen AZ, Wolff K, Freedber IM, Austen KF. *Dermatology in General Medicine*. Fifth Edition. New York.

McGraw-Hill Inc., 1999: 561-577.

2. Cribier B, Frances C, Chosidow O. Treatment of lichen planus. An evidence-based medicine analysis of efficacy. *Arch Dermatol* 1998; 134:152-30.
3. Singapore Lichen Planus Study Group. A randomized controlled trial to compare calcipotriol with betamethasone valerate for the treatment of cutaneous lichen planus. *J Dermatol Treat* 2004; 15:141-145.
4. Lider O, Baharav E, Mekori YA, Miller I, Naparstek Y, Vlodavsky I, et al. Suppression of experimental autoimmune diseases and prolongation of allograft survival by treatment of animals with low doses of low molecular weight heparin. *J Clin Invest* 1989; 83:752-6.
5. Ingber A, Trattner A, Cohen IR, Mekori YA. Low doses of low molecular weight heparin in vivo inhibits the elicitation of contact hypersensitivity. *Acta Derm Venereol (Stockh)* 1994; 74:454-6.
6. Stefanidou MP, Ioannidou DJ, Panayiotides JG, Tosca AD. Low-molecular-weight heparin; a novel alternative therapeutic approach for lichen planus. *Br J Dermatol* 1999; 141:1040-1045.
7. Hodak E, Yosipovitch G, David M, Ingber A et al. Low-dose low-molecular-weight heparin (enoxaparin) is beneficial in lichen planus: a preliminary report. *J Am Acad Dermatol* 1998; 38:564-8.
8. Shelley WB, Shelley ED. Urinary tract infection as a cause of lichen planus: metronidazole therapy. *J Am Acad Dermatol* 1984; 10:905-7.
9. Büyük AY, Kavala M. Oral metronidazole treatment of lichen planus. *J Am Acad Dermatol* 2000; 43:260-262.
10. Katta R. Lichen planus. *Am Fam Physician* 2000; 61:3319-24.
11. Boyd AS. New and emerging therapies for lichenoid dermatoses. *Dermatology Clinics* 2000; 18:21-27.
12. Fridman R, Lider O, Naparstek Y, et al. Soluble antigen induces T lymphocytes to secrete an endoglycosidase that degrades the heparin sulfate moiety of subendothelial extracellular matrix. *J Cell Physiol* 1987; 130:85-92.
13. Pacheco H, Kerdel F. Successful treatment of lichen planus with low-molecular-weight heparin: a case series of seven patients. *J Dermatol Treat* 2001; 12:123-126.
14. Forsea DG, Nica M, Jinga O, Motirlachie M, et al. Therapy with enoxaparin in lichen planus. *JEADV* 2001; 15:104-274 (abstr).
15. Rai R, Kaur I, Kumar B. Low-dose low-molecular-weight heparin in lichen planus. *J Am Acad Dermatol* 2002; 46:141-3.
16. Rosenblatt JE, Edson RS. Metronidazole. *Mayo Clin Proc* 1983; 58:154-157.
17. Wahba-Yahav AV. Intestinal amebiasis, lichen planus, and treatment with metronidazole. *J Am Acad Dermatol* 1989; 20:1128-9.
18. Wahba-Yahav AV. Idiopathic lichen planus: treatment with metronidazole. *J Am Acad Dermatol* 1995; 33:301-302.
19. Büyük AY, Kavala M. Oral metronidazole treatment of lichen planus. *J Am Acad Dermatol* 2000; 43:260-262.
20. Grove DJ, Mohmood AAF, Warren KS. Suppression of cell-mediated immunity by metronidazole. *Int Arch Allergy Appl Immunol* 1977; 54:422-7 (abstr).
21. Rockwell S, Irvin CG. Inhibition of delayed hypersensitivity by metronidazole and misonidazole. *Int J Radiat Oncol Biol Phys* 1983; 9:701-6.
22. Ely Ph. Flagyl: beneficial in psoriasis? *Schoch Lett*. 1985; 35:9-13.
23. Akamatsu H, Oguchi M, Nishijima S, Asada Y, et al. The inhibition of free radical generation by human neutrophils through the synergistic effects of metronidazole with palmitoleic acid: a possible mechanism of action of metronidazole in rosacea and acne. *Arch Dermatol Res* 1990; 282:449-454 (abstr).

Author Information

Ayşe Tülin Mansur, M.D.

Department of Dermatology, Haydarpaşa Numune Training and Research Hospital

Sirin Yasar, M.D.

Department of Dermatology, Haydarpaşa Numune Training and Research Hospital