

## A 40 year old woman with nutritional osteomalacia.

S Vakil, K Padha, A Bashir, V Singh, R Singh

### Citation

S Vakil, K Padha, A Bashir, V Singh, R Singh. *A 40 year old woman with nutritional osteomalacia..* The Internet Journal of Nutrition and Wellness. 2009 Volume 9 Number 2.

### Abstract

A 40 year old female presented with pain in hip joints, spine and axilla since 2 years. On thorough examination and investigations we found typical clinical, radiological and lab findings suggestive of primary nutritional deficiency osteomalacia.

### CASE REPORT

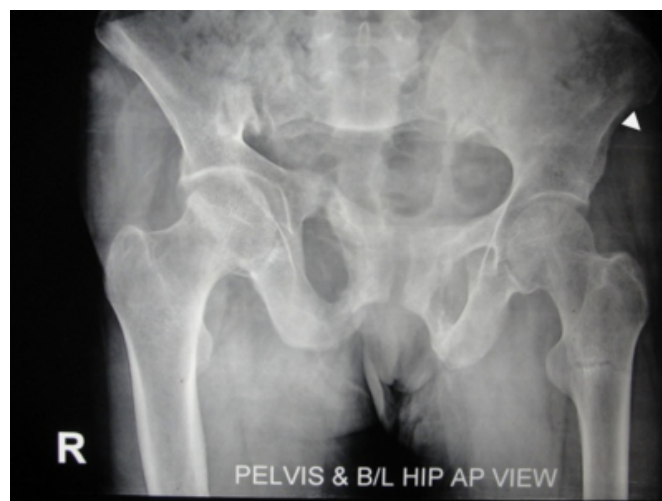A 40 year old female resident of Poonch (a hilly area), not a known case of diabetes mellitus, hypertension or any history of ATT intake presented with diffuse aches and pains in her body for last 2 years. The complaints were persistent, initially mild but increasing in severity with passage of time. The pain was diffuse. Initially it was present in hips then back and knees. At present she had pain in both shoulders also. There was no history of headache, convulsions, cough, chest pain, hemoptysis, flank pain, haematuria, generalized swelling, acute loss of weight and appetite. She had 5 issues 2 abortions and was breast feeding her youngest child. The patient was strict vegetarian and didn't take even milk. She was house wife spent most of the time indoors.

On examination she was pale, gave an anxious look, no lymphadenopathy, all vitals maintained, chest and CVS examination was within normal limits. On local examination her attitude was of flexion at hips and knees. There was tenderness in hips and axilla.

Investigations revealed the following findings; Hemoglobin=8.5%, ESR=60 mmHg, Serum Calcium=7.2mg%, serum Phosphorous=2.6% serum Alkaline Phosphatase=486 Kings-Armstrong units, Serum albumin was 3.8Gm%. Renal functions, liver functions, blood sugar, montoux test were negative. Her x-rays showed typical findings;

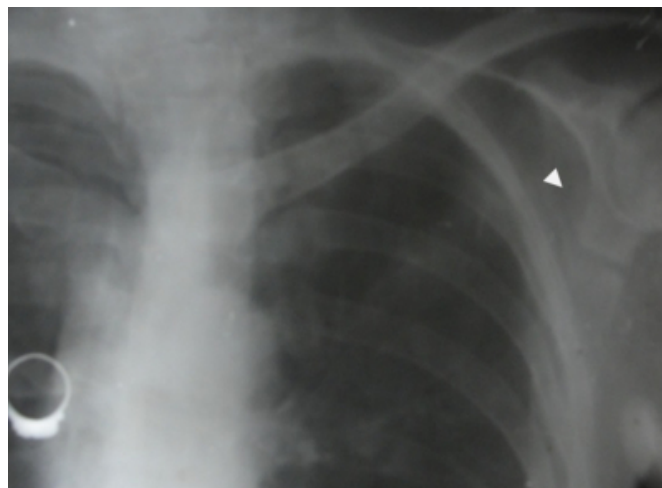
### Figure 1

Figure 1. showing pseudo fractures in both pubic rami [rt.] with loosers zone in the left intertrochantric area.



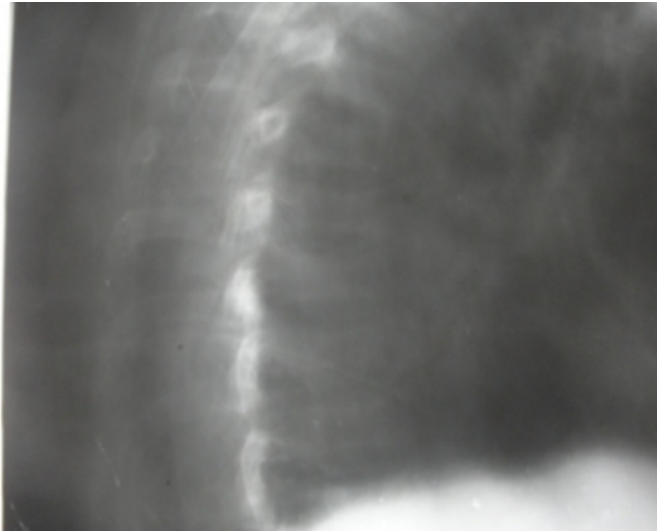
### Figure 2

Figure 2. showing loosers zone in the left axillary edge of scapula.



**Figure 3**

Figure 3. showing typical cord fish spine in thoracic vertebra.



**DISCUSSION**

Osteomalacia is a condition of adults characterized by softening of bones because of accumulation of osteoid matter which is protein matrix mainly collagen which fails to mineralize. The most common cause is vitamin D deficiency. The main biological effect of VIT D3 are promotion of calcium absorption by the gut and mobilization of mineral from the bone. The effects on renal tubules are inhibition of calcium resorption and encouraging phosphate resorption.

The source of dietary Vitamin D is irradiated ergosterol known as calciferol or D2. endogenous Vitamin D3 is formed from 25 hydroxycalciferol by UV light acting on precursor substance in skin. Through a series of conversions Vitamin D3 is formed.

Hypophosphatemia impairs bone formation by interfering with the function of osteoblasts, on the other hand hyperphosphatemia stimulates bone formation.

Pathologically much of the compact bone is transformed into cancellous bone in osteomalacia. Fractures are multiple and heal with abundant callus formation consisting chiefly of osteoid so that union is markedly delayed.

Clinical picture is of patient with generalized body pains with tenderness confined to lower back and extremities. Muscle weakness is typical. Deformities of weight bearing structures is typically present.

Radiographic findings reveal a generalized demineralization with loss of transverse trabeculae and persistent transverse loose zones. The loose zones or pseudofractures typically extend across the bone. These represent incomplete fractures that have healed by callus consisting of osteoid tissue devoid of mineralization. It typically occurs at the neck of femur, rami of ischium, pubis, axillary edge of scapula just below glenoid. In spine the vertebra assumes a typical biconcave configuration leading to Cord Fish Appearance. Laboratory findings are decreased or normal serum Calcium, decreased serum Phosphorus and elevated Serum Alkaline Phosphatase.

**References**

1. Eisman JA: Osteomalacia. *Baillieres Clin Endocrinol Metab* 1988, 2(1):125-55
2. Gonzalez-Compta, M. Mañós-Pujol, M. Foglia-Fernandez. Maxillofacial osteomalacia. *The Journal of Laryngology & Otology* (1998), 112:389-392. Cambridge University Press
3. Harzy T, Benbouazza K, Amine B, Rahmouni R, Hajjaj-Hassouni N: An unusual case of osteomalacia as the presenting feature of coeliac disease. *Rheumatol Int* 2005, 26(1):90-1.
4. Jaworski ZFG : Pathophysiology treatment and diagnosis of osteomalacia. *orthop clin north am* 3:623,1972
5. Kanis JA; Vitamin D metabolism and its clinical implications, *JBJS* 64B:542,1982
6. Mankin HJ: Metabolic bone diseases, *JBJS* 74A:760,1994
7. Mankin HJ: Rickets, Osteomalacia, and renal osteodystrophy: 1 *JBJS* 56A:101,1974
8. Mankin HJ: Rickets osteomalacia and renal osteodystrophy: *JBJS* 56A:352,1974
9. Ray, Debarti, Gowswami et al. predisposition in females to osteomalacia and rickets linked to vit D intake and calcium intake rather than Vit D3 receptor deficiency. *Clinical endocrinol* 2009, sep 01;71(3):334-40.

**Author Information**

**Suhail M. Vakil**

PG student, GMC Jammu

**Kanav Padha**

PG student, GMC Jammu

**Aadil Bashir**

PG student, GMC Jammu

**Vikram Aditya Singh**

**Rajinder Singh**

M.D PGI Chandigarh, Assistant Professor GMC Jammu