

A Huge Bifrontal Meningioma Associated With Intraoperative Massive Bleeding

A Babashahi, A Ghomeishi, L Izadi, M Mashari, I Zaeem, S Fallahpour, H Safari, H Mirzaei

Citation

A Babashahi, A Ghomeishi, L Izadi, M Mashari, I Zaeem, S Fallahpour, H Safari, H Mirzaei. *A Huge Bifrontal Meningioma Associated With Intraoperative Massive Bleeding*. The Internet Journal of Anesthesiology. 2010 Volume 30 Number 1.

Abstract

We report a 25-year-old Iranian female who presented with progressive memory disturbance, headache, and personality change associated with loss of visual acuity since 3 months before admission; bilateral optic atrophy was also noted. Magnetic resonance imaging disclosed a large bifrontal lesion accompanied by prominent edema in both frontal lobes. Cerebral angiography demonstrated a rich-vessel tumor that drained through the diploic vein. A bifrontal craniotomy was performed. We encountered massive bleeding from the diploic vein and dura mater immediately after craniotomy. We were also faced with severe brain swelling at the dural incision. The tumor was solid, highly vascularized, and fairly well demarcated. We performed total removal of the tumor as quickly as possible to reduce intracranial hypertension and avoid impending brain herniation. The patient had an uneventful recovery, and no new neurologic deficits were noted at follow-up.

INTRODUCTION

The 2000 World Health Organization (WHO) classification of tumors of the nervous system lists meningioma. under the heading of “tumours of the meninges”, invasion of the dura and dural sinuses is common, underlying brain without invading it. Even though they are attached to the dura and compress the underlying brain, meningiomas are usually easily separated from the pia mater. The cleavage plane, however, may not encompass the whole surface of the tumor.² meningiomas, the behaviour of such tumours in a given patient depends on many factors: location, size, histology, and cytology. There is little information about hemorrhage associated with meningioma.¹ Factors responsible for hemorrhage within benign intracranial tumours, such as meningiomas, are less obvious.

Angioblastic meningiomas characteristically are composed of abnormal blood vessels,³ and meningiomas of other cell types can contain foci of abnormal vessels; this abnormal vasculature could be related to tumour-associated haemorrhage.⁴ It is possible that blood vessels supplying a meningioma undergo compensatory enlargement with weakening of their wall and create the potential for tumour associated haemorrhage.⁵

CASE REPORT

We report a 25 year old Iranian female who presented with

progressive memory disturbance and personality change associated with loss of visual acuity since 3 months ago. Examination revealed bilateral optic atrophy of the right eye visual acuity NLP. The left eye was about LP. The patient had no motor or sensory deficit. Magnetic resonance (MR) imaging disclosed a huge bifrontal mass lesion (fig1,2), accompanied by prominent edema in both frontal lobes. Cerebral angiography demonstrated a tumor vascular rich and a major drainer through the diploic vein. After establishing four large IV lines, a right subclavian catheter and arterial line induction of general anesthesia was started. A bifrontal craniotomy was performed. We encountered massive bleeding from the diploic vein and dural mater immediately at the craniotomy. We were also faced with severe brain swelling at the dural incision. We ligated the distal part of the superior sagittal sinus immediately. The tumor was solid, highly vascularized, and fairly well demarcated. We performed total removal of the tumor by approach by laterally due to massive bleeding and once we debulked the mass we removed the tumor totally without scarification of any adjacent vital structure. We tried to maintain the patient's mean arterial pressure at about 70-75 mmHg and for bleeding compensation she received 14 units standard packed RBC, 10 units FFP and 10 units concentrated platelets. We estimated total inter operative bleeding to be about 6800cc. At the end of surgery, for ICP

reduction and preventing of probable hypoxic insult, the patient remained intubated and 4 mg/kg/hour sodium thiopental was infused for 28hrs. After termination of the sodium thiopental the endotracheal tube removed. The patient had an uneventful recovery and there was no new neurological deficit at follow-up. Finally cytopathologic study revealed a fibroblastic meningioma.

DISCUSSION

Though the majority of meningiomas are benign, they can have malignant presentations.

Meningiomas can usually be surgically resected with permanent cure if the tumor is superficial on the dural surface and easily accessible. Transarterial embolization has become a standard preoperative procedure in the preoperative management.^[6] If invasion of the adjacent bone occurs, total removal is nearly impossible. Malignant transformation is rare. We present a patient whose tumor location was in the bifrontal lobes and reviewed the available literature on hemorrhage associated with meningiomas. In our patient the recovery with no morbidity and mortality relates both to the fact that she had definitive surgery. However, the anesthesiologist applied meticulous control of blood loss and hemodynamic condition of the patient throughout the operation and ICU care. From our study it is apparent that definitive surgery with combined removal of the tumour resection in addition with proper anesthetic care provides the best chance for recovery with the least morbidity.

Figure 1

Figure 1

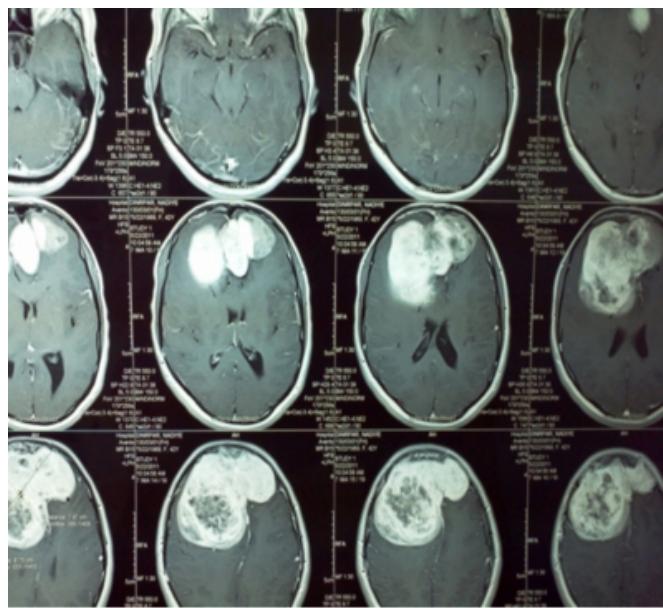


Figure 2

Figure 2

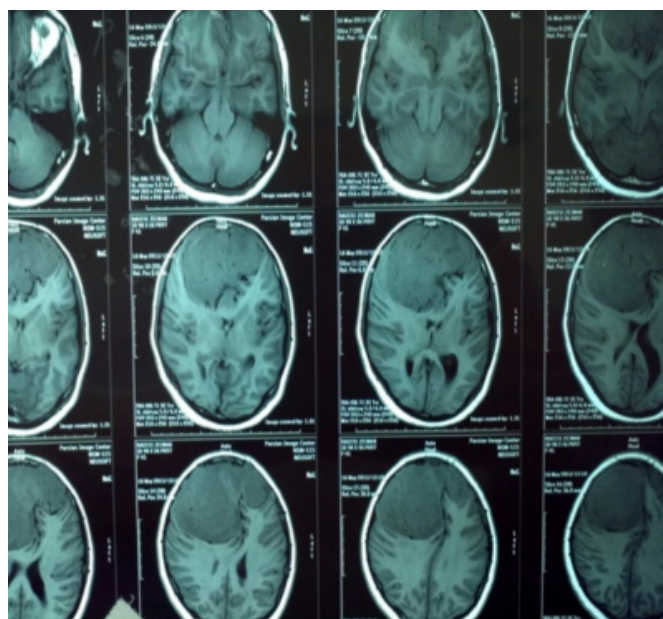
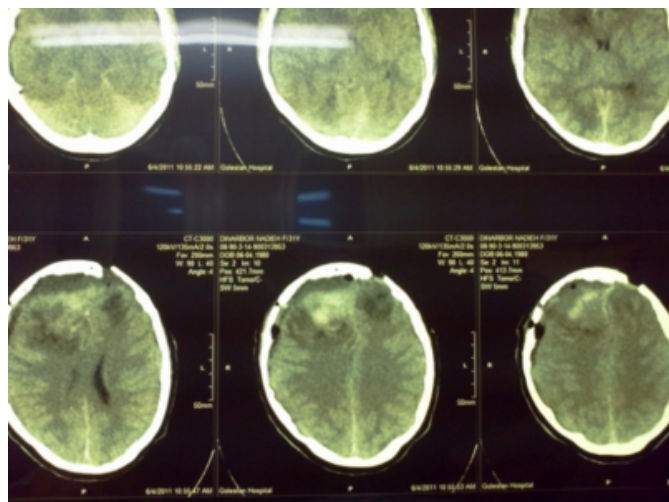


Figure 3

Figure 3: post operative imaging



References

1. Skullerud K, Loken AC. The prognosis in meningiomas. *Acta Neuropathol (Berl)* 1974; 29:337-44.
2. Sindm MP, Alaywan M: Most intraaerial meningiomas are not cleavable tumors: anatomical – surgical evidence and angiographic predictability neurosurgery 4W2:47F648Y0,1998
3. Nakao S, Sato S, Ban S, Inutsuka N, Yamamoto T, Ogata M. Massive intracerebral hemorrhage caused by angioblastic meningioma. *Surg Neurol* 1977;
4. Gruszkiewicz J, Doron Y, Gellei B, Peyer E. Massive intracerebral bleeding due to supratentorial meningioma. *Neurochirurgia (Stuttg)* 1969; 12:107-11.
5. Askenasy HM, Behmoaram AD. Subarachnoid hemorrhage in meningiomas of the lateral ventricle. *Neurology (Minneap.)* 1960; 10:484-9.

Author Information

A. Babashahi, MD

Assistant professor of Neurosurgery, Ahwaz Medical Science University

A. Ghomeishi, MD

Assistant professor of Anesthesiology, Ahwaz Medical Science University

L. Izadi, MD

Resident of Neurosurgery, Shahid beheshti Medical Science University

M. A. Mashari, MD

Resident of Neurosurgery, Ahwaz Medical Science University

I. Zaeem, MD

Resident of Neurosurgery, Ahwaz Medical Science University

S. Fallahpour, MD

Resident of Neurosurgery, Ahwaz Medical Science University

H. Safari, MD

Resident of Neurosurgery, Ahwaz Medical Science University

H. Mirzaei

Student of Hormozgan , Medical Science University, Iran