

Sebotrichoma

D Sarma, E Santos, B Wang

Citation

D Sarma, E Santos, B Wang. *Sebotrichoma*. The Internet Journal of Dermatology. 2006 Volume 5 Number 1.

Abstract

A benign adnexal skin tumor showing sebaceous and hair differentiation occurring in an 84-year-old man is reported. Such a tumor may be called a sebotrichoma.

SOURCE OF SUPPORT

None

REPORT OF A CASE

An 84-year-old white man presented with an enlarging, painless skin mass localized to the left side of his neck. There were no other symptoms or any other skin lesions. His past medical history was unremarkable and there was no history of systemic cancer.

The biopsied skin lesion showed a dermal mass composed of a well circumscribed, encapsulated benign lobular proliferation of sebaceous glands peripherally rimmed by basaloid cells with well differentiated sebaceous cells in the central portion of the lobules. There were several foci of duct-like structures with luminal lining by keratinous tissue consistent with hair (follicular) differentiation (Figures 1 and 2).

Figure 1

Figure 1: Sebotrichoma, low magnification: Encapsulated dermal tumor shows lobular epithelial proliferation. Peripheral basaloid cells blend centrally into sebaceous cells. Several duct-like structures with keratotic luminal lining (hair differentiation) are present.

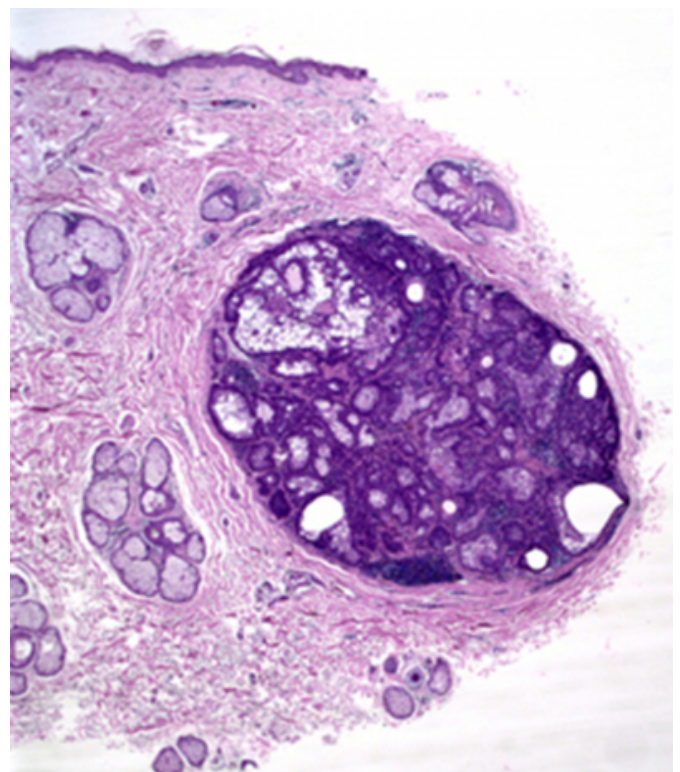
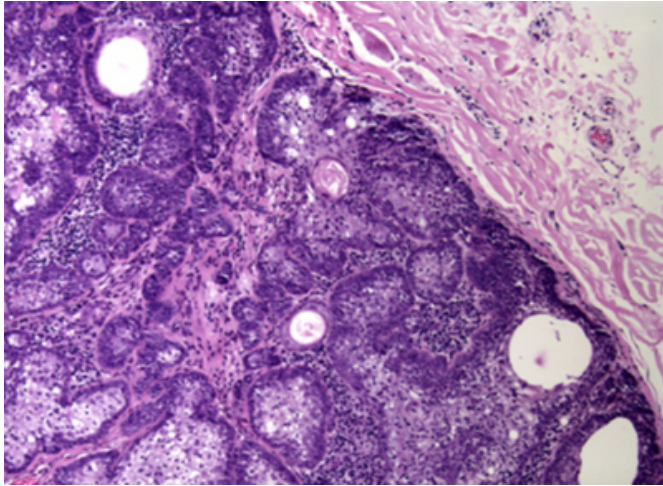


Figure 2

Figure 2: Sebotrichoma, high magnification.



Cytologic or nuclear pleomorphism and increased mitoses were not seen. We interpreted the lesion as a benign adnexal tumor showing sebaceous and hair differentiation.

COMMENT

Benign adnexal tumors arising from sebaceous glands have been described under various names, such as, sebaceous adenoma, sebaceoma, superficial epithelioma with sebaceous differentiation, sebomatrichoma etc. (1). In the present case, a simple name 'sebotrichoma' may clearly signify the tumor as a benign tumor composed of sebaceous and hair components.

CORRESPONDENCE TO

Deba P Sarma, MD Department of Pathology Creighton University Medical Center Omaha, NE 68131 Tel: 402-449-4951 E-mail: debasarma@creighton.edu

References

1. Patterson JW, Wick MR (2006): Nonmelanocytic tumors of the skin. AFIP Atlas of Tumor Pathology, Fourth Series, Fascicle 4. Washington, DC: Armed Forces Institute of Pathology, pp 119-124.

Author Information

Deba P. Sarma, M.D.

Professor, Department of Pathology, Creighton University Medical School

Eric E. Santos, M.D.

Senior Resident, Department of Pathology, Creighton University Medical School

Bo Wang, M.D.

Assistant Professor, Department of Pathology, Creighton University Medical School