

Trans Rectal Ultrasound Guided Injection Of Bladder Tumour Allowing Local Anaesthetic Resection In A High Risk Patient

G Lamb, M Hehir

Citation

G Lamb, M Hehir. *Trans Rectal Ultrasound Guided Injection Of Bladder Tumour Allowing Local Anaesthetic Resection In A High Risk Patient*. The Internet Journal of Urology. 2005 Volume 4 Number 1.

Abstract

Bladder cancer affects an elderly potentially unfit population. Low grade superficial disease confers an excellent prognosis following local resection assuming the patient can medically tolerate the procedure. We report a case where transrectal ultrasound guided local anaesthetic needle injection was used to safely allow rigid transurethral resection of a superficial tumour affecting the bladder base in a high risk patient deemed medically unfit for general or spinal anaesthetic.

INTRODUCTION

There are more than 10,000 people diagnosed with bladder cancer each year in the UK accounting for the fourth and tenth commonest malignancies in men and women respectively (<http://www.cancerhelp.co.uk>). The 1999 American Urological Association Guidelines on Bladder Cancer state that unless there is a medical contraindication, all visible bladder tumours should be removed (Smith et al., 1999). The initial tumour must be removed and subjected to histologic pathological review to determine the grade and stage. There are several acceptable methods that include transurethral resection, or combined with biopsy fulguration, cauterization, and laser vaporization.

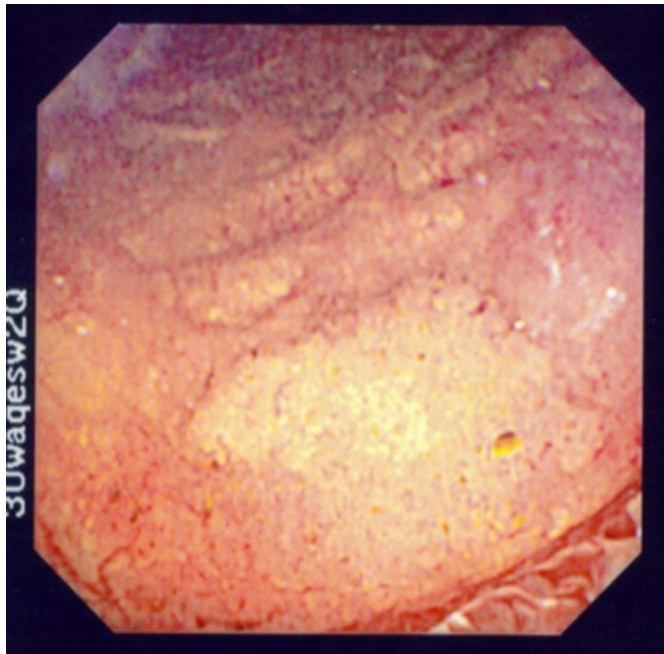
The incidence of bladder cancer increases with age and is associated with smoking which confers additional risks for both cardiac and respiratory co-morbidity in the affected population. As such a proportion of patients will have significant peri-operative mortality risk for what ultimately may prove to be low grade disease that is unlikely to progress (Solway, 2006). Previous reports have suggested the use of intravesical local anaesthetic in the outpatient management of patients with a known diagnosis of bladder cancer (Hedelin et al., 1997). We report the first case where a presumed diagnosis of bladder cancer in a patient deemed unfit for either general or spinal anaesthesia was treated successfully by transrectal ultrasound guided needle injection of local anaesthetic combined with rigid transurethral resection.

CASE PRESENTATION AND MANAGEMENT

A 78 male presented via his general practitioner having been referred with a short history of painless frank haematuria on a background of severe chronic obstructive airways disease. He was seen urgently for a flexible cystoscopy and found to have an approximate 5cm diameter flat lesion affecting his right side and bladder base (figure 1) consistent with a clinical diagnosis of a bladder tumour (an ultrasound examination of his upper tracts was reported as normal).

Figure 1

Figure 1: Flexible cystoscopic appearance of bladder tumour at diagnosis.

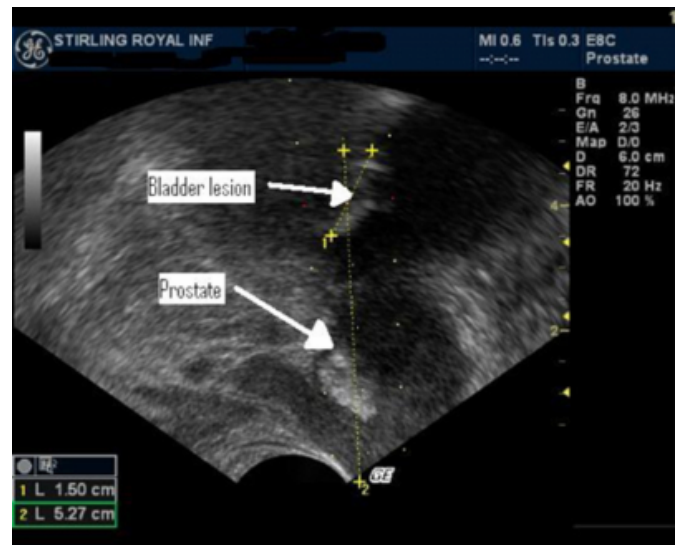


The patient was listed for urgent trans-urethral resection of bladder tumour and attended for pre-operative assessment at which point he was noted to be moderately obese, severely short of breath on minimal exertion and had an ejection systolic heart murmur. Subsequent pulmonary function tests confirmed mixed severe obstructive restrictive airway disease with a FEV1 less than one litre (age height predicted value 3.39). In view of the cardiac murmur he also underwent an echo-cardiogram which demonstrated moderately severe aortic stenosis. He was reviewed by both a cardiologist and an anaesthetist who determined that he was only suitable for minor surgery and not a candidate for spinal anaesthesia due to the risks of hypotension combined with his aortic stenosis.

Due to the 5 month delay in assessing his risk for intervention he underwent a further flexible cystoscopy to re-evaluate the tumour and determine the suitability for local anaesthetic resection. The lesion was noted to be unchanged from presentation and CT scanning showed only bladder thickening with no evidence of local extension or lymphadenopathy. He was therefore admitted and underwent Trans rectal ultrasound scanning on which the tumour was readily visible (figure 2) and amenable to local anaesthetic injection. The prostatic pedicles were injected using a 22 gauge 20cm long Chiba needle with 10 ml prilocaine 1% with 2ml at each prostate apex and 5ml into bladder lesion.

Figure 2

Figure 2: Trans rectal ultrasound view of bladder lesion prior to injection with local anaesthetic.



The patient then proceeded to theatre within fifteen minutes covered with intravenous fentanyl and medazolam and monitored using a blood pressure cuff and pulse/oximeter. A urethral dilation was carried out prior to passage of a 24 french gauge resectoscope sheath. A rigid resection of 1.7 grammes of tumour was carried out down to muscle and was well tolerated throughout by the patient. The patient reported some minor discomfort on resecting the far right lateral aspect of tumour which had been difficult to access for local anaesthetic infiltration due to the length of the needle. Subsequent pathology has demonstrated grade 3 pT1 transitional cell carcinoma of the bladder with no muscle invasion. Following discussion at the multidisciplinary team meeting he has been commenced on a course of BCG.

DISCUSSION

Although it is difficult to quantify exactly an individual person's potential operative mortality it was determined by two independent specialists that the patient described would be at significant risk. This clinical dilemma is not unusual in the management of patients with bladder tumours. The size and position of the tumour described in the above case has allowed the patient to undergo potentially curative surgery as well as accurate pathological staging to determine his disease prognosis. This has changed his management as an informed decision could be made regarding the necessity for post operative BCG therapy. Having reflected on our first experience using trans rectal ultrasound guided local anaesthetic infiltration we would consider using a longer needle in future cases to allow greater access. Trans rectal

ultrasound guided local anaesthetic needle injection is well tolerated and can be used safely to allow rigid transurethral resection of tumours affecting the bladder base in high risk patients without need for general or spinal anaesthetic.

References

r-0. J.A. Smith, R.F. Labasky and A.T.K. Cockett et al., Bladder cancer clinical guidelines panel summary report on

the management of nonmuscle invasive bladder cancer (stages Ta, T1 and TIS). The American Urological Association, J Urol 162 (1999), pp. 1697–1701.

r-1. Sloway MS. Expectant treatment of small recurrent, low grade, non-invasive tumours of the urinary bladder. Urologic Oncology 24 (2006), 58-61

r-2. Hedelin H, Holmang S, Wiman L. Outpatient treatment of bladder cancer- lower cost and satisfied patients. Norsk Medicin 112 (1997), 48-51.

Author Information

Gavin W.A. Lamb

Department of Urology, Stirling Royal Infirmary

Michael Hehir

Department of Urology, Stirling Royal Infirmary