

Ossified Pilomatricoma

P Sharma, D Sharma

Citation

P Sharma, D Sharma. *Ossified Pilomatricoma*. The Internet Journal of Dermatology. 2006 Volume 5 Number 2.

Abstract

Cutaneous ossification is as a primary event or secondary to a wide variety of inflammatory, traumatic, or neoplastic conditions. We describe a case of pilomatricoma with extensive ossification.

INTRODUCTION

Pilomatricoma is a benign tumor of hair matrix. It is most often seen in children and young adults as a slowly growing nodule in the skin of head and neck. We report a case of pilomatricoma with extensive ossification.

CASE REPORT

A 7 year old girl presented with a firm painless nodule situated in right post auricular area. An excisional biopsy was performed. The specimen consisted of a piece of yellow-brown hard tissue measuring 1.0 cm in maximum dimension. The tissue was submitted for microscopic examination following decalcification. Microscopic examination revealed interlacing bundles of ghost cells and extensive heterotopic ossification (Figures 1-3).

Figure 1

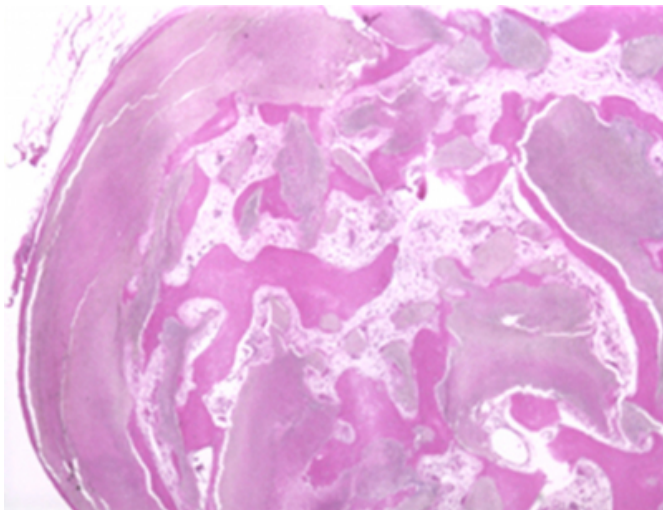


Figure 2

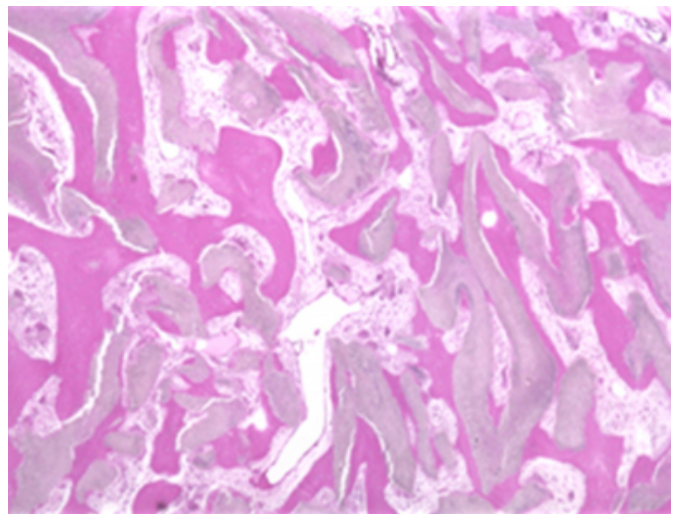
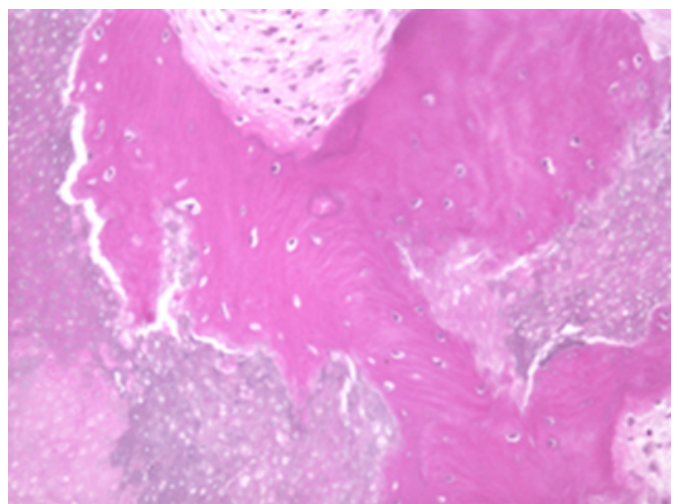


Figure 3



DISCUSSION

Pilomatricoma is a distinctive benign neoplasm that represents the prototype of matrical follicular differentiation.

The tumor frequently shows calcification and ossification. Extramedullary hematopoiesis may be seen in approximately 5% of tumors (1). The mechanism of occurrence of calcification and ossification remains unclear. Bone morphogenetic protein 2 (BMP-2) plays role in ectopic bone formation. BMP-2 has been found in shadow cells of pilomatricoma indicating that shadow cells may play a role in bone formation in pilomatricoma (2).

Pilomatricoma evolves through four morphological stages. It begins as an infundibular matrix cyst and ends up as a calcified and ossified nodule with no visible epithelial component (3). Extensive ossification seen in final stage of

neoplasm may simulate the appearance of a cutaneous osteoma if attention is not paid to the ghost elements, as in this case.

References

1. Kaddu S, Beham-Schmid C, Soyer HP, Hodl S, Beham A, Kerl H. Extramedullary hematopoiesis in pilomatricomas. *Am J Dermatopathol.* 1995;17(2):126-30.
2. Kurokawa I, Kusumoto K, Bessho K, Okubo Y, Senzaki H, Tsubura A. Immunohistochemical expression of bone morphogenetic protein-2 in pilomatricoma. *Br J Dermatol.* 2000;143(4):754-8.
3. Kaddu S, Soyer HP, Hodl S, Kerl H. Morphological stages of pilomatricoma. *Am J Dermatopathol.* 1996;18(4):333-8.

Author Information

Poonam Sharma

Department of Pathology, Creighton University Medical Center

Deba P. Sharma

Department of Pathology, Creighton University Medical Center