

Group B Streptococcus Endocarditis Following an Elective Abortion: A Case Report and Review of Literature

S Cardozo, J Luu, J Kao

Citation

S Cardozo, J Luu, J Kao. *Group B Streptococcus Endocarditis Following an Elective Abortion: A Case Report and Review of Literature*. The Internet Journal of Infectious Diseases. 2006 Volume 6 Number 1.

Abstract

Endocarditis caused by *Streptococcus agalactiae*, a group B streptococcus (GBS), is unusual; however, it can occur in association with obstetrical procedures and carries a high mortality rate. We describe a previously healthy patient who developed GBS mitral valve endocarditis after an elective abortion, and compare and contrast prior case reports.

INTRODUCTION

Since 1985, only 11 cases of Group B Streptococcus endocarditis following an obstetrical procedure have been reported in the English literature. The incidence of endocarditis following an obstetrical or gynecological procedure is low, ranging from 0.03 to 0.14 for every 1000.¹ The incidence of endocarditis following an abortion is one per million.² Group B Streptococcus accounts for 1.7% of all cases of endocarditis; though rare, it carries a mortality rate as high as 40%.³

CASE REPORT

A healthy 20 year old female with no significant medical history elected to have an abortion at 21 weeks of gestation. The procedure was uncomplicated, and afterwards, she continued in her usual state of health until one week following the abortion. At this time, she began to develop fevers, shortness of breath, intermittent nausea and vomiting, malaise, and fatigue. Her symptoms persisted for 2 weeks, and at this time, she presented to the hospital.

Upon presentation, her vital signs were: T: 99.7 ° F, P: 118, R: 30, BP: 98/62, SaO₂: 97% RA. On exam, she was a diaphoretic female with a 5cm JVP, a loud S1, a normal S2, and an apical 3/6 holosystolic murmur that radiated to the axilla. There were decreased breath sounds at the lung bases with variable egophany.

Her labs revealed a white blood cell count of 15.8 with a predominance of neutrophils (82%). After two sets of blood cultures were drawn, she was empirically started on Unasyn and Gentamicin.

The history of fever and a new murmur on physical examination raised concerns for endocarditis. A transthoracic echocardiogram showed a thickened mitral valve with moderate to severe mitral regurgitation, moderate to severe tricuspid regurgitation, and pulmonary hypertension with a pulmonary artery systolic pressure estimated at 60mmHg. A vegetation measuring 1.25 x 0.75cm was found on the posterior mitral leaflet. This was confirmed with a transesophageal echocardiogram.

Figure 1

Figure 1: A Transesophageal Echocardiogram, a vegetation measuring 1.25 by .75cm on the mitral valve posterior leaflet

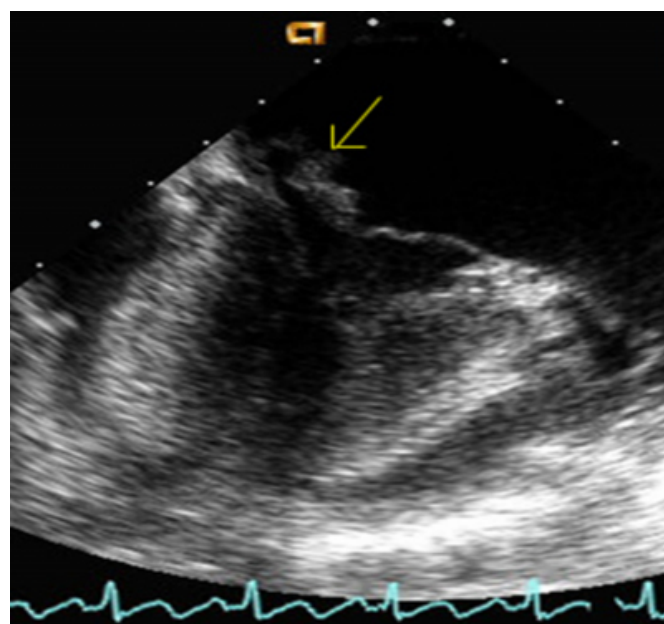
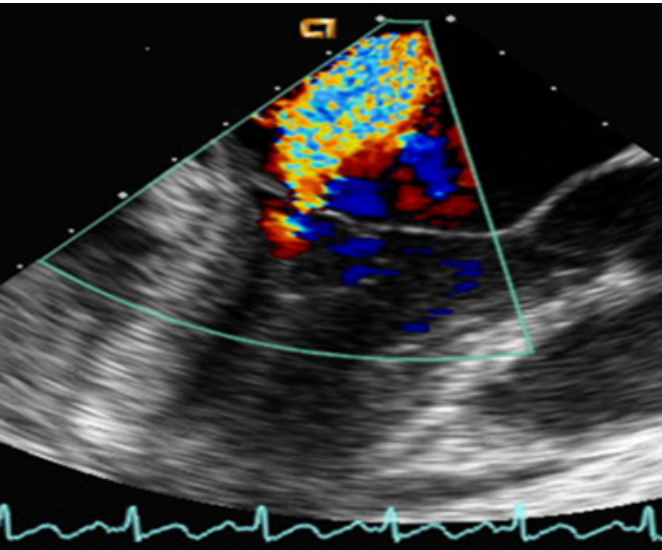


Figure 2

Figure 2: A Transesophageal Echocardiogram showing a thickened mitral valve with moderate to severe mitral regurgitation



A diagnosis of infective endocarditis was made as she now satisfied 2 of Duke's Major Criteria: new valvular regurgitation and echocardiographic evidence of an oscillating valvular mass (Figure 1). In the meantime, both sets of her blood cultures grew Group B Streptococcus. Her antibiotics were then tailored to Ceftriaxone.

Moderate to severe pulmonary hypertension in a patient with native valve endocarditis is an ACC Class IB indication for surgery. ⁴ She was continued on Ceftriaxone until her bacteremia resolved. Nine days later, she underwent a mitral valve replacement with a Carpenter-Edwards valve. A mechanical valve was chosen because she was a young patient.

Figure 3

Table 1: Duke's Criteria for Diagnosis of Infective Endocarditis, and ACC Guidelines for Surgery in Native Valve Endocarditis

| Duke's Criteria (Modified) | | ACC Guidelines |
|--|--|--|
| Major Criteria | Minor Criteria | Indications for Surgery in Native Valve Endocarditis |
| Sustained bacteremia by an organism known to cause endocarditis | Predisposing conditions: intravenous drug use, diabetes, indwelling venous catheters, hemodialysis, diabetes | Class I: Surgery indicated in: 1. Patients with valvular stenosis or regurgitation resulting in heart failure 2. Patients with aortic or mitral regurgitation with hemodynamic evidence of elevated LV end-diastolic or left atrial pressures, or moderate or severe pulmonary hypertension 3. Patients with infective endocarditis caused by fungal or highly resistant organisms 4. Patients with infective endocarditis complicated by heart block, annular or aortic abscess, or destructive penetrating lesions |
| Echocardiographic evidence: vegetation, abscess, prosthetic dehiscence | Vascular phenomena: septic arterial or pulmonary emboli, Janeway lesions, mycotic aneurysms | |
| | Immune phenomena: Osler's nodes, (++) Rheumatoid factor, Osler's nodes, Roth spots | |
| New valvular regurgitation | Fever | Class IIa: Surgery reasonable in: 1. Patients with infective endocarditis who present with recurrent emboli or vegetations despite antibiotic therapy |
| | Blood cultures positive for organisms not meeting major criteria | |
| | | Class IIb: Surgery can be considered in: 1. Patients with mobile vegetations greater than 10mm. |

She was anticoagulated after surgery, and continued her course of IV Ceftriaxone for five weeks. Follow-up blood cultures were negative. A follow-up echocardiogram showed a prosthetic mitral valve with trace mitral regurgitation and mild LV dysfunction. At six month follow-up, there was no clinical or physical evidence of congestive heart failure or significant valvular dysfunction.

DISCUSSION

Group B Streptococcus (GBS) is a gram positive organism that is a frequent colonizer of the female genitourinary tract, but only rarely causes disease in the adult female. GBS is primarily a pathogen in neonates, causing a wide variety of severe infections that include meningitis, pneumonia, and sepsis. Though rare, disease outside of the pediatric population is usually limited to pregnant females and immunocompromised patients. In pregnant females, GBS infections manifest as urinary tract infections, chorioamnionitis, postpartum endometritis, or bacteremia, while in immunocompromised patients they present as soft tissue infections or bacteremia without a focus. Endocarditis is exceedingly rare, and are unusual in the absence of predisposing factors that decrease polymorphonuclear cell function: malignancy, diabetes, intravenous drug use, and alcoholism.

GBS infection in neonates is well recognized; both the ACOG and AAFP have issued guidelines to screen women for GBS during the 35-37th week of pregnancy; those with

GBS in the genital tract are prophylaxed with Penicillin to prevent intrapartum infection of the newborn. There are, however, no guidelines addressing prophylaxis for the pregnant female during these procedures. There are also no guidelines for patients undergoing obstetrical procedures prior to the 35th week of pregnancy.

In the 11 case reports of Group B Streptococcus since 1985 associated with obstetrical and gynecological procedures, Crespo and colleagues found that 36% had pre-existing valvular heart disease. The precipitating event in 5 of 11 was an elective abortion. However, only one of these cases involved the mitral valve. In all cases (6) in which there was no underlying valvular disease, the tricuspid valve was involved. The aortic valve was involved in the remaining case, however, this patient had a prosthetic aortic valve. In light of this study, our index patient is unusual in that the mitral valve was involved in a patient with no predisposing valvular abnormality.

Figure 4

Table 2: Streptococcus Agalactiae Endocarditis Cases after Obstetrical Procedures

| Case | Age | GBS/Condition | Previous Cardiac Disease | Symptom Duration | Valve Infected | Size of Vegetation | Heart Failure | Valve Surgery/ Valve Type | Antibiotics | Year and Reference |
|------|-----|--------------------------------|--|------------------|----------------|--------------------|---------------|---------------------------|---|--------------------|
| 1 | 18 | Placental rupture of membranes | None | 3 days | Aortic | Not defined | No | No | Penicillin for 28 days plus gentamicin plus 14 days | 1985 ¹ |
| 2 | 30 | Vaginal delivery | Mitral/Valve prolapse with regurgitation | 4 weeks | Mitral | Not defined | No | No | Penicillin for 45 days plus gentamicin for 2 days | 1987 ² |
| 3 | 18 | Elective abortion | None | Several weeks | Tricuspid | 2.2 cm | No | No | Penicillin plus gentamicin for 6 weeks | 1990 ³ |
| 4 | 30 | Elective abortion | None | 1 month | Tricuspid | Not defined | No | Yes | Vancomycin for 28 days | 1991 ⁴ |
| 5 | 36 | Papercutaneous cervical smear | None | 7 days | Tricuspid | unknown | unknown | Yes | Penicillin plus gentamicin for 2 weeks, then ampicillin plus gentamicin for 6 weeks | 1997 ⁵ |
| 6 | 33 | Elective abortion | None | 4 weeks | Tricuspid | Not defined | No | Yes | Penicillin plus gentamicin for 6 weeks | 1998 ⁶ |
| 7 | 24 | Elective abortion | None | 4 weeks | Tricuspid | 2.0 by 2.0 cm | Yes | No | Penicillin plus gentamicin for 6 weeks | 2000 ⁷ |
| 8 | 60 | None | None | 12 weeks | Tricuspid | Not defined | No | No | Ampicillin and amikacin for unknown duration | 2001 ⁸ |
| 9 | 42 | Rheumatic heart disease | Rheumatic heart disease | 10 days | Tricuspid | Not defined | No | No | Penicillin plus gentamicin | 2002 ⁹ |
| 10 | 32 | Prosthetic mitral valve | Prosthetic mitral valve | 5 days | Mitral | Not defined | No | Yes | Penicillin plus gentamicin | 2002 ¹⁰ |
| 11 | 37 | Elective abortion | Prosthetic Aortic and Mitral valve | 4 days | Mitral | Not defined | No | No | Ampicillin plus gentamicin for 6 weeks | 2002 ¹¹ |
| 12 | 30 | Elective abortion | None | 2 weeks | Mitral | 1.25cm by 0.75cm | No | Yes | Ceftriaxone for 6 weeks | 2005 ¹² |

From 1988-1998, Sambola and colleges estimated the annual prevalence of Group B Streptococcus endocarditis from any cause as 1.3 cases per 1,000,000. Out of 1771 cases of endocarditis in 4 Spanish hospitals from 1975-1998; they found 30 cases of GBS endocarditis. In their study, only 1 out of 30 cases was precipitated by an abortion. 3 Even when endocarditis does occur following an abortion, the usual causative organisms are enterococci and Gram negative bacilli.

Though rare, GBS endocarditis is exceedingly aggressive,

carrying a mortality rate as high as 40%, a percentage as high as that seen in staphylococcal endocarditis. In patients with prosthetic valves, the mortality rate approaches 100%.^{5,6} GBS endocarditis more often affects left sided valves. Disease in left sided valves tends to lead to more extensive valve destruction. Therefore, early medical therapy is imperative. GBS has an MIC < 0.12 for penicillin, and is susceptible to all beta-lactam antibiotics. The current antibiotic therapy recommended for Group B Streptococcus endocarditis is a beta lactam antibiotic for 4-6 weeks with an aminoglycoside for 2 weeks. However the outcomes from patients treated with or without synergistic therapy were not significantly different. Some authors recommend early surgical treatment of left sided GBS endocarditis. From 1992-1998, as the percentage of patients who underwent cardiac surgery increased from 24% to 43%, the mortality rate of GBS endocarditis decreased from 61% to 8%.

While Group B Streptococcus infection in the adult is rare, it can be severe and can have long lasting sequelae. This case highlights the damaging effects of Group B Streptococcus on the adult mitral valve—severe mitral regurgitation and pulmonary hypertension that necessitated valve replacement in a 20 year old female. A high index of suspicion is therefore necessary to make the diagnosis.

References

1. Crespo A, Retter AS, Lorber B. Group B Streptococcal endocarditis in obstetric and gynecologic practice. *Infect Dis Obstet Gynecol.* 2003; 11 (2): 109-15.
2. Gallagher PG, Watankunakorn C. Group B streptococcal bacteremia in a community teaching hospital. *Am J Med* 1985; 795-800.
3. Sambola A, Miro JM, Tornos MP, Almirante B, Moreno-Torrico A, Gurgui M, Martinez E, Del Rio A, Azqueta M, Marco F, Gatell JM, and the Streptococcus agalactiae Endocarditis Study Group. Streptococcus agalactiae Infective Endocarditis: Analysis of 30 Cases and Review of the Literature, 1962-1998. *Clinical Infectious Diseases* 2002; 34: 1576-1584.
4. ACC/AHA 2006 Guidelines for the Management of Patients with Valvular Heart Disease, Vol. 48 No. 3 2006.
5. Gallagher PG, Watanlunakorn C. Group B streptococcal endocarditis: Report of seven cases and review of the literature 1962-1985. *Rev Infect Dis* 1986;8:175-88.
6. Scully BE, Spriggs D, Neu HC. Streptococcus agalactiae (group B) endocarditis: a description of 12 cases and review of the literature. *Infection* 1987; 15: 175-88.

Author Information

Shaun J. Cardozo, M.D.

Department of Internal Medicine, Division of Cardiology, University of Illinois Medical Center

Jane T. Luu, M.D.

Department of Internal Medicine, Division of Cardiology, University of Illinois Medical Center

John A. Kao, M.D.

Department of Internal Medicine, Division of Cardiology, University of Illinois Medical Center