

# Idiopathic Orbital Myositis And Review Of Literature

A Dubey, R Eidsness, R Koul

## Citation

A Dubey, R Eidsness, R Koul. *Idiopathic Orbital Myositis And Review Of Literature*. The Internet Journal of Ophthalmology and Visual Science. 2009 Volume 8 Number 2.

## Abstract

Orbital inflammatory disease includes a broad spectrum of disorders, ranging from diffuse involvement of multiple orbital structures to localized tissue inflammation. Orbital myositis is the most common non thyroid cause of orbital muscle diseases and may be idiopathic or secondary to any systemic and localized inflammatory disorders. We report a case of 69 year old female who presented with swelling of right eye muscles. There was no history of trauma, thyroid dysfunction or infection at this time. The laboratory data revealed normal T3, T4, TSH and ESR. The antinuclear antibodies were negative. CT scan of orbit defined soft tissue density mass was found in right orbit along the superior and lateral aspect. She did not show major response to steroid and immunosuppressant so was treated with external beam radiation. At 1 year follow up, clinically and radiologically she was in remission.

## INTRODUCTION

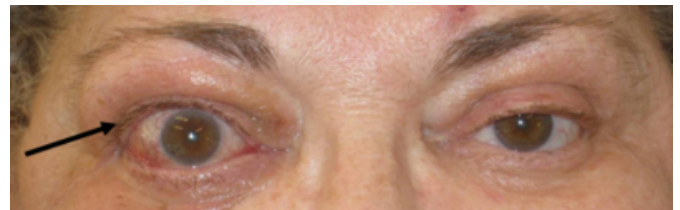One or more extraocular muscles infiltrated by an idiopathic inflammatory process are broadly termed as orbital myositis. Orbital myositis was described for the first time in 1903 in English literature<sup>1</sup>. It was merged with term “orbital pseudotumor.” In present time orbital myositis is now classified as part of the broader category of “orbital inflammatory disease” (OID)<sup>2</sup>. OID includes a broad spectrum of disorders, ranging from diffuse involvement of multiple orbital structures to a localized tissue inflammation. Orbital myositis is the most common non thyroid cause of orbital muscle diseases and could be idiopathic or secondary to any systemic and localized inflammatory disorders<sup>3</sup>. Orbital myositis is commonly treated by oral steroids however many patient recur despite being on long steroid therapy. External beam radiation has been proved to be an effective alternative modality of treatment. We report a rare case of orbital myositis that recurred on high dose of steroid and methotrexate based immunosuppressant therapy but did very well with local radiation.

## CASE REPORT

Sixty nine year-old pleasant lady who apparently had thyroid disease in the past, was treated with radioactive Iodine, and did quite well for the past 20 years. Recently, in the month of May 2009 she started having discomfort in her right orbit, pain on eye movement, swelling of right eye muscles (Figure 1).

## Figure 1

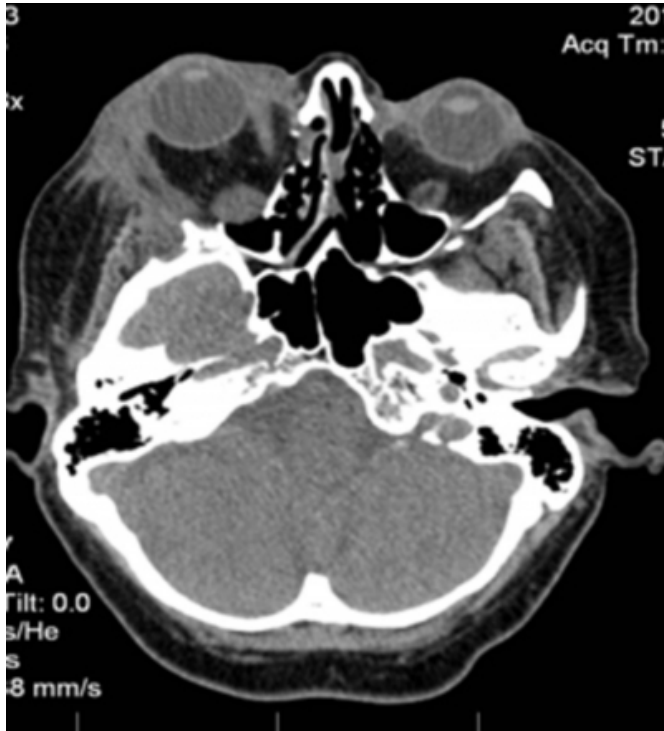
Figure 1; Clinical photograph showing abnormal, swollen right eye muscles with proptosis.



There was no history of trauma, thyroid dysfunction or infection. The laboratory data revealed normal T3, T4, TSH and ESR. The antinuclear antibodies were negative. CT scan of orbit defined soft tissue density mass was found in right orbit along the superior and lateral aspect. There was some enlargement of the lacrimal gland. Since her lesion was unilateral, thyroid associated myopathy was less likely (Figure 2).

**Figure 2**

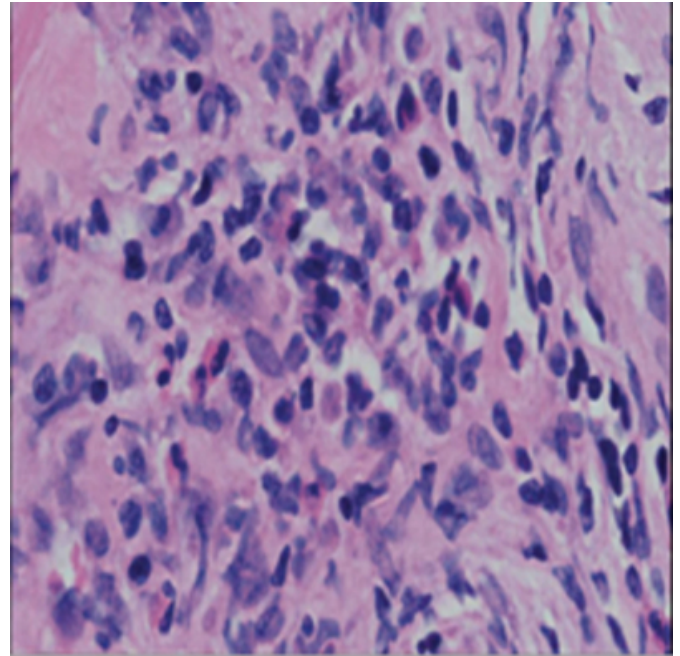
Figure 2 ; CT scan of orbit showing soft tissue density mass in right orbit along the superior and lateral aspect and some enlargement of the lacrimal gland .



Other differentials were orbital tumor, sarcoidosis, or metastasis. This was confirmed by echogram. Since she was quite symptomatic so was started on non steroidal anti inflammatory drugs which resolved symptoms for few days but recurred in 2 weeks time .She was started on prednisolone oral steroid therapy. She became dependant on steroid and still had progressive symptoms especially decrease in vision and frank proptosis. She continued on 20mg prednisone and 12.5 mg of methotrexate for two months. This combined therapy did not help much. Either. Patient in the month of December 09 had episode of severe pain, headaches, marked swelling and further decrease in vision. She underwent decompression surgery .The pathology from the right lacrimal gland and superior rectus muscle revealed dacryoadenitis, and myositis consistent with orbital inflammatory syndrome. Lymphocytes were mixture of CD; CD35 positive, T-cell CD 20 positive, B-cell plasma cells showed balanced light chain expression, CD10 was negative. The overall morphologic immunotype of the lymphocytic infiltrate was consistent with inflammatory orbital syndrome (Figure 3).

**Figure 3**

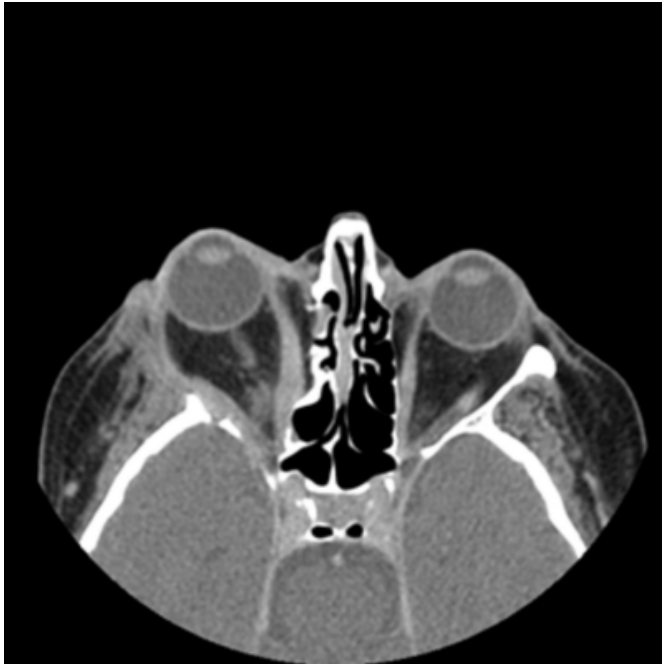Figure 3; Micrograph showing dacryoadenitis and myositis consistent with orbital inflammatory syndrome. Lymphocytes are CD35 positive and T-cell CD 20 positive but CD10 negative. B-cell plasma cells showed balanced light chain expression.



No evidence of any neoplasia. Despite decompressive surgery patient had progressive and significant discomfort 4 weeks post surgery. At this point Methotrexate was increased to 17.5 mg per week and she continued on daily dose of 20 mg oral prednisone. Patient felt that with the increase in dose of methotrexate she was more dizzy and exaggerated discomfort in upper abdomen. She felt that this therapy was not helping to alleviate her symptoms but adding on unnecessary tacitly which were significantly affecting her quality of life. Repeat CT scan showed 10 mm persistent proptosis and muscular enlargement with some enhancement of right extraocular muscles in the superior aspect of right orbit especially superior rectus. There was significant crowding at the orbital apex despite on steroid and MTX based treatment. Brain otherwise was normal. MRI study was incomplete because of claustrophobia patient was not able to complete the examination. Eventually case was discussed at multidisciplinary tumor board meeting and consensus was to offer low dose radiation. She received radiation to right orbit 20 Gray in 10 fractions on 6 MV photon machine. Patient tolerated radiation quite well. The symptoms resolved immediately and we were able to withdraw methotrexate and reduce oral steroid intake. Patient is doing clinically and radiologically very well at one year follow up (Figure 4).

**Figure 4**

Figure 4; CT scan at 1 year follow up shows resolution of right orbital myopathy



**DISCUSSION**

Idiopathic orbital myositis is classified as a subtype of nonspecific orbital inflammation usually involves the extraocular muscles. It occurs most frequently in young to middle-aged adults with a 2 to 1 female predominance<sup>4</sup>. The main clinical presentation is orbital pain exacerbated by eye movement, diplopia, proptosis, ptosis, conjunctiva injection, and periorbital edema. Patients usually have normal acuity<sup>5</sup>. Eye movements are paretic if in acute phase otherwise becomes quite restrictive in chronic phase. Muscles commonly involved are medial rectus (43%), superior rectus (19%), lateral rectus (17%), and rarely oblique's (5-10%) mainly inferior rectus<sup>6</sup>. An autoimmune process has been suggested as the ocular mechanism for idiopathic orbital inflammation by Atabay et al, 31 who reported the presence of circulating auto antibodies against eye muscle antigens<sup>7</sup>. Although autoimmunity is a plausible idea, it is not clear whether these auto antibodies are specific or are also present in other forms of inflammation, such as scleritis. In addition, the typical unilateral presentation of idiopathic orbital inflammation argues against the notion that autoimmunity is the primary mechanism. Alternatively, Mombaerts et al<sup>8</sup> and Rootman et al proposed aberrant immune-mediated production of fibrogenic cytokines causing delayed wound healing and incinerate the process of fibrosis<sup>9</sup>. Although benign, idiopathic orbital myositis may have a clinically malignant course, with severe vision loss and oculomotor

nerve dysfunction. Spontaneous remission may occur without any therapy, but systemic corticosteroids are the cornerstone of therapy in the acute phase<sup>10</sup>. Despite the initial favorable response to steroid therapy, relapses and recurrent inflammation are notoriously common and often complicate the clinical course and treatment. In many studies the idiopathic orbital inflammation has been associated with immunologic disorders such as Crohn disease, systemic lupus erythematosus, rheumatoid arthritis, diabetes mellitus, myasthenia gravis, and ankylosing spondylitis<sup>11</sup>.

The commonest differential diagnosis is thyroid eye disease which usually is characterized by a more acute onset, more severe pain, and a rapid response to systemic corticosteroid therapy. Other differential diagnosis quoted in literature is orbital infections, orbital neoplasms, carotid-cavernous fistula and cavernous sinus thrombosis<sup>12</sup>. Diagnosis is done by. A- and B-mode ultrasound. These investigations usually complement CT scanning in separating GO and IOL In the latter, B-scan commonly demonstrates discrete reterobulbar masses or edema in the posterior portion of Tenon's space. If fluid also surrounds the optic nerve sheath, there is a rather characteristic "T sign."<sup>13</sup> A-scan provides more or less accurate determinations of muscle diameters but probably cannot aid in categorically distinguishing between GO and IO. In modern medicine preference is upfront CT scan and or MRI orbit<sup>13</sup>.

Histopathological examination usually shows inflammation and is typically non diagnostic clumped as a broad term. It can range from the typical diffuse polymorphous infiltrate to the atypical granulomatous inflammation, tissue eosinophilia and infiltrative sclerosis. In the absence of systemic fibro inflammatory, granulomatous, and vasculitic disease these atypical presentations are considered to be idiopathic orbital inflammation<sup>14</sup>.

Acute orbital myositis will often respond to systemic corticosteroids at doses of 60 to 120 mg prednisone/day for two weeks, with subsequent tapering over weeks to months<sup>15</sup>. Prompt treatment is associated with dramatic improvement in symptoms, and a reduced risk of muscle fibrosis and recurrence. Treatment with nonsteroidal anti-inflammatory drugs has also had some success, but these drugs are not considered as effective as corticosteroids. Recurrent disease is not unusual; also, some cases have proven refractory to steroids, and orbital radiation has been tried with mixed results<sup>16</sup>. There are also cases of treatment with immunosuppressive drugs, but too few case reports

make recommendations on their utility. Patients with multiple recurrences, or those unresponsive to therapy should have biopsy samples taken to rule out any other hematological malignancy. Radiotherapy may be used in patients who fail to respond to steroids or have a rapidly progressive course. Several studies have reported favorable outcomes with radiation therapy, indicating that radiation therapy remains a viable treatment option for idiopathic orbital inflammation. Radiation therapy is an attractive alternative to steroid therapy, particularly given the relatively few potential adverse effects of low-dose external-beam radiation treatment, which include increased soft tissue inflammation that is generally self-limited. At approximately 20 Gy in 10 fractions the only ocular structure with a significant potential risk is the lens which can be changed as well once cataract sets in<sup>17</sup>. Serious side effects such as dry eye, retinopathy and optic neuropathy seldom occur at this dose, usually seen more than 50 Gray. In patients who are refractory to both corticosteroids and radiotherapy, anecdotal reports have suggested the use of chemotherapeutic agents such as cyclophosphamide and cyclosporine. Methotrexate and intravenous immunoglobulin have similarly been found to be effective in treating idiopathic orbital inflammation that did not respond to steroids<sup>18</sup>. The role of chemotherapy in the treatment of idiopathic orbital inflammation remains to be further explored<sup>19</sup>.

Surgical resection may be an effective alternative for more localized lesions. It is not a strong therapeutic option for diffuse, fibrotic orbital lesions that cannot be removed because of the involvement of vital structures. The ultimate surgical option is exenteration when no other treatment modality works but results in permanent visual loss<sup>20</sup>.

## CONCLUSION

The orbital myositis is a disease which is characterized by a heterogeneous, nonspecific inflammation usually involving the extraocular muscles. The importance of a rapid diagnosis and treatment is very essential and should be stressed. Majority of cases respond to oral corticosteroid therapy. However, there are majority of cases who require alternative therapeutic options if disease is deemed refractory. Relapses are very frustrating for patient as well as treating physician as there are few effective treatment options available for these refractory cases. Factors predictive of these recurrent and refractory cases need to be studied and properly delineated in future. However idiopathic orbital myositis still remains a diagnostic and therapeutic challenge in modern

medicine.

## References

1. Gleason JE. Idiopathic myositis involving the extraocular muscles. *Ophthalmic Rec* 1903;12: 471-8.
2. Birch-Hirschfeld A. Zur Diagnostik und Pathologie der Orbital Tumoren. *Ber Zusammenkunft Dtsch Ophthalmol Ges.* 1905;32:127-135.
3. Yuen SJ, Rubin PA. Idiopathic orbital inflammation: ocular mechanisms and clinicopathology. *Ophthalmol Clin North Am* 15:121-6; 2002.
4. Hankey GJ, Silbert PL, Edis RH, Nicoll AM. Orbital myositis: a study of six cases. *Aust N Z J Med* 1987;17 :585-91.
5. Slavin M, Glaser J. Idiopathic orbital myositis. *Arch Ophthalmol* 100:1261-163;1982.
6. Trokel SL, Hilal SK: Recognition and differential diagnosis of enlarged Extra ocular muscles in computed tomography. *Am J Ophthalmol* 1979; 87:503-512.
7. Atabay C, Tyutyunikov A, Scalise D, et al. Serum antibodies reactive with eye muscle membrane antigens are detected in patients with nonspecific orbital inflammation. *Ophthalmology.* 1995;102:145-153.
8. Mombaerts I, Schlingemann RO, Goldschmeding R, et al. What is orbital pseudotumor? *Surv Ophthalmol.* 1996;41:66-78.
9. Rootman J, McCarthy M, White V, Harris G, Kennerdell J. Idiopathic sclerosing inflammation of the orbit a distinct clinicopathologic entity. *Ophthalmology.* 1994; 101:570-584.
10. Jacobs D, Galetta S. Diagnosis and management of orbital pseudotumour. *Curr Opin Ophthalmol* 2002; 13:347-51.
11. Woo TL, Francis IC, Wilcsek GA, Coroneo MT, McNab AA, Sullivan TJ. Australian orbital and adnexal Wegner's granulomatosis. *Ophthalmology.* 2001;108: 1535-1543.
12. Serop S, Vianna RN, Claeys M, De Laey JJ. Orbital myositis secondary to systemic lupus erythematosus. *Acta Ophthalmol (Copenh).* 1994;72: 520-523.
13. Patrinely JR, Osborn AG, Anderson RL, Whiting AS. Computed tomography features of non thyroid extraocular muscle enlargement. *Ophthalmology.* 1989; 96:1038-1047.
14. Birch-Hirschfeld A. Zur Diagnostik und Pathologie der Orbital Tumoren. *Ber Zusammenkunft Dtsch Ophthalmol Ges.* 1905;32:127-135.
15. Mombaerts I, Schlingemann RO, Goldschmeding R, Koornneef L. Are systemic corticosteroids useful in the management of orbital pseudotumors? *Ophthalmology.* 1996;103:521-528.
16. Lanciano R, Fowble B, Sergott R, et al. The results of radiotherapy for orbital pseudotumor. *Int J Radiat Oncol Biol Phys.* 1990;18 :407-411.
17. Donaldson SS, McDougall R, Egbert PR, et al. Treatment of orbital pseudotumor (idiopathic orbital inflammation) by radiation therapy. *Int J Radiat Oncol Biol Phys.* 1980;6:79-86.
18. Culver E, Salmon J, Frith P, Travis S. Recurrent posterior scleritis and orbital myositis as extra-intestinal manifestations of Crohn disease: Case report and systematic literature review. *Journal of Crohn & Colitis,* 2(4): 337-342;2008.
19. Mombaerts I, Koornneef L. Current status in the treatment of orbital myositis. *Ophthalmology.* 1997;104:402-408.
20. Mannor GE, Rose GE, Moseley IF, et al. Outcome of orbital myositis: clinical features associated with recurrence. *Ophthalmology.* 1997;104:409-414.

**Author Information**

**Arbind Dubey, FRCPC**

Staff Radiation Oncologist, Allan Blair Cancer Centre, University of Saskatchewan

**Ryan Eidsness**

Staff Ophthalmologist, RQHR, University of Saskatchewan

**Rashmi Koul, FRCPC**

Staff Radiation Oncologist, Allan Blair Cancer Centre, University of Saskatchewan