

# Non-Traumatic Chylothorax

L Varadarajalu, M Jahandardoost, L Pyreddy, G Diaz-Fuentes

## Citation

L Varadarajalu, M Jahandardoost, L Pyreddy, G Diaz-Fuentes. *Non-Traumatic Chylothorax*. The Internet Journal of Pulmonary Medicine. 2007 Volume 10 Number 1.

## Abstract

Chylothorax is a rare cause of pleural effusion seen in approximately 2% of pleural effusions in adults and is associated with a 10% morbidity and mortality rate. Non-traumatic chylothorax in the adult is highly suggestive of malignancy, mainly lymphoma and metastatic carcinoma. Others etiologies include collagen vascular diseases and liver cirrhosis. Aggressive and early evaluation of pleural effusions is of the outmost importance, establishing the cause is essential in non-traumatic chylothorax. Pleural fluid and Radiologic studies including CT of the mediastinum and abdomen are recommended. We present a cases series and a review of non-traumatic chylothorax.

## INTRODUCTION

Chylothorax is the occurrence of chylus in the pleural space and is characterized by pleural fluid (PF) with a turbid or milky white appearance due to high lipid content. The lipids in a chylothorax consist of triglycerides that enter the pleural space as chyle; most commonly from disruption of the thoracic duct. In a normal adult, the thoracic duct transports up to 4 L of chyle per day, allowing a rapid and large accumulation of fluid in the chest.

Chylothorax is a rare cause of pleural effusion seen in approximately 2% of pleural effusions in adults and is associated with a 10% morbidity and mortality rate. Chylothorax is usually classified as traumatic and non-traumatic; the prevalence after various cardiothoracic surgeries is 0.2-1%.

We report a series of three patients presenting with chylothorax and we discuss the literature.

### CASE 1

A 46-year-old woman with no significant past medical history (PMH) was admitted to the Intensive Care Unit (ICU) with cough, dyspnea and fatigue of four days duration. She denied fever, weight loss or toxic habits. On examination she was tachypneic with a respiratory rate of 30/min, a pulse rate of 120/min, normal blood pressure and temperature. There were decreased breath sounds in both lungs fields and a one cm left supraclavicular lymph node nonmatted, nontender was noted. Initial laboratory showed a white blood cell count 6,000/mm<sup>3</sup>, hemoglobin 11 g/dl, liver

and renal functions were normal. Chest roentgenogram (CXR) showed bilateral large pleural effusion and lower lobe alveolar infiltrates. Pleural fluid (PF) obtained from the left pleural space was consistent with an exudative neutrophilic effusion and normal triglycerides (TG). Patient was started on antibiotics for possible community acquired pneumonia. Results of respiratory, PF, blood cultures and HIV test were negative. The patient's condition continued to deteriorate and she underwent a CT guided right thoracentesis on the third day of admission. The PF was an exudative lymphocytic chylous effusion with TG of 490 mg/dL (Table 1). Cytology of the right PF showed atypical lymphocytes. Lymph node biopsy of the supraclavicular node revealed Non Hodgkin's Lymphoma (diffuse B large cell). The patient was given chemotherapy and after a prolonged hospital stay she was discharged home with complete resolution of the pleural effusions.

### CASE 2

A 39 y/o male with AIDS was admitted with severe dyspnea of one-week duration. Remarkable PMH was Kaposi Sarcoma (KS) of the oral cavity. The patient had not received any treatment for the KS. On examination he was tachypneic (respiratory rate of 25/min), there were purple lesions in the upper palate and lower extremities and decreased breath sound in both lungs. The CXR showed large bilateral effusion. Thoracentesis of the left side revealed an exudative serosanguineous lymphocytic effusion with TG of 255 (Table 1). The patient refused all medical intervention and he died shortly after admission.

# CASE 3

A 42-year-old male with history of AIDS and liver cirrhosis due to Hepatitis C was admitted with fever, cough and respiratory failure that required intubation and mechanical ventilation. Examination revealed a cachectic man, febrile to 101°F, tachypneic with decreased breath sounds in the right side of the thorax and questionable ascitis on abdominal examination. A massive right pleural effusion was seen on CRX; thoracentesis showed a transudative effusion with TG of 184 mg/dL (Table 1). A chest tube was inserted for drainage. All septic work up that included blood, PF and respiratory cultures were negative. Sonogram of the abdomen showed ascites and liver changes consistent with cirrhosis. The patient condition continued to deteriorate and he died during the hospital admission.

## Figure 1

Table 1: Pleural fluid analysis of cases and comparison with literature

	Case 1 Lymphoma	Case 2 Kaposi	Case 3 Liver cirrhosis	Romero et al 1998 Cirrhosis n=5	Romero et al 1998 13 out of 19 cases were malignancies
Appearance Of Fluid	Turbid	Turbid	Clear	Milky	Milky or turbid
Ph	7.31	7.66	7.57	>7.35	N/A
LDH ratio	2.4	0.67	0.4	0.29 (0.19-0.43)	0.87 (0.38-10)
Protein ratio	0.62	0.8	0.2	0.27 (0.18-0.41)	0.6 (0.46-0.97)
TG	490	255	184	245 (143-555)	284 (115-1,652)
WBC (% lymphocytes)	6960 (80%)	69 (91%)	133 (65%)	N/A 90% (65-99%)	N/A 70 (4-100%)

PF: Pleural fluid, LDH: lactic dehydrogenase, TG: Triglycerides, WBC:

White cell count, N/A: not available

## DISCUSSION

The etiology of pleural effusions are diverse and ranges from local (lungs or pleura) to extrapulmonic or systemic diseases.

In many cases the cause is a chronic condition for which the patient is already receiving treatment; therefore, a patient with pleural effusion may present to a pulmonologist or other medical specialist. In up to 20% of cases the cause remains unknown despite extensive investigation. Chylothorax is a rare finding and is usually an exudative effusion. Fat in the intestines is absorbed into the lymphatics, which drain via the thoracic duct into the systemic circulation. The average flow of chylus in an adult is 2L/day; it increases with food and drink, and decreases significantly with starvation.

## ETIOLOGY:

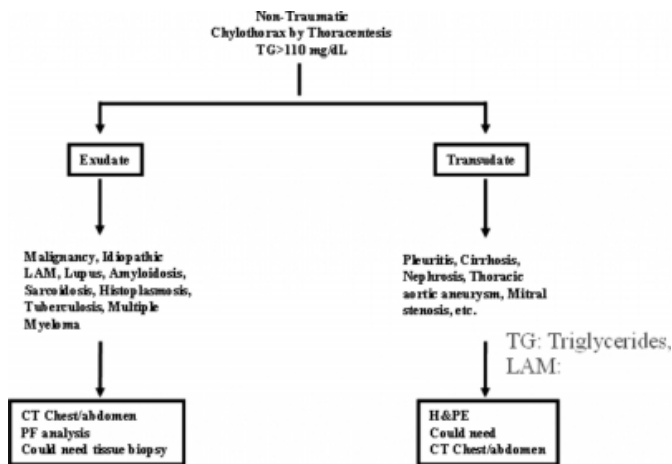
Chylothorax is uncommon and can be divided in non-traumatic (72%) traumatic (28%), and pseudo-chylothoraces

Figure 1. The most common etiologies for the non-traumatic chylothoraces are malignancies, especially lymphomas. In a study of 191 patients, lymphoma was found to be the cause of chylothorax in 37% of patients <sup>2</sup>. The mechanism of how malignancies cause chylothorax is unknown, but may be by either extrinsic compression or direct invasion of the thoracic duct <sup>2, 3</sup>. Non lymphomatous malignancy causes 9% of chylothorax <sup>4</sup>. The development of Chylothorax in patients with KS is probably a result of lymphatic obstruction. A study describing the clinical course and PF findings in patients with AIDS-associated pleural KS showed that 21 of 105 (20 %) cases had pleuropulmonary KS involvement and 13 (62 %) had pleural effusions. Chylothorax was present in two of the 13 cases with effusions. Pleural fluid analysis showed that most effusions were exudative, serosanguineous, with mononuclear cell-predominant. Neither cytological examination nor needle biopsy of the parietal pleura was able to establish the diagnosis. Median survival from diagnosis of KS to death was 205 days for patients with pleuropulmonary KS <sup>4</sup>.

Liver cirrhosis is a rare cause of chylothorax; his frequency has been reported in the range of 1 to 5 % <sup>5</sup>. Chylothorax / chyloascites are difficult to manage and are associated with poor prognosis; treatment in those patients involves management of the ascites and occasionally pleurodesis. Patients with liver cirrhosis and portal hypertension have increased thoracic duct lymph flow; chylothorax can result from transdiaphragmatic passage of chylous ascites. Cirrhotic chylothorax is always a transudate according to Light's criteria. Its uniform biochemical characteristics can facilitate its separation from chylous effusions of different etiology, therefore avoiding potentially harmful diagnostic and therapeutic procedures <sup>5, 6</sup>. Traumatic chylothorax are most often due to trauma, either iatrogenic, like thoracic surgery (05% cases) or non-iatrogenic trauma.

**Figure 2**

Figure 1: Etiology and Initial approach of Non-Traumatic Chylothorax



Lymphangiomyomatosis, CT: Computed

tomogram, PF: pleural fluid, H&PE: History and physical examination

The presentation and chest radiographic findings are nonspecific and indistinguishable from other causes of pleural effusion. Symptoms depend of rate of PF accumulation, so can have an acute or chronic presentation with acute or chronic progressive dyspnea. Physical examination usually reveals decreased breath sounds in the area of PF.

Patients with chylothorax due to liver cirrhosis have the tendency to have right side effusion, whereas patients with malignancy related Chylothorax have larger and usually bilateral or left-sided effusions.<sup>2, 7</sup>

## DIAGNOSIS

The diagnosis is made by finding more than 110 mg/dL of triglycerides in the PF. A TG level between 50 to 110 mg/dL may also represent a chylothorax; in that case a lipoprotein electrophoresis will show chylomicrons in the PF, confirming the diagnosis. The electrolyte content of chyle is similar to plasma, and the protein concentration is usually greater than 3 g/dL. The absence of a milky appearance does not exclude a chylothorax, especially if the patient is fasting or on a low fat diet. It also described as bloody, serous or turbid in as many as 50% of cases. Chylothorax is usually not associated with loculation and it usually does not become infected due to the high concentration of lymphocytes <sup>1</sup>.

## EVALUATION

In non-traumatic cases, a chest and abdomen CT scan is recommended in order to visualize any tumor or enlarged lymph nodes. A dilated duct can often be seen in cases where lymphatic obstruction produced the leakage. Lymphography can be helpful, as can an MRI.

## MANAGEMENT OF NON-TRAUMATIC CHYLOTHORAX

Conservative treatment with diet restrictions is successful in >50% of patients with traumatic chylothorax, but rarely so with chylothorax of other causes. A low-fat diet containing medium-chain triglycerides (which are absorbed into the blood) will decrease chylus production. If diet does not work, the next step is total parenteral nutrition. In non-traumatic cases, spontaneous resolution is less likely. <sup>8, 9</sup>

The success of chemical pleurodesis is limited but could be tried <sup>10</sup>. Surgery is the last resort; ligation of the duct at the level of the diaphragm is successful in up to 90% of patients.

Patients with underlying lymphoma or metastatic cancer frequently respond to therapy directed at the primary tumor or metastatic sites. Some reports showed that 68% of patients with lymphoma and 50 % of those with metastatic carcinoma had resolution of the chylothorax after radiation therapy. <sup>2, 3</sup>

## CONCLUSION

Pleural effusions are a common finding in any clinical practice. The physicians should be aware of the rare presentations of common diseases. Chylothorax is rare, and should be suspected in patients with the above mentioned pathologies. It will be useful to include the measurement of triglycerides in the routine PF panel. The presence of a chylothorax entitles a poor prognosis especially in patients with liver cirrhosis or KS.

## CORRESPONDENCE TO

Gilda-Diaz Fuentes, MD, FCCP Assistant Professor of Medicine at Albert Einstein College of Medicine Chief of Pulmonary and Critical Care Bronx Lebanon Hospital Center, Bronx, NY 1650 Grand Concourse, Pulmonary Division. Bronx, NY 10457 Phone: (718) 960-2003 Fax: (718) 518-5704 e-mail: gdf.gdfuentes210@verizon.net

## References

1. Doerr, CH, Miller, DL, Ryu, JH. Chylothorax. Semin Resp Crit Care Med 2001; 22:617-626.
2. O'Callaghan AM, Mead GM. Chylothorax in lymphoma: mechanism and management. Ann Oncol 1995; 6: 603-607.

3. Valentine VG, Raffin TA. The management of chylothorax. *Chest* 1992; 102: 586-591.
4. RF O'Brien and DL Cohn Serosanguineous pleural effusions in AIDS-associated Kaposi's sarcoma *Chest* 1989; 96(3):460-466
5. Romero S, Martin C, Hernandez L, Verdu J, Trigo C, Perez-Mateo M, Alemany L. Chylothorax in cirrhosis of the liver: analysis of its frequency and clinical characteristics. *Chest*. 1998 Jul; 114(1):154-9.
6. Mokshagundam SP, Minocha A. Massive chylothorax complicating cirrhosis of the liver. *South Med J*. 1996 Sep; 89(9):927-30.
7. Margolis M., MacDonald E., Green P. et al. An Unusual Case of Chylothorax in an HIV-infected Patient with Kaposi's sarcoma. *Resident & Staff Physician*. April 05; 22.
8. Browse NL, Allen DR, Wilson NM. Management of chylothorax. *Br J Surg* 1997; 84:1711-6.
9. Marts BC, Naunheim KS, Fiore AC, Pennington DG. Conservative versus surgical management of chylothorax. *Am J Surg* 1992; 164:532-4.
10. Sudduth CD, Sahn SA. Pleurodesis for nonmalignant pleural effusions. Recommendations. *Chest* 1992; 102:1855-60.

**Author Information**

**Lakshmi Varadarajalu, MD**

Pulmonary Fellow, Division of Pulmonary Medicine, Bronx Lebanon Hospital Center

**Mohammed Jahandardoost**

Internal medicine Resident, Department of Internal Medicine, Bronx Lebanon Hospital Center

**Lovrdu Pyreddy, MD**

Pulmonary Fellow, Division of Pulmonary Medicine, Bronx Lebanon Hospital Center

**Gilda Diaz-Fuentes, MD, FCCP**

Chief of Pulmonary and Critical Care Division, Bronx Lebanon Hospital Center