

Fistulous communication between hepatic hydatid cyst and stomach

M Mahmoodieh, B Sanei, R Sobhani, R Samani, B Tavakoli, S Alesaeidi, A Motamedi

Citation

M Mahmoodieh, B Sanei, R Sobhani, R Samani, B Tavakoli, S Alesaeidi, A Motamedi. *Fistulous communication between hepatic hydatid cyst and stomach*. The Internet Journal of Surgery. 2008 Volume 19 Number 2.

Abstract

Objectives: Hydatid disease primarily affecting the liver, demonstrates characteristic imaging findings but findings of unusual anatomic locations are less frequently described in the literature. We present a very rare presentation of hydatid disease. **Case report:** A 42-year-old woman was admitted to Al-Zahra Hospital in Isfahan complaining of abdominal pain, fever and jaundice. Ultrasonography showed a hepatic cyst and dilated intrahepatic ducts and common bile duct. CT scan confirmed a fistula between cyst and stomach. Surgery was performed and pathology confirmed cystogastric fistula. The patient had no problems in a 6-months follow-up period. **Conclusions:** Spontaneous rupture of a hydatid cyst into hollow viscera is an extremely rare complication. Typically, the fistula is not discovered until surgery, although in some patients it is found at radiology. Furthermore, frank rupture into the biliary tree occurs in 5-15% of cases. Familiarity with atypical manifestations of hydatid disease may be helpful in making accurate diagnosis and treatment.

INTRODUCTION

Hydatid disease is a worldwide zoonosis produced by the larval stage of the echinococcus tapeworm. This disease primarily affects the liver and typically demonstrates characteristic imaging findings. However, it has many potential local complications including biliary complications and perforation into hollow viscera.

The classical findings in hydatid disease are well known; however, findings related to complications and unusual anatomic locations are less frequently described in the literature (1). We present a case of hepatic hydatid disease presenting a cystogastric fistula as an extremely rare complication.

CASE REPORT

A 42-year-old woman was admitted to Al-Zahra Hospital in Isfahan in July 2008, complaining of abdominal pain, fever and jaundice. The patient had a history of dyspepsia, abdominal pain and jaundice intermittently from 6 months before admission with increased severity of pain and jaundice during 30 days before hospitalization. Past history was normal. On physical examination, the patient was febrile and icteric.

Abdominal ultrasonography showed a large cyst of the left

liver lobe and dilatation of intrahepatic ducts and common bile duct. Upper endoscopy (done because of dyspepsia and epigastric pain) revealed an orifice in the greater curvature of the stomach at the junction of body and antrum. Abdominopelvic CT scan showed fistulous communication between hepatic hydatid cyst and stomach (figure 1).

Midline laparotomy was performed and the following procedures were done:

- a- Evacuation of the hydatid cyst of the left liver lobe
- b- Biopsy of the stomach at the site of the orifice of the fistula and repair of the stomach in two layers
- c- Cholecystectomy, exploration of CBD and removal of the laminated layer of the hydatid cyst from the CBD.
- d- Choledochoduodenostomy

Pathologic examination confirmed a hydatid cyst fistula to the stomach (figure 2).

The patient was discharged after 5 days of hospitalization and had no problems in a 6-months follow-up period.

CONCLUSION

Spontaneous rupture of a hydatid cyst into hollow viscera is

an extremely rare complication with an estimated frequency of 0.5% (2). This complication may be accompanied by clinical findings of hydatidemia or hydatidorrhea (3). Typically, the fistulous communication is not discovered until surgery; although in some patients it is found at radiology (3). CT scan may demonstrate a cyst with an air-fluid level or oral contrast material inside the cavity. Barium-enhanced CT can be used to demonstrate the fistula between the cyst and the hollow viscus. Furthermore, biliary communication of hydatid disease has been described in up to 90% of hepatic cysts (2, 4). However, frank rupture into the biliary tree occurs in only 5-15% of cases (2).

Jaundice, fever and chills are the most frequent symptoms related to biliary obstruction and cholangitis (5). CT is the modality of choice in depicting hydatid cyst contents in the CBD, although endoscopic retrograde cholangiography may provide an excellent diagnostic and therapeutic modality in surgically high-risk patients (6).

Familiarity with these atypical manifestations of hydatid disease may be helpful in making an accurate diagnosis and treatment.

Figure 1

Figure 1: CT scan showing fistulous communication between hepatic hydatid cyst and stomach

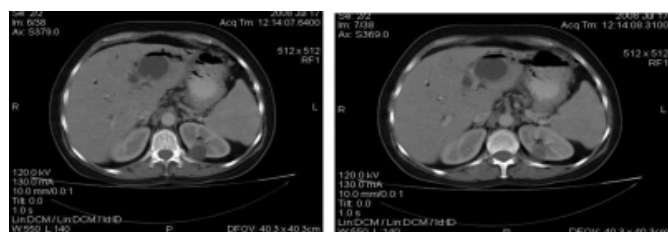
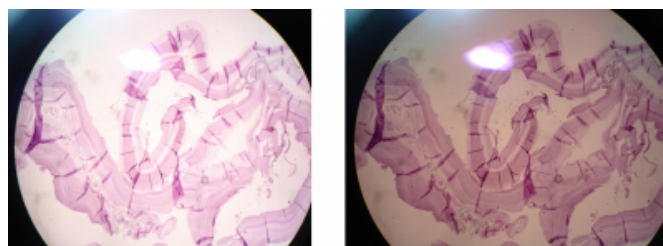


Figure 2

Figure 2: Pathology revealing the laminated layer of the hydatid cyst



CORRESPONDENCE TO

Reza Eshraghi Samani Address: 27, 5th floor, Shahrivar block, Moshtagh building, Jeyshir Street, Isfahan, Iran. Tel: +983112630716 E-Mail: eshraghireza@yahoo.com

References

1. Lewall DB. Hydatid disease: biology, pathology, imaging and classification. Clin Radiol 199; 52: 863-874.
2. Moguillanski SJ, Gimenez CR, Villavicencio RL. Radiologia de la hidatidosis abdominal. Vol 2. Philadelphia, PA: Lippincott, Williams and Wilkins 1999; 47-72.
3. Jain R, Dawhney S, Berry M. Hydatid disease: CT demonstration and follow-up of a cystogastric fistula. AJR Am J Roentgenol 1992; 158: 212.
4. Mendez JV, Arrazola J, Lopez J, et al. Fat-fluid level in hepatic hydatid cyst: a new sign of rupture into the biliary tree? AJR Am J Roentgenol 1996; 167: 91-94.
5. Ulualp KM, Aydemir I, Senturk H, et al. Management of intrabiliary rupture of hydatid cyst of the liver. World J Surg 1995; 19: 720-724.
6. Manouras A, Genetzakis M, Antonakis PT, et al. Endoscopic management of relapsing hepatic hydatid cyst with intrabiliary rupture: a case report and review of the literature. Can J Gastroenterol 2007; 21: 249-53.

Author Information

Mohsen Mahmoodieh, MD

Assistant Professor, Department of General Surgery, AL-Zahra Hospital, Isfahan Medical University

Behnam Sanei, MD

Assistant Professor, Department of General Surgery, AL-Zahra Hospital, Isfahan Medical University

Roohollah Sobhani, MD

Resident of General Surgery, Department of General Surgery, AL-Zahra Hospital, Isfahan Medical University

Reza Eshraghi Samani, MD

Resident of General Surgery, Department of General Surgery, AL-Zahra Hospital, Isfahan Medical University

Babak Tavakoli, MD

Resident of Radiology, Department of General Surgery, AL-Zahra Hospital, Isfahan Medical University

Samira Alesaeidi, MD

Resident of Internal Medicine, Department of General Surgery, AL-Zahra Hospital, Isfahan Medical University

Azadeh Motamedi

Staff, Department of General Surgery, AL-Zahra Hospital, Isfahan Medical University