

Local Glyceryl Trinitrate Versus Lateral Internal Sphincterotomy In Management Of Anal Fissure

G El-Labban, G El-Gazzaz, E Hokamam

Citation

G El-Labban, G El-Gazzaz, E Hokamam. *Local Glyceryl Trinitrate Versus Lateral Internal Sphincterotomy In Management Of Anal Fissure*. The Internet Journal of Surgery. 2009 Volume 22 Number 2.

Abstract

Aim of the work: We aimed to evaluate the effectiveness of local glyceryl trinitrate (GTN) versus surgical lateral internal sphincterotomy in the management of acute and chronic anal fissure. **Patients and methods:** We divided our patients into two groups; group 1 included 40 patients with anal fissure treated with topical GTN 0.2% and group 2 also included 40 patients, treated with lateral internal sphincterotomy. **Results:** In group 1, healing of fissures occurred in 85% of patients after 8 weeks therapy. Headache as a side effect developed in 65% of patients. In group 2, healing occurred in 97.5% of patients after 8 weeks. Incontinence to flatus occurred in 3 patients (7.5%) and mild soiling occurred in 2 patients (5%), but all were temporary. The improvement in group 2 was faster than in group 1 but at the end of 8 weeks both groups became equal in pain score. The main anal resting pressure (MARP) assessment changes in the two groups were nearly equal. **Conclusion:** We conclude that topical application of nitroglycerin represents a new, easily handled and effective alternative in the treatment of anal fissure.

INTRODUCTION

Anal fissure is one of the most painful conditions encountered in surgical practice, and causes considerable morbidity and reduction in quality of life.⁽¹⁾

Anal fissure is a linear tear in the lining of the distal anal canal below the dentate line. It is a common condition affecting all age groups, but is seen particularly in young and otherwise healthy adults, with equal incidence across the sexes. The classical symptom is anal pain during or after defecation accompanied by the passage of bright red stool. In addition, pruritus ani may accompany up to 50% of anal fissures.⁽²⁾

Subcutaneous lateral sphincterotomy remains the gold standard for management of chronic anal fissure because of its simplicity, rapid healing and low recurrence rate. However, disadvantages of lateral sphincterotomy including disturbance of continence, bleeding, fistula, abscess, persistent wound pain, cost and time of recovery⁽³⁾ have led to search for a mode of therapy or pharmacological way to create a temporary or reversible sphincterotomy, one that would lower sphincter pressure only until the fissure had healed.⁽⁴⁾

Local GTN can reduce the increased anal canal pressure

caused by a hypertonic internal anal sphincter and improve anodermal blood flow, as surgical lateral sphincterotomy. Reversible chemical sphincterotomy produced by local GTN has been used successfully for healing in anal fissure, with minimal side effects and avoiding the need for operative intervention.⁽⁵⁾

Topical GTN can be used with liposomal base as a delivery system, liposomes are most useful to transfer and deliver active ingredients to application sites, which leads to more efficacy of the drug. In view of this and the fact that the optimal therapeutic strength of GTN is still to be determined, we aimed to evaluate the use of topical GTN versus surgical lateral internal sphincterotomy in the management of anal fissure.⁽⁶⁾

PATIENTS AND METHODS

The study is a clinical prospective randomized controlled study, hospital-based, and was carried out on patients who were diagnosed clinically with anal fissure and attended to in the outpatient clinic of the surgical department of Suez Canal University Hospital.

The study was carried out on male and female patients aged 18-60 years who were diagnosed clinically with acute and chronic anal fissures. Patients with complicated anal

fissures, with other anal problems (as piles), with previous anal surgery, with systemic diseases (diabetes mellitus, chronic liver disease and collagen diseases), and patients under treatment with nitrates for other diseases, e.g. ischemic heart diseases were excluded from the study. Pregnant women and children were also excluded.

METHODS AND PROCEDURES

Full detailed history, especially about symptoms of anal fissure including anal pain during and after defecation, bleeding, discharge and itching and duration of these symptoms were obtained from the patients. Possible causes of anal fissure as history of constipation and anal trauma were also reported.

Digital rectal examination was done to palpate for presence of spasm and tenderness. The presence of a linear ulcer in the distal anal canal, indurations and a sentinel skin tag, with the previous symptoms, was enough for clinical diagnosis.

According to outcome, fissures were classified as; (a) acute, anal fissure with less than 6 weeks of duration, and (b) chronic anal fissure, more than 6 weeks of duration with preserved symptoms (pain, bleeding), marginal indurations and sphincter muscle.

Each patient agreed to participate in the study after being informed in detail of the aim of the study, and fully informed written consent was obtained from each patient prior to entry into the study.

According to the method of treatment, the patients were divided randomly into two groups:

Group (1), which included 40 patients with acute and chronic anal fissure who agreed to have the medical treatment with local GTN 0.2% cream (in liposomal base): Each patient was instructed to apply about 0.5g “per size amount” of GTN manually at the distal anal canal (lower half of the anal canal and anal verge) twice daily for eight weeks. All patients were advised to receive stool softeners and fiber supplements diets.

N.B. To patients in group 1 with persistent fissure after treatment, or those unable to tolerate treatment with GTN, surgical sphincterotomy was offered. These patients were excluded from the study (failure of GTN treatment).

Group (2), which included 40 patients with acute and chronic anal fissure who agreed to have surgical treatment with lateral internal sphincterotomy: All patients were

treated by the same surgeons using a uniform method in the lithotomy position with the same technique of internal lateral sphincterotomy.

Assessment of the patients in the two groups:

MARP assessment

The pressure changes in the anal sphincter (MARP) were recorded in each group using anal manometry at the first visit (before treatment), and repeated after 20 min. of application of topical GTN and after surgical lateral internal sphincterotomy.

Follow-up assessment:

All patients in each group were followed up at 2-week intervals for 8 weeks, in order to evaluate the improvement as following:

1- Pain, assisted by visual analogue score (VAS) in all patients. Patients were asked to indicate a point on the 100mm line, with one end of the line representing no pain on defecation and the other representing the worst pain they could imagine.

2- Bleeding (for absent or present).

3- Fissure healing: the anus was examined by inspection to assess healing of the fissure which means complete epithelization of the fissure or persistence of the fissure, and the time of complete healing.

4- Appearance of any adverse effect.

All patients were reassessed after one month and three months for evidence of recurrence of the fissure and the presence of possible side effects.

RESULTS

Group 1:

Patients treated with local application of GTN 0.2%: This group consisted of 40 patients; 20 patients (50%) with acute anal fissure and 20 patients (50%) with chronic anal fissure. Sixteen patients (40%) were male and the other 24 patients (60%) were females. The age ranged from 18 to 60 years with a median age of 36 years.

Presenting with anal pain were 40 patients (100%), with anal pain and constipation 28 patients (70%) and with anal pain and bleeding 16 patients (40%). Thirty-five patients (87.5%) had posterior anal fissures, one patient (2.5%) an anterior

anal fissure and 4 patients (10%) posterior and anterior anal fissures.

Group 2:

Patients who underwent lateral internal sphincterotomy: This group also consisted of 40 patients; 20 patients (50%) with acute anal fissure and 20 patients (50%) with chronic anal fissure. Twenty patients of them (50%) were males and 20 (50%) were females. The age ranged from 18 to 60 years with a median age of 36 years.

Presenting with anal pain were 40 patients (100%), with anal pain and constipation 30 patients (75%) and with anal pain and bleeding 14 patients (35%). Thirty-one patients (77.5%) had posterior anal fissures and 9 patients (22.5%) anterior and posterior anal fissures.

MARP assessment:

The main pre-treatment MARP was 122 ± 44cm H₂O in group 1 and 120 ± 44cm H₂O in group 2; this was comparable in both groups. The mean value of MARP dropped by 40.5% to 72 ± 31.1cm H₂O after application of GTN in group 1; this post-treatment drop in pressure of 49.5cm H₂O was statistically highly significant (P-value 0.0001). In group 2, the mean MARP dropped by 43.3% to 68.2 ± 31.3cm H₂O; this drop of 51.8cm H₂O was also statistically highly significant (P-value 0.0001). The difference in reduction of MARP between topical GTN and sphincterotomy (4.3cm H₂O) was not statistically significant showing that both modalities of treatment were equally effective in reducing the MARP in anal fissures.

Follow-up assessment:

Follow-up after 2 weeks in group 1:

Pain score fell from 100 at the beginning of treatment to 70 at the end of 2 weeks. Absence of bleeding increased from 60% (24 patients) at the beginning of treatment to 85% (34 patients) at the end of 2 weeks. Twelve patients (with 3 chronic and 9 acute fissures) (30%) showed complete healing by inspection after 2 weeks. At the beginning of the treatment, 26 patients (65%) developed headache as a side effect of the treatment, although usually moderate to mild and tolerable, and often diminishing in intensity and duration with continued application.

Follow-up after 4 weeks in group 1:

Pain score fell from 70 after 2 weeks to 40 at the end of the

4th week. Absence of bleeding increased from 85% (34 patients) at the end of 2 weeks to 95% (38 patients) at the end of the 4th week. Twenty patients (with 5 chronic and 15 acute fissures) (50%) showed complete healing by inspection after 4 weeks. Only 8 patients (20%) had mild tolerable headache at the end of the 4th week.

Follow-up after 6 weeks in group 1:

Pain score fell from 40 after the end of the 4th week to 20 at the end of the 6th week. Absence of bleeding increased from 95% (38 patients) at the end of the 4th week to 97.5% (39 patients) at the end of the 6th week. Twenty-seven patients (with 8 chronic and 19 acute fissures) (67.5%) became healed at the end of the 6th week. Only 4 patients (10%) had continuing mild tolerable headache.

Follow-up after 8 weeks in group 1:

Pain score fell to 10 at the end of the 8th week and absence of bleeding became 97.5% (39 patients) at the end of the course of treatment. Thirty-four patients (with 14 chronic and 20 acute fissures) (85%) became completely healed of anal fissure (by inspection) at the end of the 8th week. The headache stopped after the 6th week and no patients had headache after the 6th week.

Follow-up after one month in group 1:

There were no relapses or complications.

Follow-up after 3 months in group 1:

One patient had recurrence of symptoms and surgical intervention was done (lateral internal sphincterotomy) with no complication.

Follow-up after 2 weeks in group 2:

Pain score fell from 100 before the operation to 40 at the end of two weeks after operation. Absence of bleeding increased from 65% (16 patients) before operation to 97.5% (39 patients) after 2 weeks from operation. Thirty patients (with 10 chronic and 20 acute fissures) (75%) showed complete healing by inspection after 2 weeks of operation. Three patients (7.5%) complained of incontinence to flatus, two patients (5%) complained of mild soiling, one patient had a wound infection. No gross incontinence occurred.

Follow-up after 4 weeks in group 2:

Pain score fell to 20 after 4 weeks from the operation. Absence of bleeding became 97.5% (39 patients). Thirty-

eight patients (with 18 chronic and 20 acute fissures) (95%) showed complete healing by inspection after 4 weeks from operation. One patient had mild soiling. One patient had incontinence to flatus.

Follow-up after 6 weeks in group 2:

Pain score fell to 10 after 6 weeks from operation. Absence of bleeding became 97.5% (39 patients). Thirty-nine patients (with 19 chronic and 20 acute fissures) (97.5%) showed complete healing after 6 weeks from operation. There were no complications; only one patient had incontinence to flatus.

Follow-up after 8 weeks in group 2:

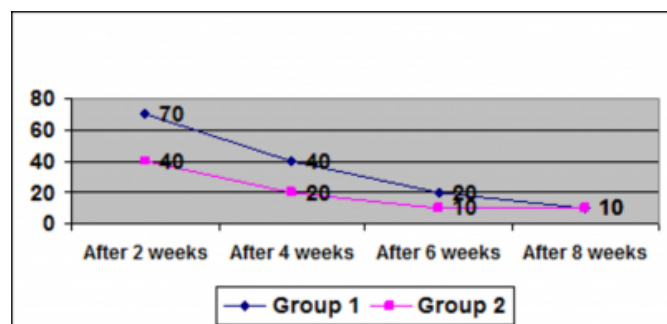
Pain score was around 10 after 8 weeks from operation. Thirty-nine patients (with 19 chronic and 20 acute fissures) (97.5%) showed complete healing. There were no complications and only one patient had incontinence to flatus.

Follow-up after one month and 3 months in group 2:

There were no relapses and no complications. Only one patient had incontinence to flatus.

Figure 1

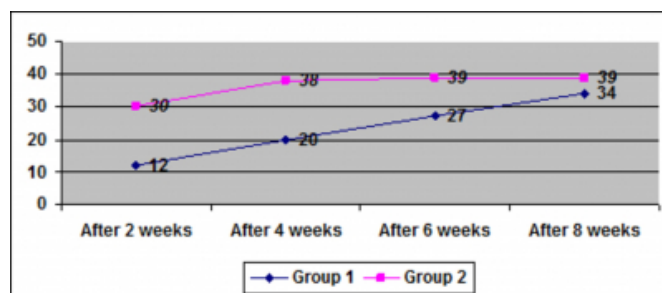
Figure 1: Pain score improvement - comparison between the two groups.



At the end of the 2nd week of treatment, pain score in group 1 fell to 70 as compared to the score in group 2 falling to 40 ($p = 0.0032$). This clearly indicates that lateral sphincterotomy relieves pain much earlier as compared to GTN. However, by the end of the 8th week of treatment, the pain score in both groups became 10. Hence, after 8 weeks of treatment, pain score with GTN is comparable to that after lateral sphincterotomy.

Figure 2

Figure 2: Healing of the fissure - improvement comparison between the two groups.



At the end of the 2nd week, only 12 patients in group 1 showed complete healing of fissure as compared to 30 patients in group 2 ($p = 0.0001$). However, at the end of the 8th week, healing with GTN was comparable to that with lateral sphincterotomy (34 patients with GTN versus 39 patients with sphincterotomy; $P = 0.239$).

DISCUSSION

Most patients with a chronic anal fissure have raised anal resting pressures caused by hypertonicity of the internal anal sphincter (IAS) and this seems to play an important role in pathogenesis of anal fissures. Local ischemia may also be important, as there is a relative hypoperfusion at the posterior commissure of the anal canal in most people.⁽⁷⁾

The aim of treatment is to reduce anal hypertonia, which may improve anodermal blood flow and heal the fissure. Until approximately 5 years ago, lateral internal sphincterotomy was the gold 'standard' in treatment, producing rapid symptom relief and healing rates of over 90%, but it is now less popular as disturbances in continence can occur in up to 30 % of patients.⁽⁸⁾

This has led to the search for alternative non-surgical treatments and various pharmacological agents have been shown to lower anal resting pressure and to heal fissures without threatening anal continence.⁽⁹⁾

Recognition of organic nitrates as the non-adrenergic, non-cholinergic neurotransmitters mediating relaxation of the internal anal sphincter has initiated the wide-spread use of organic nitrates in the treatment of chronic anal fissure. These agents are metabolized at a cellular level to release NO which, in turn, mediates relaxation of the internal anal sphincter by increasing cGMP levels within the smooth muscle cells. Preparations of GTN have been used with success and most studies report healing in the majority of cases.⁽¹⁰⁾

In our present study we found that 20 patients of the 20 patients with acute anal fissure (100%) had a benefit from using a pea-sized portion of 0.2% GTN cream on liposomal base applied to the distal part of the anal canal and the anal verge, and showed complete healing at the end of 8 weeks therapy versus 14 of 20 patients with chronic anal fissure (70%) receiving also topical GTN cream on liposomal base and becoming healed at the end of 8 weeks. Guillemot et al.⁽¹¹⁾ reported that topical GTN ointment rapidly reduced the resting pressure in the upper anal canal in normal subjects and patients with constipation.

Loder et al.⁽¹²⁾ applied GTN 0.2% ointment to the anoderm of 10 patients presenting for physiological assessment of a variety of anal disorders, including one patient with anal fissure. A significant decrease in MARP was observed by 20 min. after application of the ointment, which was sustained for at least 9 hours after the application of ointment. A recent randomized controlled trial showed that topical GTN brought about a dramatic drop in MARP in chronic anal fissure, and causes pain relief and healing, which was superior to xylocaine, proctosedyl or placebo.⁽¹³⁾

Lund and Scholefield⁽¹⁴⁾ reported that topical GTN has been shown to be an effective treatment for chronic anal fissure, healing even two thirds of patients after 8 weeks of treatment. Such a relatively high success rate with chronic fissure in our study may be attributed to the use of a liposomal base which increases penetration of GTN in the muscle and mucosa of IAS.

Pitt et al.⁽¹⁵⁾ have the same opinion like us and they added that the presence of a sentinel pile adversely affects the outcome of treatment of chronic anal fissures with GTN ointment, and fissures with a history of more than six months were unlikely to heal initially.

Marion et al.⁽¹⁶⁾ stated that topical 0.2 percent GTN ointment has a short-lived effect on anal resting pressure and application of topical 0.2% GTN twice daily heals two-thirds of fissures after eight weeks which is similar to our procedure but they added that the short duration of action of GTN may indicate that more frequent application might heal more fissures, more rapidly. Bacher et al.⁽¹⁷⁾ stated that topical application of nitroglycerin represents a new, easily handled, and effective alternative in the treatment of anal fissure. All of their patients reported a dramatic reduction in acute anal pain which is also consistent with our study in which the pain score fell from 100 pre-treatment to 70 after 2 weeks and then to 10 at the end of 8 weeks. Also

Gorfine⁽¹⁸⁾ reported that 30% of patients experienced headache when treated with topical 0.3% GTN ointment but that all were able to continue treatment.

On the other hand, Hyman and Cataldo⁽¹⁹⁾ treated anal fissure with topical 0.3% nitroglycerin ointment applied to the anoderm three times per day. They found that it was only effective in approximately one-half of patients with an anal fissure and more often caused headache (75%) than treated the symptoms of anal fissure. This study had a much higher incidence of adverse reactions than our study and we think that this is attributable to the higher concentration (0.3% GTN) than ours (0.2% GTN) and also to application to the anoderm three times per day compared to 2 times only in our study.

Despite the recent interest and the good results obtained with topical GTN in the non-surgical management of chronic anal fissure, there have been surprisingly few studies comparing it with the standard lateral sphincterotomy in the format of a randomized clinical trial.

Oettle⁽²⁰⁾ randomized 24 patients for treatment with sphincterotomy or local GTN; all 12 patients healed following sphincterotomy while 10 of 12 patients healed with local GTN ($P = 0.239$). Anal pressure recordings were not done or compared in that study. He concluded that local application of GTN could avoid surgery in more than 80% of patients with chronic anal fissure.

A multicenter trial involving 82 patients (38 patients in the sphincterotomy group and 44 patients in the GTN group) was conducted by Richard et al.⁽²¹⁾; this study concluded that internal sphincterotomy was superior to topical GTN in the treatment of chronic anal fissure because of a higher rate of healing, fewer side effects, and a low risk of early incontinence. Another study that randomized 60 patients into lateral sphincterotomy (27 patients) and GTN (33 patients) concluded that GTN heals the majority of chronic anal fissures. However, because a significant minority had little improvement or developed side effects and required conventional surgical treatment, GTN was not shown to be superior to lateral sphincterotomy.

A recent trial randomized 70 patients to GTN ointment or sphincterotomy, and resolution of symptoms and healing of fissures were assessed after 24 months. They concluded that many anal fissures heal with topical GTN; lateral sphincterotomy remains effective but should be reserved for patients who fail to respond to initial GTN.⁽²²⁾

The present study showed that in patients with fissure in ano a highly significant and comparable drop in MARP was brought about by both GTN and sphincterotomy.

Sphincterotomy relieves pain much earlier as compared to GTN, but after 4 weeks of treatment, pain relief in the two groups is comparable. Healing in the sphincterotomy group was also much earlier as compared to GTN. But this initial advantage was lost by 8 weeks of treatment. Lateral sphincterotomy has a significant incidence of minor short-term complications of bleeding, wound infection and incontinence, which are usually self-limiting. It also requires surgical expertise, theater time, and day care beds. GTN, on the other hand, is a safe and simple procedure with mild and tolerable side effects of headache and local burning sensation. Because it was a short-term study, no conclusions can be drawn about long-term recurrences with either treatment modality.

Because topical GTN is safe and well-tolerated, and because pain relief and healing are comparable with lateral sphincterotomy at the end of 6-8 weeks, we suggest that conservative treatment with GTN should be the initial treatment for chronic anal fissure. Lateral sphincterotomy should be reserved for patients with severe disabling pain (because pain relief is much faster), and for those patients not responding to at least 4 weeks of conservative therapy with GTN.

We also observed that the use of GTN as local application in patients with early symptomatic hemorrhoids is beneficial.

CONCLUSION

Topical application of GTN with liposomal base is a new, easily handled, low-cost and effective alternative treatment of anal fissures, effectively heals about 100% of acute anal fissures and 70% of chronic anal fissures, and can reduce the number of cases requiring sphincterotomy. Also, chemical sphincterotomy with GTN is reversible and therefore avoids permanent division of part of the sphincter and the consequent disturbance of the continence mechanism.

References

1. Leah S, Rick G (2000): Are non-surgical treatments for anal fissure effective? *Can Fam Phys* 46: 1063-1065.
2. Sailer M, Bussen D, Dubus E, et al. (1998): Quality of life in patients with benign anorectal disorder. *Br J Surg* 85: 1719-1726.
3. Rotholtz N, Bun M, Mauri M, et al. (2005): Long-term assessment of fecal incontinence after lateral internal sphincterotomy. *Tech Coloproctol* 9: 115-118.
4. Lund J, Scholefield J (1996): The etiology and treatment of anal fissure. *Br J Surg* 83: 1335-1344.
5. Mishra R, Thomas S, Maan M, et al. (2005): Topical nitroglycerin versus lateral internal sphincterotomy for chronic anal fissure. *ANZ J Surg* 75: 1032-1035.
6. Wilson A, Pitt B. (2002): Complex role of CpG in liposomal delivery of DNA oligonucleotides. *Biosci Reps* 22: 309-322.
7. Lund J, Scholefield J. (1997): A randomized prospective, double blinded, placebo controlled trial of glyceryl trinitrate ointment in the treatment of anal fissure. *Lancet* I: 340: 11-14.
8. Khubchandani I, Reed J (1989): Sequelae of internal sphincterotomy for chronic fissure in anus. *Br J Surg* 76: 431-434.
9. Jonas M, Scholefield J (2001): Anal fissure & chemical sphincterotomy. *Recent advances in surgery*. Eds I. Taylor and C. D. Jonsone. 24: 115-124.
10. Carapeti E, Kamm M, McDonald P, et al. (1999): Randomised controlled trial shows that glyceryl trinitrate heals anal fissures, higher doses are not more effective and there is a high recurrence rate. *Dis Colon Rectum* 42 (9): 727-730.
11. Guillemot F, Leroi H, Lone Y, et al. (1993): Action of in situ nitroglycerin on upper anal canal pressure of patients with terminal constipation. A pilot study. *Dis Colon Rectum* 36: 372-376.
12. Loder P, Kamm M, Nicholls R, et al. (1994): Reversible chemical sphincterotomy by local application of glyceryl trinitrate. *Br J Surg* 81: 1386-1394.
13. Maan M, Mishra R, Thomas S, et al. (2004): Randomized, double blind trial comparing topical nitroglycerine with xylocaine and Proctosedyl in idiopathic chronic anal fissure. *Indian J Gastroenterol*. 23: 91-93.
14. Lund J, Binch C, McGrath J, et al. (1999): Topographical distribution of blood supply to the anal canal. *Br J Surg* 86: 496-498.
15. Pitt J, Williams S, and Peter M (2001): Reasons for failure of glyceryl trinitrate in treatment of chronic anal fissure. *Dis Colon Rectum* 44: 764-867.
16. Marion J, Swan A, Jeff W, et al. (2001): Topical 0.2 % glyceryl trinitrate ointment has short-lived effect on resting anal pressure. *Dis Colon Rectum* 44: 1640-1643.
17. Bacher H, Mischinger H, El-Shabrawi A, et al. (1997): Local nitroglycerin for treatment of anal fissure: An alternative for lateral sphincterotomy. *Dis Colon Rectum* 440: 8405-8406.
18. Gorfine S (1995): Treatment of benign anal disease with topical nitroglycerin. *Dis Colon Rectum* 38: 453-457.
19. Hyman N and Cataldo P (1999): Nitroglycerin ointment for anal fissure. Effective treatment or just a headache? *Dis Colon Rectum* (Abstract) 42.
20. Oettle G (1997): Glyceryl trinitrate vs. sphincterotomy for treatment of chronic fissure in ano: A randomized, controlled trial. *Dis Colon Rectum* 40: 1318-20.
21. Richard C., Gregoire R, Plewes E, et al. (2002): Internal sphincterotomy is superior to topical nitroglycerin in the treatment of anal fissure; results of randomized, controlled trial by Canadian Colorectal Surgical Trials Group. *Dis Colon Rectum* 43: 1048-1058.
22. Libertiny G, Knight J, Farouk R (2002): Randomized trial of topical 0.2% glyceryl trinitrate and lateral internal sphincterotomy for the treatment of patients with chronic anal fissure: long-term follow-up. *Eur J Sug* 168: 418-421.

Author Information

Gouda M. El-Labban, M.D.

General Surgery Department, Faculty of Medicine, Suez Canal University-Egypt

Galal H. M. El-Gazzaz, M.D.

General Surgery Department, Faculty of Medicine, Suez Canal University-Egypt

Emad Hokamam, M.D.

General Surgery Department, Faculty of Medicine, Suez Canal University-Egypt