

Faecal Fistula, the Most Unfortunate Sequelae of Appendectomy. Case Report.

A Mohamed

Citation

A Mohamed. *Faecal Fistula, the Most Unfortunate Sequelae of Appendectomy. Case Report.* The Internet Journal of Surgery. 2010 Volume 27 Number 2.

Abstract

Faecal fistula is distressing for both the surgeon and the patient. We report a case of post-appendicectomy faecal fistula which was successfully treated conservatively.

INTRODUCTION

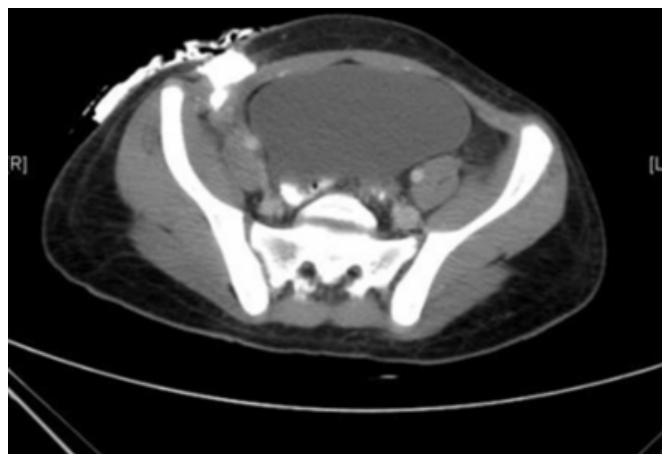Post-appendectomy faecal fistula formation, though a rare complication, is associated with significant morbidity. We present a 14-year-old boy who developed faecal fistula after appendicectomy which was reported as technically difficult.

CASE PRESENTATION

A 14-year-old boy was referred to the surgical department at King Fahad Medical City for further management of post-appendicectomy faecal fistula. He had appendicectomy at a periphery hospital two weeks before his referral. The appendicectomy was reported to be technically difficult as it was retrocaecal and subserosal. Attempts of freeing the appendix from the caecum resulted in caecal laceration which was primarily sutured. The patient did well in the early postoperative period and was discharged on the second postoperative day. He presented 2 days later with fever and signs of inflammation of the wound. On removal of some stitches, a large amount of feculent discharge was drained. A contrasted CT scan was requested which showed extravagation of contrast medium at the caecal region (figure 1).

Figure 1

Figure 1: Oral contrast CT scan showing extravasations of contrast dye at the level of the caecum.

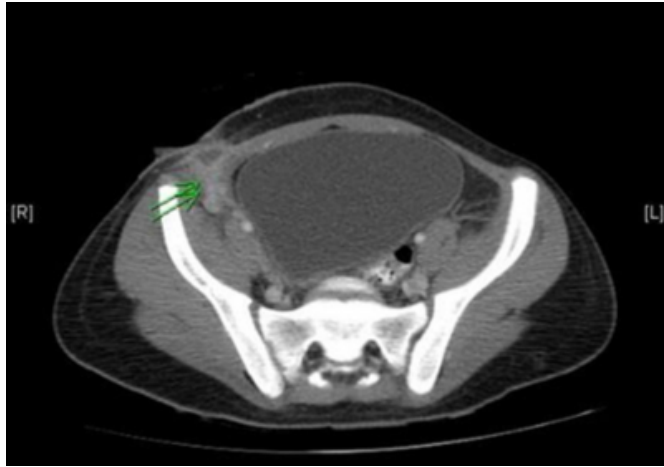


The patient was admitted and kept on intravenous fluids, intravenous antibiotics and regular dressings for 10 days before his transfer.

On admission to our hospital he looked well, not febrile, with normal vital signs. Leukocyte count and other laboratory investigations were within normal limits. The CT scan on admissions is shown below.

Figure 2

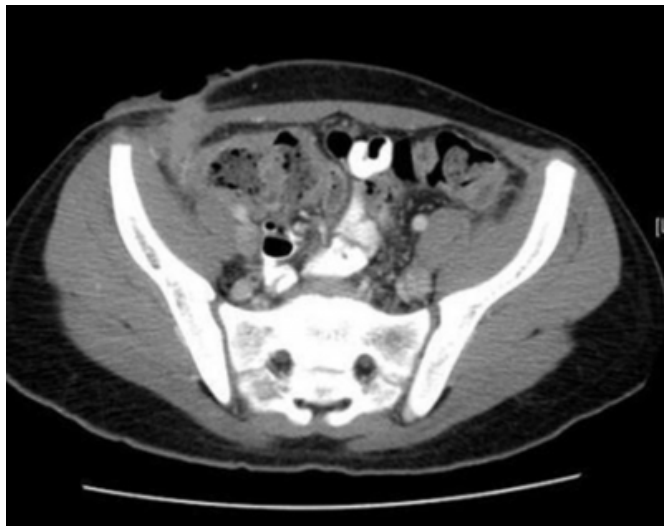Figure 2: CT scan two weeks later showing residual subcutaneous fluid collection.



We continued to treat him conservatively with parenteral nutrition, intravenous antibiotics and regular dressings of the wound. He responded well to the conservative treatment with complete closure of the fistula in 4 weeks (figure 3).

Figure 3

Figure 3: CT scan 6 weeks later showing complete closure of the fistula.



DISCUSSION

Faecal fistula is defined as an abnormal passage communicating with the intestines. Post-appendectomy faecal fistula formation, though a rare complication is associated with significant morbidity (1). It was given the first place among the unfortunate “sequelae” of appendectomy by Royster in his work on “Appendectomy” (2).

Post-appendectomy faecal fistulas occur mostly when there is severe peri-appendicitis involving the base of the appendix as well as the adjoining caecal wall. Leakage from the appendiceal stump is incriminated as a major etiological factor in such patients (3). Injuries to the caecum during appendectomy, although is not frequently reported, are another important etiological factor.

Genier et al. reviewed 22 cases of post-appendectomy faecal fistulas, treated during a 24-year period (January 1970 to December 1993). They found that in 21 cases, appendicitis was severe (suppurative, gangrenous or perforated) or appendectomy quoted as technically difficult (4).

Other known etiological factors include neoplasia of appendix and caecum, infective bowel conditions, especially intestinal tuberculosis, actinomycosis and Crohn's disease, distal obstruction and foreign body (5).

The relation of post-appendectomy complications (including faecal fistula) to surgical technique, namely use of purse-string suture versus simple ligation of the stump is not well established.

Some other authors believe that the use of the purse-string suture is a main contributory factor in development of faecal fistula. Fairchild (6) extensively reviewed the issue being attracted to the dangers of the purse-string suture by the large percentage of faecal fistulas reported by surgeons who used it in comparison to his own patients who were operated without using a purse-string suture. He concluded that the chief objections to the purse-string treatment include many factors that may predispose to development of faecal fistulas. These factors include: purse-string suture necessitates more mobilization of the caecum; there is a great danger of the needle penetrating the bowel with resulting peritonitis; a distinct danger of a haematoma from pricking a vessel; a danger of necrosis of the encircled wall of the caecum from diminished blood supply and an increase of postoperative adhesions, with resulting post-operative ileus.

Although many recent studies showed no significant difference between the two methods of treatment of the appendix stump (5, 7, 8), most surgeons continue to carry out purse-string sutures in daily practices of open appendectomy as long as the stump situation permits (9, 10, 11).

At early stage, a faecal fistula may be confused with wound infection. Faecal fistula usually presents with persistent

feculent discharge from the wound which continues inspite of attempts of drainage and repeated dressing. The patient generally looks unwell during the early postoperative period and may have slow recovery. Associated symptoms include fever, nausea and vomiting and symptoms and signs of paralytic ileus. Diagnosis is usually established on CT scan which shows extravagation of the oral contrast medium at the caecum. Fistulography is helpful in the late stages when the fistulous tract is well matured.

Although faecal fistula is very distressing for both the surgeon and the patient, the occurrence of the fistula has the advantage of preventing the extension of the infection in other directions.

Bailey, of London, in writing on fecal fistulas quotes approvingly an aphorism of a former colleague of his: "If a patient with peritonitis develops a fecal fistula, he does not die"; his explanation being, of course, that a fecal fistula acts as an enterostomy (4, 12).

Procedures like caecostomy or even right hemicolectomy have been advised when there is severe inflammation and abscess formation to avoid the serious complication of fistula formation. Use of tube caecostomy seems to be quite reasonable in preventing post-appendectomy abscess and faecal fistula formation in patients with severe peri-appendicitis involving the base of the appendix as well as the adjoining caecal wall, and in cases of severe iatrogenic caecal lacerations as it associated with the least morbidity (1).

Most faecal fistulae respond to conservative treatment in absence of underlying pathology and distal obstruction. Non-surgical management options for faecal fistula include vacuum-assisted closure (13) and fistuloscopy with fibrin glue injection (14).

Surgical management should be considered after 4-6 weeks of sepsis-free adequate nutritional support. Fistula tract excision and segmental resection of involved bowel, with end-to-end anastomosis is recommended (15).

SUMMARY

Post-appendectomy fecal fistula formation, though a rare complication, is associated with significant morbidity. Early diagnosis is essential to institute proper treatment at an early stage of the disease. Most faecal fistulae respond to conservative treatment in absence of underlying pathology and distal obstruction. Surgical management should be reserved for those who failed to respond to conservative management.

References

1. Ali N, Javaid A: Role of tube cecostomy in preventing post appendectomy abscess and fistula formation. *Pak J Med Sci*; 2005; 21: 285-8.
2. Royster HA: Appendicitis. D. Appleton & Co., New York; 1927; p. 346.
3. Finlay DJ, Doherty GM: Acute abdominal pain and appendicitis. In: *Washington Manual of Surgery*. Washington University School of Medicine. Lippincott Williams & Wilkins; 2002; 265.
4. Genier F, Plattner V, Letessier E, Armstrong O, Heloury Y, Le Neel JC: [Post-appendectomy fistulas of the cecum. Apropos of 22 cases]. *J Chir (Paris)*; 1995; 132(10): 393-8.
5. Watters DA, Walker MA, Abernethy BC: The appendix stump: should it be invaginated? *Ann R Coll Surg Engl*; 1984; 66(2): 92-3.
6. Baldwin JF: The prevention of faecal fistula after appendectomy. Simple ligation vs. precarious purse-string. *Ann Surg*; 1932; 95(5): 704-714.
7. Lavonius MI, Liesjärvi S, Niskanen RO, Ristkari SK, Korkala O, Mokka RE: Simple ligation vs stump inversion in appendectomy. *Ann Chir Gynaecol*; 1996; 85(3): 222-4.
8. Street D, Bodai BI, Owens LJ, Moore DB, Walton CB, Holcroft JW: Simple ligation vs stump inversion in appendectomy. *Arch Surg*; 1988; 123(6): 689-90.
9. Shahid N, Ibrahim K: Appendectomy: non-invagination vs. invagination of appendicular stump. *Prof Med J*; 2004; 11: 117-20.
10. Chaudry IA, Samiullah, Mallhi AA, et al.: Is it necessary to invaginate the stump after appendectomy. *Pak J Med Sci*; 2005; 21: 35-8.
11. Morrow SE, Newman KD: Current management of appendicitis. *Semin Pediatr Surg*; 2007; 16: 34-40.
12. Bailey, Hamilton: *Emergency Surgery*, Vol. I, pp. 40, 44, and 274.
13. Cro C, George KJ, Donnelly J, Irwin ST, Gardiner KR. Vacuum assisted closure system in the management of enterocutaneous fistulae. *Postgrad Med J*; 2002; 78: 364-5.
14. Eleftheriadis E, Kotzampassi K: Therapeutic fistuloscopy: an alternative approach in the management of postoperative fistulas. *Dig Surg*; 2002; 19: 230-6.
15. Deaver JB: Appendiceal fecal fistula. *Ann Surg*; 1924; 80(1): 56-7.

Author Information

Abbas Mohamed, MBBS, FRCSI, FICS

Consultant General and Laparoscopic Surgeon, Department of Surgical Specialties, King Fahad Medical City