

Unusual Maxillary First Molar with two palatal roots: A case report

P Ravishanker, K Prashanthi

Citation

P Ravishanker, K Prashanthi. *Unusual Maxillary First Molar with two palatal roots: A case report*. The Internet Journal of Dental Science. 2008 Volume 7 Number 1.

Abstract

A case report is presented regarding a maxillary first molar with 4 roots. The morphology is atypical because it is characterized by 2 divergent palatal roots. A literature review pertaining to the morphology of maxillary first molars is discussed. The importance of straight line access and the need for examination of the pulpal floor for additional canals are stressed.

INTRODUCTION

The unusual occurrence of 4 rooted maxillary first molars with 2 separate palatal roots which have been endodontically treated has been sparsely reported in the literature.

The morphology and configuration of the maxillary first molars have been discussed for more than half a century ¹²³⁴⁵⁶⁷⁸⁹¹⁰¹¹¹². Differences between studies may be attributed to variations in the technique used to study the morphology.

- 1925: In a study of 513 maxillary molars, Hess ¹ found that 53% had 4 canals.
- 1927: Okumara ² found that 53% of 299 extracted teeth had 2 canals in the mesiobuccal (MB) root, 2.9% had 2 in the distobuccal (DB) root, and 0.3% had 2 in the palatal root.
- 1969: Weine and others ³ studied 208 extracted first molars, and found that 51.5% had 2 canals in the MB root.
- 1972: Pineda and Kuttler ⁴ found that, in 262 maxillary first molars, 60.7% had 2 canals in the MB root, 3.6% had 2 in the DB root and 100% had one canal in the palatal root.
- 1973: Seidberg and others ⁵ found that 62% of 100 extracted first maxillary molars studied in vitro had 2 canals in the MB root, but only 33% of 201 maxillary molars treated with endodontic therapy and studied in vivo showed 2 canals.
- 1974: Slowey ⁶ reported that of 103 endodontically treated molars 50.4% had 2 MB canals and 49.6% had only one.
- 1974: In a study of 100 decalcified maxillary first molars,

Vertucci ⁷ found that a fourth canal occurred in 55%.

- 1974: Pomeranz and Fishelberg ⁸ examined 100 extracted maxillary first molars and found 69% had 4 canals, with 2 located in the MB root.
- 1978: Acosta Vigouroux and Trugeda Bosaans ⁹ showed that 72% of the 134 maxillary first molars studied had more than 3 root canals.
- 1983: Gray ¹⁰ found a fourth canal in 56% of teeth examined.
- 1993: Thomas and others ¹¹ found that 74% of MB roots showed a double canal system and over 95% of palatal and DB roots contained a single canal.
- 1994: Fogel and others ¹² reported a double canal system in the maxillary first molar of 72% of teeth.

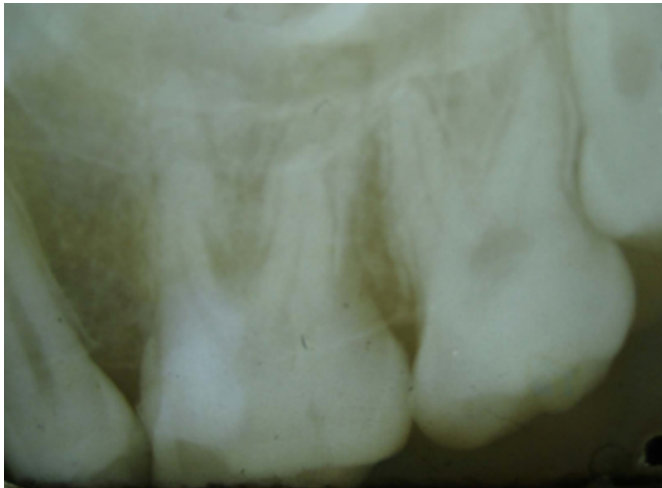
What is not generally understood, however, is that there may be more than 3 roots. Thews et al described a case involving the endodontic treatment of a maxillary first molar with 2 widely divergent palatal roots. Christie et al (1991) analysed endodontic treatment in 16 maxillary molars and of 6 extracted teeth with 2 palatal roots and classified these 22 molars into three types (I-III) according to root separation level and their divergences. According to the same classification, Di Fiore (1999) classified as type II- a case of maxillary first molar with 4 independent roots.

CASE REPORT

A 25-year-old female patient reported to "Radiant Smile Dental Clinic" in suburban Chennai, India presenting with

signs of acute irreversible pulpitis. She complained of pain, both spontaneous and temperature related, on the left side of the face for four days prior to her appointment. The patient's medical history was noncontributory. After extensive clinical and radiographic examination, the maxillary left first molar was prepared for nonsurgical endodontic therapy. A preoperative radiograph was obtained

Figure 1

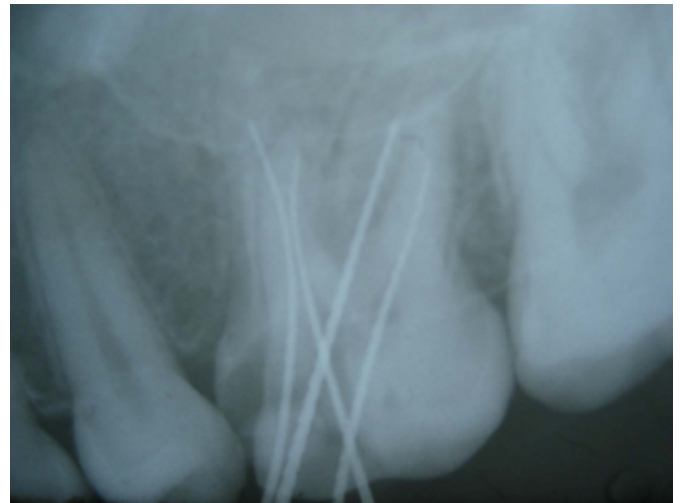

The patient received local anesthesia of 2% lidocaine with 1:100,000 epinephrine. Isolation was done with high vacuum suction and cotton rolls and a conventional endodontic access opening was made.

In the pulp chamber floor, the 3 principal root canal systems were identified: MB, DB, and palatal. H-type files were used for gross removal of pulp tissue in the 3 main canals. A small hemorrhagic point was noted 3mm distal to the orifice of the main palatal canal. The pulp chamber floor was then explored to find the fourth root i.e. the distopalatal root. A small amount of dentin that was occluding the orifice of the second palatal root was removed. The conventional triangular access was modified to a trapezoidal shape to improve access to the additional distopalatal root.

Examination of the chamber floor with the explorer revealed 4 canal orifices. There were 2 palatal orifices, fairly well separated, exiting from the floor of the pulp chamber and MB and DB orifices. The coronal portion of the canals were prepared using Protaper system (Shaper X file) to improve straight line access. Frequent irrigation with 5.25% sodium hypochlorite was also carried out. A working length radiograph was taken (Fig.2), length adjusted.

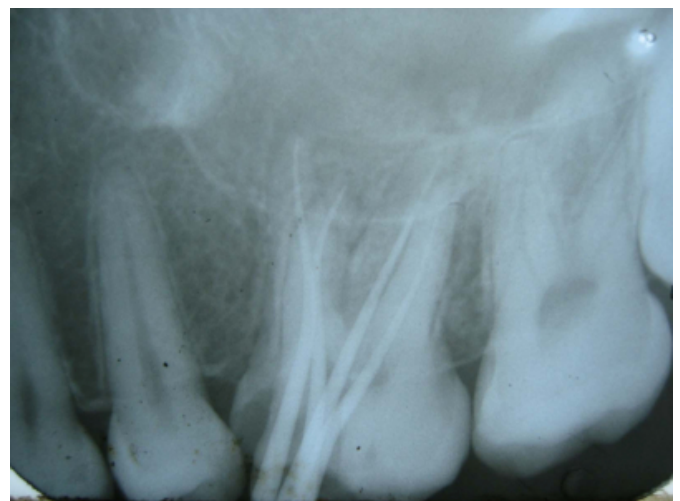Figure 2



It was clearly evident in this radiograph, the 4 roots of the maxillary first molar, with the 2 palatal roots diverging. The apical preparation was done using K-type files. Cleaning and shaping was completed using Protaper files S1 and F1.

The tooth was dried with paper points, and a cotton pellet was sealed into the pulp chamber with a temporary restorative filling material. At the next appointment, the root canals were irrigated with normal saline and dried with paper points. The canals were obturated using zinc oxide-eugenol sealer and Protaper gutta percha. The immediate post-obturation radiograph (Fig.3) shows the unique root morphology.

Figure 3



The tooth has been asymptomatic thereafter.

This case report emphasizes the importance of looking for additional roots and canals and of ensuring adequate access to improve the likelihood that additional canals will be

located. The conservation of tooth structure must be kept in mind when establishing an endodontic access to allow for successful restoration of the tooth after root canal therapy. Endodontic access should be designed to provide direct access to the apical third of the root canal system, not merely to locate the canal orifice. The dentist should be able to visualize all aspects of the coronal third of the root canal system, and all tooth structure or restorative material that interferes with straight-line access should be removed. It is important for the access cavity to have smooth externally diverging walls to improve visibility and prevent debris from migrating into the canal system.

CONCLUSION

This case report contributes to our understanding of the complexity of the morphology found in maxillary first molars. Although such cases occur infrequently, dentists should be aware of them when considering endodontic treatment of a maxillary first molar.

References

1. Hess W. The anatomy of the root canals of the teeth of the permanent dentition. London: John Bale Sons and Danielsen, 1925.
2. Okumara T. Anatomy of the root canals. *J Am Dent Assoc* 1927; 632-6.
3. Weine FS, Healey HJ, Gerstein H, Evanson L. Canal configuration in the mesiobuccal root of the maxillary first molar and its endodontic significance. *Oral Surg Oral Med Oral Pathol* 1969; 28(3):419-25
4. Pineda F, Kuttler Y. Mesiodistal and buccolingual roentgenographic investigation of 7,275 root canals. *Oral Surg Oral Med Oral Pathol* 1972; 33(1):101-10.
5. Seidberg BH, Altman M, Guttuso J, Suson M. Frequency of two mesiobuccal root canals in maxillary permanent first molars. *J Am Dent Assoc* 1973; 87(4):852-6.
6. Slowley RR. Radiographic aids in the detection of extra root canals. *Oral Surg Oral Med Oral Pathol* 1974; 37(5):762-72.
7. Vertucci FJ. The endodontic significance of the mesiobuccal root of the maxillary first molar. *US Navy Med* 1974; 63(5):29-31.
8. Pomeranz HH, Fishelberg G. The second mesiobuccal canal of maxillary molars. *J Am Dent Assoc* 1974; 88(1):119-24.
9. Acosta Vigouroux SA, Trugeda Bosaans SA. Anatomy of the pulp chamber floor of the permanent maxillary first molars. *J Endod* 1978; 4(7):214-9.
10. Gray R. The maxillary first molar. In: Bjorndal A, Skidmore E, editors. *Anatomy and morphology of the human teeth*. Iowa City: University of Iowa College of Dentistry; 1983. p. 31-40.
11. Thomas RP, Moule AJ, Bryant R. Root canal morphology of maxillary permanent first molar teeth at various ages. *Int J Endod* 1993; 26(5):257-67.
12. Fogel HM, Peikoff MD, Christie WH. Canal configuration in the mesiobuccal root of the maxillary first molar: a clinical study. *J Endod* 1994; 20(3):135-7.

Author Information

P. Ravishanker, M.D.S. (Conservative dentistry & Endodontics)

Senior Lecturer, Department of Conservative dentistry & Endodontics, College of Dental surgery, Saveetha University

K. Prashanthi, B.D.S.

Radiant Smile Dental Clinic