

Ovarian Mass In Pregnancy: A Review Of Six Cases Treated With Surgery

K Shah, S Anjurani, V Ramkumar, P Bhat, M Urala

Citation

K Shah, S Anjurani, V Ramkumar, P Bhat, M Urala. *Ovarian Mass In Pregnancy: A Review Of Six Cases Treated With Surgery*. The Internet Journal of Gynecology and Obstetrics. 2009 Volume 14 Number 2.

Abstract

Ovarian masses greater than 5 cm are rare during pregnancy. We report six pregnant women with an ovarian mass more than 5 cm and operated during pregnancy or at the time of cesarean delivery. Elective surgery in second trimester of pregnancy is safe. Emergency surgery is required for complication such as torsion or hemorrhage. Complication of emergency antenatal surgery can be reduced by proper care. Malignant ovarian mass is uncommon during pregnancy. Ultrasound morphology is quite accurate to decide characteristic of mass and further management. Careful selection of ovarian mass is important for expectant management till term.

INTRODUCTION

With the advent of routine prenatal ultrasound, the detection of ovarian mass has become common. The presence of ovarian masses in pregnancy is not unusual with prevalence between 1-2%¹ and incidence of malignancy being 1-3%.^{2,3} In the era before routine prenatal ultrasound, ovarian masses were discovered either incidentally on physical examination or as a result of symptoms. In either case, detection would tend to favor masses that were problematic as a result of either size or complications. The majority of ovarian masses detected in first trimester of pregnancy disappear by early second trimester. After 16 weeks, histopathology is identical to non-pregnant women of same age group i.e. germ cell, epithelial and sex cord stromal tumors. Other than malignancy, serious complications of these tumors are torsion, intracystic hemorrhage and rupture, which require surgical intervention.

Understanding of the benign nature and uncomplicated course of ovarian masses diagnosed incidentally by ultrasound has led to a more conservative but careful and vigilant approach to management of ovarian masses in pregnancy. Emergent surgical intervention is associated with increased risk of adverse outcome for both mother and fetus. Optimal management lies in weighing the risk of expectant management versus intervention in individual cases.

The aim of this study was to review ovarian masses in pregnancy that were operated with traditional approach of laparotomy during pregnancy or caesarean delivery.

MATERIAL AND METHODS

Six ovarian masses with pregnancy operated in our institution between June 2008 and June 2010 were included. Persistent mass of more than 5 cm in any trimester of pregnancy who underwent surgery due to complication or with cesarean delivery were included. Large ovarian mass is defined here as mass measuring more than 10 cm (with or without septa, nodule or papillary excrescences). Data of six pregnancies with ovarian mass and neonatal outcome are mentioned in Table 1.

Figure 1

Table 1. Data of six pregnancies with ovarian mass and neonatal outcome

	Case 1	Case 2	Case 3	Case 4	Case 5	Case 6
Age (years)	31	26	24	28	29	25
Parity	1	1	2	1	0	0
Gestational age at presentation (week)	7	8	30	37	6	24
Period /Gestational age at surgery (week)	7	15	30	Postpartum	38	37
Size of mass at surgery (cm)	8x10	8x7	7x6.5	12x11	6x6	6x7, 4x5
Surgery	Salpingo-oophorectomy	Oophorectomy	Salpingo-oophorectomy	Salpingo-oophorectomy	Cystectomy	Cystectomy
Pathology	Simple ovarian cyst with cystic corpus luteum	Mature cystic teratoma	Hemorrhagic ovarian cyst	Mature cystic teratoma	Serous cystadenoma in parovarian cyst	Mucinous cyst adenofibroma
Pregnancy complication	No	No	No	No	No	No
Gestational age at delivery (week)	39	38	37	37	38	37
Birth weight (kg)	3.1	2.8	2.8	2.6	3.4	2.9

Case 1: A 31-year, second gravida presented with 7 weeks of pregnancy and severe abdominal pain on right side associated with nausea and vomiting since 4 hours. She was afebrile. Scan showed an enlarged right ovary of 5.2x4.5 cm containing a 3.7x3.4 cm corpus luteal cyst. Doppler

velocimetry was normal. After 6 hours of observation with analgesic and antibiotics, the patient was taken up for emergency laparotomy in view of ovarian torsion. Right ovarian cyst of 8x10 cm with 3 twists of pedicle and gangrenous and hemorrhagic areas on ovarian cyst were observed (figure 1). Histopathology showed simple ovarian cyst with cystic corpus luteum. Progesterone was administered till 16 weeks of gestation. Rest of antenatal period was uneventful. She had a normal vaginal delivery at 39 weeks and the newborn was healthy.

Case 2: A 26-year, second gravida presented with abdominal pain at 15 weeks of gestation. Transvaginal ultrasound at 7 weeks showed complex left ovarian mass measuring 5.7x5.1 cm, with 3x1.5 cm hyperechoic area; without any septa and with regular border and low level echoes. Vaginal examination detected an ovarian mass with pregnant uterus. The ovarian mass was unchanged from previous scan to admission scan. Planned laparotomy was done after 1 day of observation with antibiotics, analgesics and progesterone supplementation. Tumor markers were not done as scan suggested benign mass. At laparotomy, left ovary was 8x7 cm, with incomplete torsion (figure 2). Detorsion and left oophorectomy was done. Histopathology showed mature cystic teratoma with congestion. Progesterone supplementation was continued for 4 weeks following surgery. Postoperative period and rest of antenatal period was uneventful. Patient had a normal vaginal delivery at 38 weeks, the newborn was healthy and postpartum sterilization performed.

Case 3: A 24-year, third gravida presented at 30 weeks of gestation with acute abdominal pain. She had right sided abdominal pain and vomiting since 1 day. On examination mild tenderness in right side of abdomen was elicited. Ultrasound suggested well defined ovarian cyst of 5x5.5 cm with minimal echogenicity. Patient was kept under observation with antibiotics and analgesics. Steroids and progesterone supplementation were given. Emergency laparotomy was done in view of suspected acute appendicitis or ovarian torsion. Laparotomy showed normal appendix and hemorrhagic ovarian cyst measuring 7x6.5 cm with bluish discoloration. Right salpingo oophorectomy and left side tubal ligation was done according to the patient's wishes. Histopathology showed hemorrhagic ovarian cyst. She delivered a healthy baby at term.

Case 4: A 28-year, second gravida presented at 37 weeks of gestation with back pain and mild right upper abdominal pain. Patient had an ultrasound report which showed a right

ovarian cyst of 12x11 cm. Abdominal palpation showed full term uterus and cystic, non tender mass of 10 cm in the right hypochondrium. Ultrasound suggested complex ovarian mass of 11x12 cm, with low levels of echogenicity and solid area of 2x1.4 cm with probable diagnosis of dermoid cyst (figure 3). She had a spontaneous vaginal delivery after 1 day of observation and the newborn was healthy. Laparotomy was done on second postpartum day for large ovarian mass (figure 4). Right salpingo oophorectomy with left tubal ligation was performed. Histopathology showed mature cystic teratoma.

Case 5: A 29-year, primigravida presented at 38 weeks with severe upper abdominal pain. Admission ultrasound showed unilocular, thin walled ovarian cyst measuring 5x6.5 cm without septation or internal echoes. Emergency cesarean was done. A healthy baby was delivered and concurrent cystectomy performed for twisted right parovarian cyst measuring 6x6.5 cm. Histopathology suggested serous cystadenoma.

Case 6: A 25-year primigravida presented at 37 weeks with breech presentation. She was diagnosed to have bilateral ovarian cyst (6x6 cm in right; 4x4 cm in left) without septa or internal echoes at 24 weeks of gestation. She was followed up conservatively till term. She underwent planned cesarean for breech presentation. Bilateral ovarian cyst measuring 6x7 cm on right side and 4x5 cm on left side were noted. Bilateral ovarian cystectomy was done. Histopathology showed bilateral mucinous cystadenofibroma.

Figure 2

Figure 1. First trimester pregnancy with ovarian mass in case 1

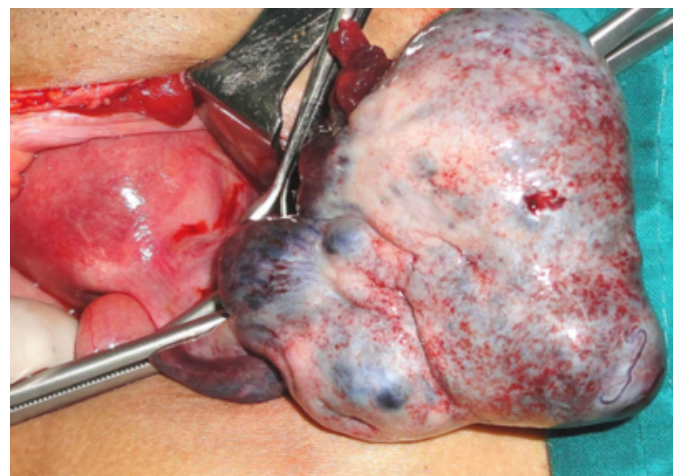

Figure 3

Figure 2. Second trimester pregnancy with ovarian mass in case 2.

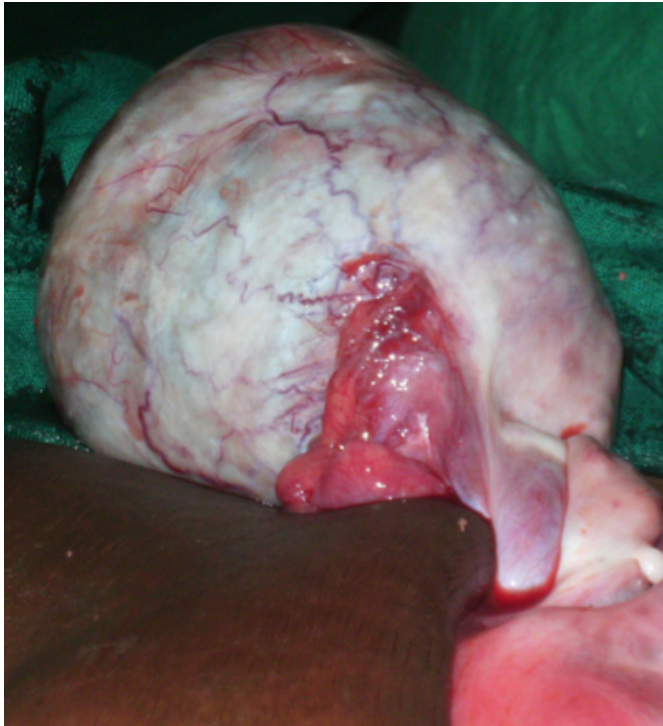

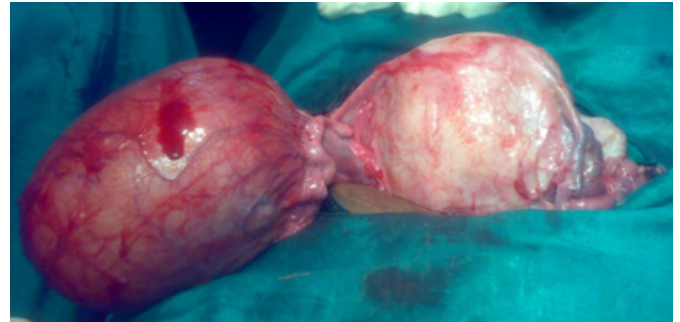
Figure 4

Figure 3. Ultrasound suggestive of dermoid cyst in case 4

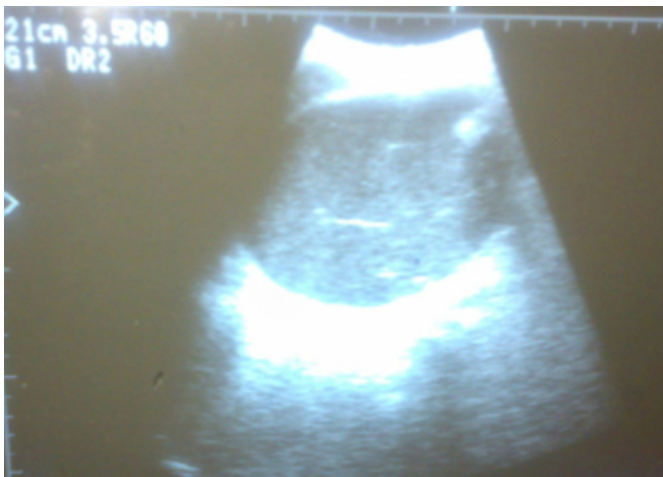

Figure 5

Figure 4. Large ovarian mass with postpartum uterus in case 4



DISCUSSION

There were five ovarian and one parovarian cyst in our series. Mature cystic teratoma was the histopathological finding of large ovarian mass of one case in our series; other ovarian masses were two cases of simple ovarian cyst (one with haemorrhage), one mature cystic teratoma, one mucinous cystadenofibroma and one serous cystadenoma in parovarian cyst. After functional cysts, most common ovarian tumors diagnosed in pregnancy are benign cystic teratoma, serous cystadenoma, parovarian cyst, mucinous cystadenoma and endometrioma in descending order.⁴

Whenever malignancy is present, they are typically germ cell tumors or borderline epithelial ovarian tumors that are commonly low stage and low grade, consequently prognosis of these women is also highly favorable.^{2,5}

Incidence of ovarian surgery required in pregnancy is about 1:1312 pregnancies.⁴ Most frequent complication of ovarian mass in pregnancy is torsion⁶ and in our series 2 patients presented with ovarian and parovarian cyst complete torsion, one in first trimester and one in late third trimester. Here we have not taken into account the entity of partial torsion. Torsion of ovary is a dreaded complication leading to infarction, infection, sepsis, peritonitis and adhesions when treatment is delayed. Ovarian masses of 6-8 cm are associated with significantly higher risk of torsion³. Sixty percent of ovarian torsion occurs between 10-17 weeks of gestation and emergency intervention is needed for all cases of torsion to relieve symptoms. Intracystic hemorrhage is a less frequent complication, which was observed in case 3 in early third trimester. Hemorrhagic functional ovarian cyst is often a cause of acute abdomen which requires intervention in majority of cases. In case 4, salpingo oophorectomy and tubal ligation was performed postpartum, due to large size of ovarian mass. Two cesareans with concurrent cystectomies were performed for torsion of parovarian cyst in case 5, and

in case 6 for persistent bilateral ovarian mass. Parovarian cyst generally originates from mesothelium of broad ligament but may arise from paramesonephric and mesonephric remnants. Parovarian cyst is generally unilocular and rarely undergoes papillomatous changes, however it can undergo torsion. Mucinous cystadenofibroma is a relatively rare benign tumor in pregnancy. In our case, it was bilateral and cystectomy was carried out on either side to preserve fertility.

Abortion is a common complication of abdominal surgery in first trimester, and in second trimester intrauterine growth restriction and preterm labor can occur. Laparotomy in our series was not associated with any obstetric complication. Although second trimester surgery is safe and ideal, it has increased risk of adverse pregnancy outcome hence, surgical management needs to be reconsidered.⁷

Ultrasound is quite accurate for detection and assessment of risk of malignancy. Morphological criteria are more accurate for identification of benign cyst than malignant mass. Ultrasound should be the first imaging modality of investigation for ovarian mass in pregnant or non-pregnant women.⁸ MRI can be safely used in pregnancy to evaluate tissue composition and to differentiate ovarian mass from other abdominal mass.⁹ Ultrasound for ovarian mass evaluation is technically difficult in third trimester hence MRI is especially useful for third trimester imaging. In our series, ultrasound could diagnose ovarian cyst even in third trimester. The clinical significance of CA 125 tumor marker in epithelial ovarian tumor in pregnancy is less, because it is elevated in the first trimester of pregnancy and declines with advancing gestational age.¹⁰ CA 19-9 is expressed by mucinous tumor, which is not changed by pregnancy, hence it is reliable.¹¹ Germ cell tumors are proportionately more common in pregnant women. Of the germ cell tumor markers, lactate dehydrogenase is not altered by pregnancy, but human chorionic gonadotropin and alpha fetoprotein levels are not reliable during pregnancy⁵. In all our cases, ultrasonography was suggestive of benign mass, hence tumor markers were not done. Color Doppler velocimetry is not routinely performed in ovarian mass and only one patient with first trimester torsion underwent Doppler, which was normal.

The specter of a possible malignancy or complication can sway the decision for intervention versus expectant management. Expectant management is recommended for most pregnant patients with asymptomatic, non-suspicious

cystic ovarian masses. Surgical intervention during pregnancy is indicated for large and/or symptomatic tumors and those that appear highly suspicious for malignancy on imaging.¹² Simple cystic masses that are < 6 cm do not require laparotomy during pregnancy as the risk of malignancy is below 1% and if ovarian mass persists into the second trimester and it is > 8 cm, rapidly growing or complex mass suspicious of malignancy, surgery should be performed.¹³ In our case series, we did an emergency laparotomy for torsion of ovarian cyst in first trimester, where high index of suspicion is necessary. In second trimester, planned laparotomy was done for ovarian mass. In early third trimester, emergency laparotomy was done for hemorrhagic ovarian cyst. There is an increasing body of evidence for the use of laparoscopy in the management of ovarian masses as an alternative to open laparotomy during pregnancy. A laparotomy could have been avoided in case 1 and case 5; if a laparoscopic approach was considered which is safe and effective when performed by an experienced team with less maternal and fetal morbidity.¹⁴ Two cesarean laparotomies were performed for bilateral ovarian mass and torsion of parovarian cyst in the other case. One postpartum laparotomy for large ovarian mass was performed. The extent of surgery depends on the intraoperative diagnosis of a benign versus malignant tumor. Conservative surgery is appropriate in the form of cystectomy, oophorectomy or salpingo oophorectomy for benign masses and borderline ovarian tumors. More aggressive surgery is indicated for ovarian malignancies, including surgical staging.¹²

CONCLUSION

Ovarian masses are frequently diagnosed during pregnancy. The majority of these are functional or physiological ovarian cysts, which resolve spontaneously by the second trimester. Even among persistent masses, malignancy is rare and restricted criteria for ultrasound and tumor markers for diagnosis of malignancy should be kept in mind. Ideal time for scheduled surgery is beginning of second trimester. Carefully selected masses can be followed until term and surgery can be performed during cesarean delivery if they are still present. Given the risk of torsion, rupture, or obstruction, immediate surgery is to be performed irrespective of gestational age, with due risk of abortion or provoked prematurity and fetal morbidity. Cesarean delivery is warranted if cyst is in the pelvis and likely to obstruct labor.

References

1. Zanetta G, Mariani E, Lissoni A, Ceruti P, Trio D,

- Strobelt N, Mariani S. A prospective study of the role of ultrasound in the management of adnexal masses in pregnancy. *BJOG* 2003; 110:578-583.
2. Leiserowitz GS, Xing G, Cress R, Brahmabhatt B, Kalrymple JL, Smith LH. Adnexal masses in pregnancy: how often are they malignant? *Gynecol Oncol* 2006; 101(2):315-321.
3. Yen CF, Lin SL, Murk W, Wang CJ, Lee CL, Soong YK, Arici A. Risk analysis of torsion and malignancy for adnexal masses during pregnancy. *Fertil Steril* 2009; 91(5):1895-1902.
4. Whitecar MP, Turner S, Higby MK. Adnexal masses in pregnancy: A review of 130 cases undergoing surgical management. *Am J Obstet Gynecol* 1999; 181:19-24.
5. Bignardi T, Condous G. The management of ovarian pathology in pregnancy. *Best Pract Res Clin Obstet Gynecol* 2009; 23:539-548.
6. Kumari I, Kaur S, Mohan H, Huria A. Adnexal masses in pregnancy: a 5-year review. *Aust N Z J Obstet Gynaecol* 2006; 46(1):52-54.
7. Platek DN, Henderson CE, Goldberg GL. The management of a persistent adnexal mass in pregnancy. *Am J Obstet Gynecol* 1995; 173(4):1236-1240.
8. Valentin L. Use of morphology to characterize and manage common adnexal masses. *Best Pract Res Clin Obstet Gynaecol* 2004; 18(1):71-89.
9. Sherer DM, Maitland CY, Levine NF, Eisenberg C, AbulaWa O. Prenatal magnetic resonance imaging assisting in differentiating between large degenerating intramural leiomyoma and complex adnexal mass during pregnancy. *J Matern Fetal Med* 2000; 9(3):186-189.
10. Condous G, Kirk E, Syed A, Van Calster B, Van Huffel S, Timmerman D, Bourne T. Do levels of serum cancer antigen 125 and creatine kinase predict the outcome in pregnancies of unknown location? *Hum Reprod* 2005; 20(12):3348-3354.
11. Reynolds K, Menon U, Jacobs I. Development and identification of tumor markers. In: Hoskins WJ, Perez CA, Young RC (editor). *Principles of gynecologic oncology*, Lippincott Williams & Wilkins, Philadelphia, 2005; 1279-1311.
12. Leiserowitz GS. Managing Ovarian Masses During Pregnancy. *Obstet Gyn Survey* 2006; 61(7):463-470.
13. Swensen RE, Goff BA, Koh W-J. Cancer in the pregnant patient. In: Hoskins WJ, Perez CA, Young RC (editor). *Principles of gynecologic oncology*, Lippincott Williams & Wilkins, Philadelphia, 2005; 1279-1311.
14. Mathevet P, Nessah K, Dargent D, Mellier G. Laparoscopic management of adnexal masses in pregnancy: a case series. *Eur J Obstet Gynecol Reprod Biol* 2003; 108(2):217-22.

Author Information

Krupa Shah

Assistant Professor, Department of Obstetrics and Gynecology, Kasturba Medical College

S Anjurani

Assistant Professor, Department of Obstetrics and Gynecology, Kasturba Medical College

Vani Ramkumar

Professor, Department of Obstetrics and Gynecology, Kasturba Medical College

Parvathi Bhat

Professor, Department of Obstetrics and Gynecology, Kasturba Medical College

MS Urala

Professor, Department of Obstetrics and Gynecology, Kasturba Medical College