

Successful treatment of recurrent aphthous stomatitis of any origin with vitamin B12 (irrespective of its blood level)

I Volkov, I Rudoy, R Peleg, Y Press

Citation

I Volkov, I Rudoy, R Peleg, Y Press. *Successful treatment of recurrent aphthous stomatitis of any origin with vitamin B12 (irrespective of its blood level)*. The Internet Journal of Family Practice. 2006 Volume 5 Number 1.

Abstract

Recurrent aphthous stomatitis (RAS) is one of the most common oral mucosal lesions seen in primary care. Over the past four years we have treated 15 RAS patients with vitamin B12. Of these, 11 patients reported a rapid and complete recovery from RAS during treatment and the other four reported pronounced reduction in the frequency and severity of RAS episodes. We suppose that a treatment with vitamin B12 can be effective for patients suffering from RAS any origin, regardless of their serum vitamin B12 level. Now we are doing double-blind, placebo-controlled, randomized clinical trial addressing the issue. It's supposed to confirm the safety and effectiveness of vitamin B12 therapy for RAS.

INTRODUCTION

Recurrent aphthous stomatitis (RAS) is one of the most common oral mucosa lesions seen in primary care.^{1,2} The Greek term “aphthai” was initially used in relation to disorders of the mouth and is credited to Hippocrates.¹ RAS is a pathologic condition characterized by recurring, painful, small, oral mucosal ulcers with a round or oval aspect, clean borders, a peripheral erythematous halo, and a yellow or grayish base.^{1,3} The frequency of aphthous ulcers is up to 25% in the general population, and three-month recurrence rates are as high as 50%.² RAS is an idiopathic condition in most patients. The most likely precipitating factors are local trauma and stress. Other associated factors include systemic diseases, nutritional deficiencies, food allergies, genetic predisposition, immune disorders, medications, and HIV infection. Although RAS may be a marker of an underlying systemic illness such as celiac disease, or may present as one of the features of Behcet's disease, in most cases no other body systems are affected, and patients remain otherwise fit and well. Since the etiology is unknown, diagnosis is entirely based on history and clinical criteria and no laboratory procedures exist to confirm the diagnosis.^{4,5,6,7} Herbal multivitamins,⁸ adhesive pastes,⁹ local antiseptics,¹⁰ local antibiotics,¹¹ topical non-steroidal anti-inflammatory drugs,¹² topical corticosteroids,¹³ and even topical and systemic immuno-modulators, immunosuppressants, and corticosteroids^{14,15,16} are among the treatments given to RAS patients. Most of these achieve “short term” therapeutic goals such as alleviation of pain, reduction of ulcer duration,

and recovery of normal oral function.^{9,10,11,12,13,16} Very few treatments have been reported to achieve “long term” therapeutic goals such as reduction of the frequency and severity of RAS and maintenance of remission.^{8,13,14,15,16} We previously reported the successful treatment of three RAS patients with intramuscular vitamin B₁₂ injections (IM).¹⁷ We have now treated 15 RAS patients with vitamin B₁₂. We present a review of our clinical experience. We believe that the results are promising and that this therapeutic option should be further explored.

METHODS

Fifteen patients suffering from RAS have been treated with vitamin B₁₂ in our clinics over the past four years. In most cases they have presented to the clinic with unrelated symptoms, and the oral ulcers were incidental findings on physical examination. Patients were asked whether oral ulcers were a recurring problem. Before initiating vitamin B₁₂ therapy a complete blood count was done and plasma vitamin B₁₂ and folic acid levels were assessed.

We used one of two therapeutic regimens:

1. IM injections of vitamin B₁₂ (1000 mcg weekly for the first month and then 1000 mcg monthly – as maintenance therapy) for patients with serum vitamin B₁₂ level below 100 pg/ml, for patients with peripheral neuropathy or macrocytic anemia, and for patients coming from a low socio-economic level (in our country IM vitamin B₁₂ treatment is cheaper than oral vitamin B₁₂).

One sublingual vitamin B₁₂ tablet (1000 mcg) per day.²

No other treatment was given for RAS throughout the treatment and follow-up periods. The follow-up period ranged from 3 months to 4 years.

RESULTS

This report presents the results of treatment for 15 patients from two primary care practices. Nine patients (60%) were males. The mean age was 38.7±18.8 years (range 15-86). The patient population was ethnically heterogenic with 8 Jewish and 7 Bedouin patients. The mean duration of RAS prior to vitamin B₁₂ therapy was 11.2±10.7 years (range 1-38). The results of blood tests prior to therapy are shown in Table 1.

Figure 1

Table 1: Plasma hemoglobin, mean corpuscular volume (MCV), vitamin B and folic acid levels in the study population.

	Mean±SD	Range	Normal range [*]
B12 before treatment (pg/ml)	303.6±169.5	88-816	>250
Hemoglobin before treatment (g/dl)	13.6±2.0	10.0-16.8	Males: 13.5-17.5 Females: 12-16
MCV before treatment (fl)	85.3±6.9	75-104	80-100
Folic acid before treatment (ng/ml)	6.9±3.5	1.5-12.3	3.1-17.5

*Ref 18

Figure 2

Table 2: RAS disease characteristics before and during treatment, and length of treatment period.

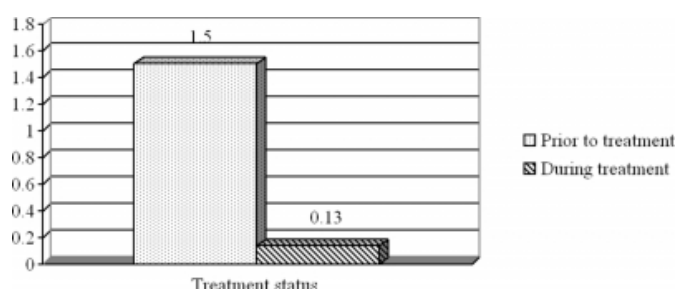
	Mean	Range
Mean duration of RAS (years)	11.2±10.7	1-38
Frequency of RAS before treatment (episodes/month)	1.5±1.2	0.3-4.0
Mean duration of treatment (months)	10.8±9.7	3-42
Frequency of RAS during treatment (episodes/month)	0.1±0.3	0-1.0

Eleven of the 15 patients (73%) were treated by IM injection, in most cases due to socio-economic considerations. The main results of treatment are presented in Table 2 and Fig. 1. Eleven patients reported a rapid and complete recovery from RAS during treatment and the other

four reported pronounced reduction in the frequency and severity of RAS episodes. Two of the four patients who did not report complete recovery were treated with sublingual vitamin B₁₂. The other two patients, who were treated with IM vitamin B₁₂, had long periods of non-adherence (over 2 months). When these two non-adherent patients received regular IM injections their aphthous ulcers disappeared completely.

Figure 3

Figure 1: Frequency of RAS episodes prior to and during vitamin B treatment (episodes per month).



DISCUSSION

In this report we review our clinic experience with 15 patients treated with vitamin B₁₂ for RAS. Interestingly, none of the patients complained of oral ulcers; all cases were discovered on physical examination. Reviewing literature, we were amazed by statistics that 10 to 50 % of general population suffers from RAS, and up to 60% of the medical staff! Why were we surprised? RAS is not considered a reason to pay a visit to the primary physician. Patients rarely complain of RAS, except for how it influences their daily lives. When we started to elucidate the phenomenon, we understood that at some moment aphthae in one's mouth was accepted as "a part of life". Many affected patients may not seek medical help because they don't believe that there is a definitive solution to their problem. Therefore, primary care physicians should actively inquire about this problem.

Although the precise role of vitamin B₁₂ deficiency in the pathogenesis of RAS is unclear, suppression of cell-mediated immunity and changes in the cells of the tongue and buccal mucosa have been reported.^{18,19} In terms of the normal range of vitamin B₁₂ levels,²⁰ only two patients in our patient population had vitamin B₁₂ deficiency (below 125 pg/ml), three others had marginal levels (from 125 to 250 pg/ml) and the other 10 had normal levels (above 250 pg/ml). There was no difference in the outcome of treatment between patients with deficient or borderline levels vitamin B₁₂ levels, and those with a normal level. How can this

phenomenon be explained? In most likelihood, a serum vitamin B₁₂ level may not reliably indicate “functional” vitamin B₁₂ status. The test for B₁₂ has several pitfalls.²¹ Most laboratories set normal limits at 200 to 900 pg/mL, but sensitivity and specificity vary greatly, depending on the method used. False negatives (ie, elevated levels in the presence of deficiency) can occur in true deficiency, active liver disease, lymphoma, autoimmune disease, and myeloproliferative disorders. False positives (i.e., low levels in the absence of deficiency) can occur in folate deficiency, pregnancy, multiple myeloma, and excessive vitamin C intake. The measurements are quite accurate for serum vitamin B₁₂ levels below 100 pg/mL. Some authors have suggested that vitamin B₁₂ treatment should be offered to all patients with clinical appearances of vitamin B₁₂ deficiency, even if their serum vitamin B₁₂ level is normal.²² Another explanation for this phenomenon (our “working hypothesis”) is that vitamin B₁₂ has some unique, but still unrecognized functions. Multifunctional systems have to maintain homeostasis. Man is an ideal example of a system that constantly aspires to attain optimal regulation, even under the stress of severe pathology. We assume that there are universal, interchangeable (as required) biologically active substances that regulate the system and try to keep it in balance. We propose that one of these substances is vitamin B₁₂. Why vitamin B₁₂? The list of organs and body systems in which vitamin B₁₂ plays a functional role is constantly being added to. Vitamin B₁₂ affects the normal growth of children, the peripheral and central nervous systems, bone marrow, skin and mucous membranes, bones, and vessels. Vitamin B₁₂ (cobalamin) is unique among all the vitamins in that it contains not only a complex organic molecule but also an essential trace element, cobalt. Vitamin B₁₂ plays an important role in DNA synthesis and has important immunomodulatory and neurotrophic effects. Deficiency of vitamin B₁₂ can lead to a wide spectrum of disorders that can often be reversed by early diagnosis and prompt treatment.

It is possible that even when the serum cobalamin level is high, treatment with vitamin B₁₂ can correct defects caused by other biologically active substances. We suppose this has been proved successful in the treatment of recurrent aphthous stomatitis with vitamin B₁₂ (irrespective of its blood level !). We call this phenomenon the “Master Key” effect.²³

CONCLUSION

Treatment with vitamin B₁₂ can be effective for patients

suffering from RAS any origin, regardless of their serum vitamin B₁₂ level. Now we are doing double-blind, placebo-controlled, randomized clinical trial addressing the issue. It's supposed to confirm the safety and effectiveness of vitamin B₁₂ therapy for RAS.

CORRESPONDENCE TO

Dr. I. Volkov, MD Department of Family Medicine Faculty of Health Sciences Ben-Gurion University of the Negev P.O.B. 653 Beer-Sheva, Israel 84105 Tel: +972-8-6431530 Cell phone: +972-54-7829623 Fax: +972-8-6404832 e-mail: r0019@zahav.net.il

References

1. Ship JA, Chavez EM, Doerr PA, Henson BS, Sarmadi M. Recurrent aphthous stomatitis. *Quintessence Int* 2000; 31:95-112.
2. Barrons RW. Treatment strategies for recurrent oral aphthous ulcers. *Am J Health Syst Pharm* 2001; 58:41-50.
3. Porter SR, Hegarty A, Kaliakatsou F, Hodgson TA, Scully C. Recurrent aphthous stomatitis. *Clin Dermatol* 2000; 18:569-78.
4. Piskin S, Sayan C, Durukan N, Senol M. Serum iron, ferritin, folic acid, and vitamin B12 levels in recurrent aphthous stomatitis. *J Eur Acad Dermatol Venereol* 2002; 16:66-7.
5. Wray D, Ferguson MM, Mason DK, Hutcheon AW, Dagg JH. Recurrent aphthae: treatment with vitamin B12, folic acid, and iron. *BMJ* 1975; 2:490-3.
6. Barnadas MA, Remacha A, Condomines J, de Moragas JM. [Hematologic deficiencies in patients with recurrent oral aphthae]. *Med Clin (Barc)* 1997; 109:85-7.
7. Natah SS, Kontinen YT, Enattah NS, Ashammakhi N, Sharkey KA, Hayrinen-Immonen R. Recurrent aphthous ulcers today: a review of the growing knowledge. *Int J Oral Maxillofac Implants* 2004; 33:221-34.
8. Pedersen A, Hougen HP, Klausen B, Winther K. LongoVital in the prevention of recurrent aphthous ulceration. *J Oral Pathol Med* 1990; 19:371-5.
9. Reznik D, O'Daniels CM. Clinical treatment evaluations of a new topical oral medication. *Compend Contin Educ Dent Suppl* 2001; 32:17-21.
10. Meiller TF, Kutcher MJ, Overholser CD, Niehaus C, DePaola LG, Siegel MA. Effect of an antimicrobial mouthrinse on recurrent aphthous ulcerations. *Oral Surg Oral Med Oral Pathol Oral Radiol Endod* 1991; 72:425-9.
11. Kerr AR, Drexel CA, Spielman AI. The efficacy and safety of 50 mg penicillin G potassium troches for recurrent aphthous ulcers. *Oral Surg Oral Med Oral Pathol Oral Radiol Endod* 2003; 96:685-94.
12. Murray B, McGuinness N, Biagioni P, Hyland P, Lamey PJ. A comparative study of the efficacy of Aphtheal in the management of recurrent minor aphthous ulceration. *J Oral Pathol Med* 2005; 34:413-9.
13. Gonzalez-Moles MA, Morales P, Rodriguez-Archilla A, Isabel IR, Gonzalez-Moles S. Treatment of severe chronic oral erosive lesions with clobetasol propionate in aqueous solution. *Oral Surg Oral Med Oral Pathol Oral Radiol Endod* 2002; 93:264-70.
14. Hutchinson VA, Angenend JL, Mok WL, Cummins JM, Richards AB. Chronic recurrent aphthous stomatitis: oral treatment with low-dose interferon alpha. *Mol Biother* 1990;

2:160-4.

15. Katz J, Langevitz P, Shemer J, Barak S, Livneh A.

Prevention of recurrent aphthous stomatitis with colchicine: an open trial. *J Am Acad Dermatol* 1994; 31(3 Pt 1):459-61.

16. Femiano F, Gombos F, Scully C. Recurrent aphthous stomatitis unresponsive to topical corticosteroids: a study of the comparative therapeutic effects of systemic prednisone and systemic sulodexide. *Int J Dermatol* 2003; 42:394-7.

17. Volkov I, Rudoy I, Abu-Rabia U, Masalha T, Masalha R. Recurrent aphthous stomatitis responsive to vitamin B12 treatment. *Can Fam Phys* 2005; 51:844-5.

18. Field EA, Speechley JA, Rugman FR, Varga E, Tyldesley WR. Oral signs and symptoms in patients with undiagnosed vitamin B12 deficiency. *J Oral Pathol Med* 1995; 24:468-70.

19. Weusten BL, van de Wiel A. Aphthous ulcers and

vitamin B12 deficiency. *Neth J Med* 1998; 53:172-5.

20. Kratz A, Ferraro M, Sluss PM, Lewandrowski KB. Case records of the Massachusetts General Hospital. Weekly clinicopathological exercises. Laboratory reference values. *N Engl J Med* 2004; 351:1548-63.

21. Dharmarajan TS, Norkus EP. Approaches to vitamin B12 deficiency. Early treatment may prevent devastating complications. *Postgrad Med*. 2001 Jul;110(1):99-105

22. Solomon LR. Cobalamin-responsive disorders in the ambulatory care setting: unreliability of cobalamin, methylmalonic acid, and homocysteine testing. *Blood*

23. Ilia Volkov MD, Yan Press MD, Inna Rudoy MD. Vitamin B12 could be a "MASTER KEY" in the regulation of multiple pathological processes. *Journal of Nippon Medical School*. 2006;73(2): 65-69

Author Information

Ilia Volkov, M.D.

Department of Family Medicine, Faculty of Health Sciences, Ben-Gurion University of the Negev

Inna Rudoy, MD

Department of Family Medicine, Faculty of Health Sciences, Ben-Gurion University of the Negev

Roni Peleg, MD

Department of Family Medicine, Faculty of Health Sciences, Ben-Gurion University of the Negev

Yan Press, MD

Department of Family Medicine, Faculty of Health Sciences, Ben-Gurion University of the Negev