# Unusual Cause Of Obstructive Sleep Apnea In A Pediatric Patient: Lipoma Of The Hypopharynx

A Shah, R Barretto, M Gerber

**Citation**

A Shah, R Barretto, M Gerber. *Unusual Cause Of Obstructive Sleep Apnea In A Pediatric Patient: Lipoma Of The Hypopharynx*. The Internet Journal of Otorhinolaryngology. 2002 Volume 2 Number 1.

**Abstract**

A case of lipoma of the hypopharynx is described in a 14-year-old female. The patient presented with symptoms of obstructive sleep apnea without any voice changes for several years. The initial physical exam noted unimpressive tonsils and no neck masses palpated. A fiberoptic scope was subsequently performed which demonstrated a 2 x 3 cm hypopharyngeal mass. The therapy was endoscopic surgical removal with CO2 laser with complete cure. Pathology revealed normal mature adipocytes consistent with a lipoma. This case represents only the fourth reported pediatric case of lipoma of the larynx or hypopharynx.

## CASE REPORT

A 14 y/o female was seen at Children's Memorial Hospital for evaluation for upper airway obstruction for 2 years which consisted of snoring at night with frequent witnessed apneic episodes. The patient denied dysphagia or any symptoms of aspiration or voice change. Physical exam revealed unimpressive tonsils. The flexible fiberoptic exam revealed a large supraglottic mass on the left aryepiglottic fold residing in the pyriform sinus. Both vocal cords were mobile and within normal limits. A CT scan was ordered and noted a 2.2 x 3 x 3.9 cm low attenuation, homogenous mass comprised of fat with multiple soft tissue strands with a density lower than water.

**Figure 1**

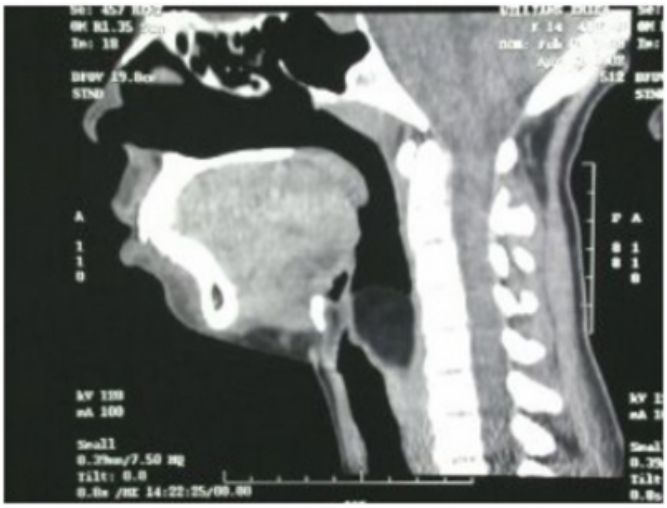

**Figure 2**

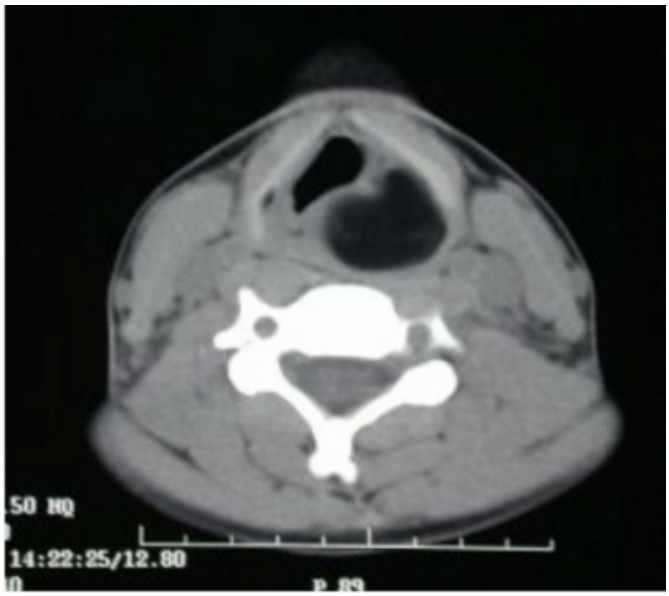

**Figure 3**

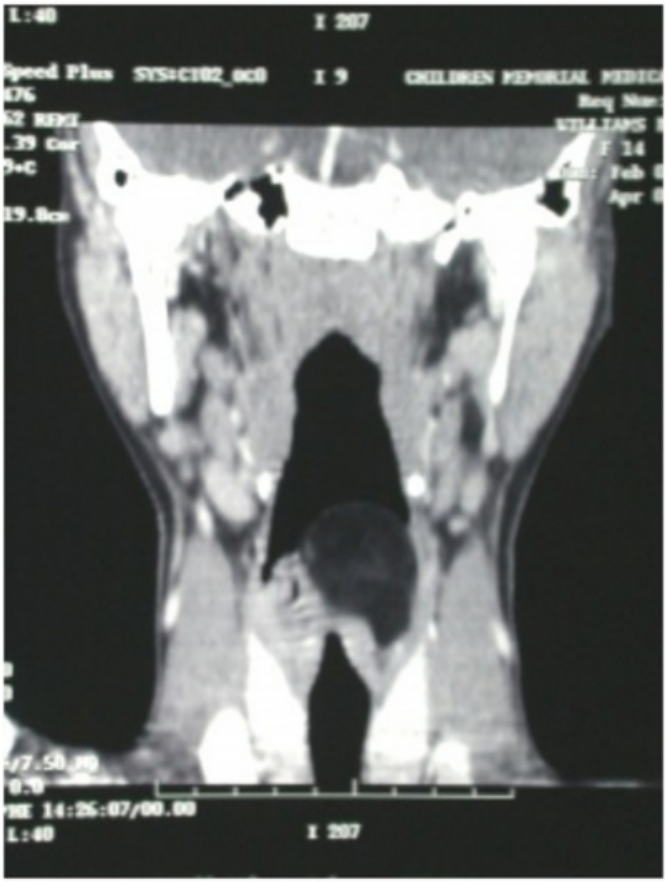

The patient was taken to the operating room and a Lindholm laryngoscope blade was used to suspend the larynx. The supraglottic mass was visualized and removed with the CO2 laser. The incision was first made horizontally over the mass and the mass was subsequently freed from the left pyriform sinus. Due to the size of the lesion, the laryngoscope was removed with the lipoma attached to the distal end.

A homogenous tan-yellow surface was seen grossly. Mature adipose tissue was seen microscopically consistent with a lipoma.

## DISCUSSION

Fewer than 100 laryngeal lipomas have been described in the English literature, of which the vast majority of patients present in the sixth decade of life or older. Typically laryngeal lipomas present as solitary masses.

The three previous cases of pediatric laryngeal lipoma presented with upper airway obstruction as well. Murty, et al reported a case of a 16 year old who complained of voice change and snoring as a result of a laryngeal lipoma which required an anterior pharyngotomy approach. Zakrzewski and Dinsdale, et al both reported similar findings in patients each requiring an external procedure for removal.

The etiology of lipomas is unknown. One theory is that the fibroblast is a multipotential cell which may differentiate into a fat cell and form a lipoma. Another theory is that lipomas form where lipomatous tissue is found below the false cords, epiglottis, and aryepiglottic fold.

Diagnosis of laryngeal lipoma is usually challenging. Symptoms from all reported cases range from dysphagia, dyspnea, airway obstruction, hoarseness, globus pharyngeus. There have been case reports of patients asphyxiating from the tumor regurgitating into the laryngeal introitus. Frequently, the laryngeal lipoma will present as a submucosal mass, however it can present as a pedunculated intraluminal projection. Endoscopically, lipomas can be confused with a mucous retention cyst or laryngocele. Laryngeal lipomas have characteristic CT scan findings which demonstrate a nonenhancing homogenous structure with low attenuation and a density lower than water. Histopathologically, lipomas are encapsulated tumors with mature white fat cells. Well-differentitated liposarcomas may appear similar, however they lack a capsule and are infiltrative with cytologic evidence of atypia and often contain lipoblasts. Liposarcomas often have a rapid growth phase as well.

Treatment of lipomas is surgical. Left untreated, lipomas can be life threatening with cases of airway obstruction reported and death. Lipomas also must be removed for a definitive pathologic diagnosis to exclude liposarcoma. The approach is dependent on the size of the lipoma. The surgeon should weigh the morbidity of an external approach with the chance of recurrence with incomplete removal.

This case represents an exceedingly rare case of pediatric obstructive sleep apnea.

### References

1. Murty KD, Murty PSN, et al. Lipoma of the Larynx. American Journal of Otolaryngology 1994;15(2): 149-151.
2. Zakrzewski A. Subglottic Lipoma of the Larynx. Journal of Laryngology and Otology. 1965:79:1039-1048.
3. Dinsdale RC, Manning S, et al. Myxoid Laryngeal Lipoma in a Juvenile. Otolaryngology-Head and Neck Surgery 1990;103:653-657.
4. Jungehulsing M, Fischbach R, et al. Rare Benign Tumors: Laryngeal and Hypopharyngeal Lipomata. Annals of Otology Rhinology Laryngology 2000;109:301-5.
5. Yoskovitch A, Efrain C, et al. Giant Lipoma of the Larynx: A Case Report and Literature Review. Ear, Nose, Throat Journal 1999:122-4.
6. Cauchois R, Laccourreye O, et al. Intrinsic Infilitrating Laryngeal Lipoma. Otol Head and Neck 1995;112:777-9.
7. Wenig BM. Lipoma of the Larynx and Hypopharynx: a

Review of the Literature with the Addition of Three New Cases. Journal of Laryngology and Otology 1995;109:353-7.

## Author Information

**Anil R. Shah, MD**
Department of Otolaryngology, University of Illinois at Chicago

**Robert L. Barretto, MD**
Department of Otolaryngology, Children's Memorial Hospital, Northwestern University Medical Hospital

**Mark E. Gerber, MD**
Department of Otolaryngology, Children's Memorial Hospital, Northwestern University Medical Hospital