

Unilateral Pulmonary Edema Following Surgical Repair Of Diaphragmatic Hernia: A Case Report

A El-Dawlatly, K Abdullah, A Al-Dohayan

Citation

A El-Dawlatly, K Abdullah, A Al-Dohayan. *Unilateral Pulmonary Edema Following Surgical Repair Of Diaphragmatic Hernia: A Case Report*. The Internet Journal of Anesthesiology. 2002 Volume 6 Number 2.

Abstract

Unilateral pulmonary edema may occur after sudden re-expansion of compressed lung which may be due to pneumothorax, pulmonary effusion, tumor, or diaphragmatic hernia (1). We describe in this report a case of unilateral re-expansion pulmonary edema following surgical correction of diaphragmatic hernia.

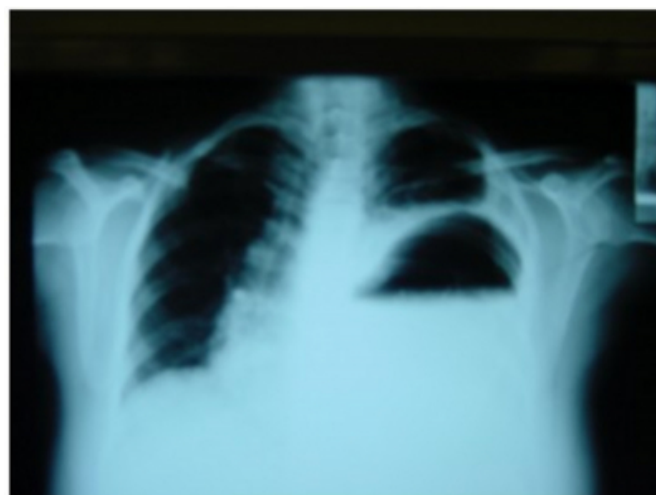CASE REPORT

A 39 yr-old female patient (body weight 63 kg, height 168 cm), not known to have any medical illness before, admitted through the emergency room complaining of abdominal pain, which was generalized at first, then became localized at epigastric area. The pain was colicky in nature, radiating to left infra-scapular area, not related to any position accompanied with vomiting following each meal. Her past medical history was significant for old road traffic accident, 2 yr ago, with multiple orthopedic fractures. Clinical examination revealed an apprehensive patient with tachypnea and tachycardia. Chest examination showed less expansion, hyper-resonance, and decreased air entry to the left side of the chest.

The abdomen was soft, lax, and not tender. Her laboratory tests & ECG were within normal limits. Analysis of arterial blood gases on room air disclosed the following values: pH 7.38, PaO₂ 78 mmHg and PaCO₂ 34 mmHg. Chest-x-ray after barium meal showed the stomach in the left hemithorax (Fig 1).

Figure 1

Fig 1. Chest x-ray after barium meal showing stomach in left hemithorax



The diagnosis of diaphragmatic hernia was made and she was scheduled to undergo surgical repair. In the operating theatre, suctioning of stomach secretions was done through nasogastric tube followed by injection of 30 ml of non-particulate anti-acid through. Anesthesia was induced in a rapid sequence order with propofol 170mg and fentanyl 100mcg followed by cricoid pressure. Endotracheal intubation was facilitated with succinylcholine 70mg. Left sided, double-lumen endobronchial tube (DLT) was used (35Fr). Fibro-optic bronchoscope was used to confirm correct position. Anesthesia was maintained with N₂O/O₂, and 1 MAC sevoflurane. During surgery, the following parameters were continuously monitored: ECG, end-tidal CO₂ (Capnography, Datex, Finland), peripheral O₂ saturation (SpO₂) (Ohmeda, USA), non-invasive blood pressure

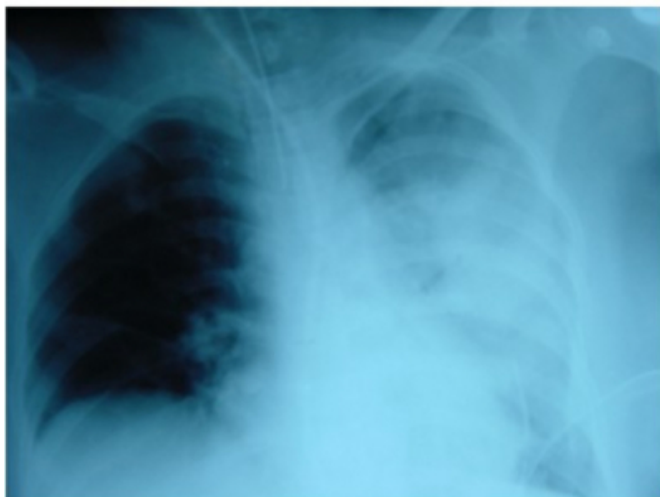(Dinamap, Critikon, USA), urine output (Foley, s catheter).

The left radial artery was cannulated for continuous measurement of blood pressure and blood gases. The right internal jugular vein was cannulated for central venous pressure monitoring. Incremental doses of fentanyl and cisatracurium were given when required. Laparoscopy with CO₂ insufflation was performed with the patient supine with slight head-up position. The stomach was released and reduced into abdominal cavity. The diaphragmatic tear was about 5 x 5 cm, through which the left lung could be seen to be totally collapsed and not expanding with ventilation. The diaphragmatic tear was sutured, and an intercostal tube was inserted in the left 6th intercostals space. The operation lasted for 3 hr, with minimal blood loss. At the end of surgery, a bolus dose of cisatracurium and midazolam were given before replacement of the DLT to single-lumen endotracheal tube.

Then the patient was transferred to the intensive care unit (ICU) for further management. In the ICU, she was haemodynamically stable, sedated with propofol infusion. Controlled ventilation was maintained with the following parameters: FiO₂ 0.6, respiratory rate 10/min, tidal volume 650 ml, PEEP 3 mmHg. Her ABG were within normal ranges. Profuse amount of whitish secretions sucked out of the trachea. Chest-x-ray showed a picture of unilateral pulmonary edema (Fig 2).

Figure 2

Fig 2. Post-operative uni-lateral pulmonary edema

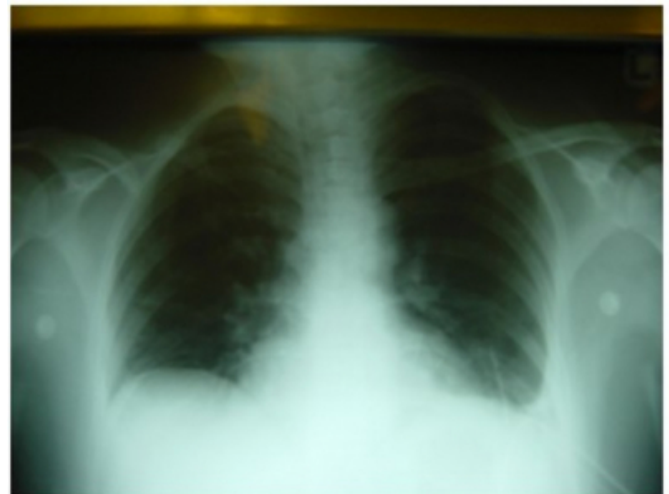


The intercostal tube was in situ, draining serous sanguineous fluid. Frusemide 50mg was given i.v. Her ABG showed PO₂ of 105 mmHg on FiO₂ of 1.0, with copious amount of whitish tracheal secretions. Controlled ventilation was

continued, but PEEP was increased to 6 mmHg. Series of ABG were done and showed gradual improvement in arterial O₂ pressure, so FiO₂ was reduced to 0.4. A chest x-ray was done, which disclosed a clear, well inflated both lung fields (Fig 3). Weaning and extubation were successively done 36 hr after surgery, and then she was transferred to the high dependency unit. One day later the intercostal tube was removed and she was discharged to the normal floor.

Figure 3

Fig 3. Clear lung fields with intercostal tube is in situ



DISCUSSION

The etiology of diaphragmatic hernia in the case presented was not well defined. It may be secondary to the old road traffic accident (2), or being a case of late onset congenital diaphragmatic hernia (CDH) (3). The Diagnosis of diaphragmatic rupture is often missed after blunt thoracic and abdominal injuries. A variety of reasons accounts for the tendency to overlook diaphragmatic injury in trauma victims, first, it is uncommon condition presenting to an unsuspecting clinician, second, the paucity of pathognomonic clinical signs and third, the diverting attention of life-threatening visceral injuries (4). Severe complications have been described in patients having a late presenting CDH namely sudden cardio-respiratory arrest (5). The occurrence of acute pulmonary edema shortly after the surgical repair can involve the ipsi and/or contralateral lung (6). Re-expansion pulmonary edema usually occurs after prolonged lung collapse with rapid re-expansion of the previously atelectatic lung undergoes re-perfusion and edema. These events may be followed by a form of high-permeability pulmonary edema due to increase in pulmonary vascular permeability followed anoxic damage of the capillary endothelium and mechanical damage of the blood vessels

from overstretching during the process of re-expansion (7). This is similar to the unilateral pulmonary edema after treatment of spontaneous pneumothorax (8). The treatment of re-expansion pulmonary edema is symptomatic with mechanical ventilation and PEEP.

In conclusion, gastric distension is a life-threatening complication in patients with diaphragmatic hernia. The optimal care of such patients depends on prompt diagnosis and early recognition of the severity of the patient condition, which present with respiratory and/or circulatory compromise. We believe that re-expansion pulmonary edema should be anticipated following surgical correction of diaphragmatic hernia.

References

1. Ravin CE, Dahmash NS. Re-expansion pulmonary edema. Chest 1980;77:709-10.
2. Chen JC, Wilson SE. Diaphragmatic injuries: recognition and management in sixty-two patients. Am Surg. 1991; 57:810-815.
3. Paut O, Mely L, Viard L et al. Acute presentation of CDH pass the neonatal period: a life threatening emergency. Canadian Journal of Anesthesia. June 1996; 43: 234-36.
4. Toh CL, Yeo TT, Chua CL, Low CH. Diaphragmatic injuries: why are they overlooked?. J R Coll Surg Edinb. 1991; 36:25-8.
5. Berman L, Stringer D, Ein SH, Shandling B. The late presenting pediatric Bochdalek hernia: a 20 years review. J Pediatr Surg 1988, 23: 735-9.
6. Paut O, Gaillat F, Delarue A, Benneru JJ, et al. Acute pulmonary edema following repair of congenital diaphragmatic hernia. Pediatric Anesthesia 1992; 2:339-42.
7. Naoki M, Shuji D, Testu K, Hirushi M. Re-expansion pulmonary edema after mediastinal tumor removal. Anesth Analg 1991;73:646-8.
8. Poulias GE, Prombonas E. Massive unilateral pulmonary edema as a rapid re-expansion sequel. (The post-expansion syndrom. Scand J Thorac Cardiovasc Surg 1974; 8:67-9.

Author Information

A. A. El-Dawlatly

Departments of Anesthesia and Surgery, King Suad University and KKHU

K. M. Abdullah

Departments of Anesthesia and Surgery, King Suad University and KKHU

A. Al-Dohayan

Departments of Anesthesia and Surgery, College of Medicine, King Suad University and KKHU