

# Late Decompression Of Cauda Equina Syndrome: Is It Worthwhile? Report Of Two Cases.

N Motsitsi

## Citation

N Motsitsi. *Late Decompression Of Cauda Equina Syndrome: Is It Worthwhile? Report Of Two Cases.*. The Internet Journal of Spine Surgery. 2009 Volume 5 Number 2.

## Abstract

Cauda equina syndrome is relatively a rare surgical entity. It is a medical emergency. It is one of the commonest causes of litigation against medical practitioners because it is commonly missed. It is believed that for a good clinical outcome, surgical decompression must be done within 24 hours. Late decompression (20 – 72 hours) is believed to be associated with poor outcome. The two patients presented here do indicate that late decompression is a worthwhile procedure. Good or satisfactory neurological outcome may occur despite late presentation.

## INTRODUCTION

Cauda equina refers to the bundles of spinal nerve roots within the spinal canal below the level of the first lumbar vertebra.<sup>1</sup> It is a complex of low backache, sciatica, saddle hypoaesthesia, motor weakness of the lower limbs and either bowel or bladder dysfunction.<sup>1</sup> You do not need all the criteria to diagnose CES. It is a serious neurologic condition. It is a dire emergency.<sup>2</sup>

There is great controversy regarding the management of CES. It is controversial whether early surgery (within 24 hours) has a better outcome

compared to late surgery (> 24 - 48 hours) or whether the duration of symptoms pre-operatively affects surgical outcome.<sup>3</sup> It is one of the most common cause of litigation against medical practitioners.<sup>2</sup> We present two patients who presented very late with the clinical problem of CES. Surgical decompression was done despite late presentation.

## CASE 1

**History:** A 63 year-old male patient presented with a history of sudden onset of inability to walk for fourteen days. He allegedly fell off a chair. He gave no history of preceding backache. He had complete loss of bladder and some bowel functions.

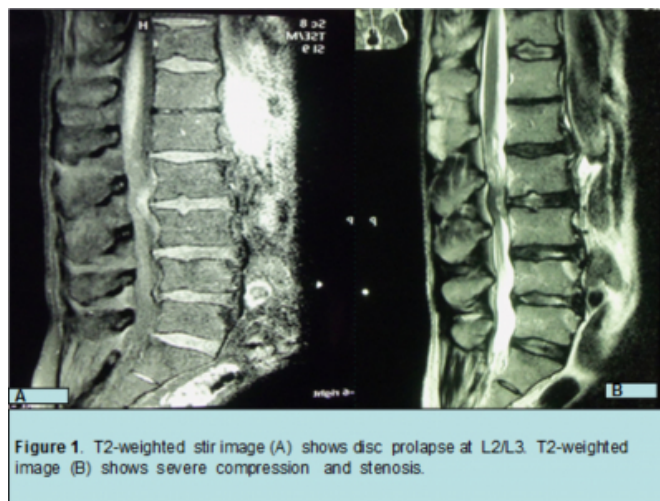
**Examination:** General examination was unremarkable. The level of neurological dysfunction was at L2/L3. He had symmetrical distal motor loss from L2 to S1 (<sup>2</sup>/5 motor power according to MRC scale), peri-anal sensory loss and

weak sphincter function. Reflexes were decreased.

**Pathology:** X-rays did not show any pathology. Urgent magnetic resonance imaging (MRI) showed disc prolapse with severe cauda equina compression at L2/L3 (figure 1).

## Figure 1

Fig1



**Operation:** L2/L3 discectomy without fusion was done.

**Post-operative course:** rehabilitation was started one week post-operatively. He showed good improvement. Five months post-operatively he was ambulant with crutches. He resumed his casual duties six months after the operation. At one year following surgery, he was fully independent; he was not using any assistive device. He had almost full motor and sensory recovery except slight symmetrical weakness

involving the L5/S1 nerve roots (<sup>4</sup>/5 motor power). He had full bladder and bowel control. The last review was done four months later. There were no further improvement in motor power.

## **CASE 2**

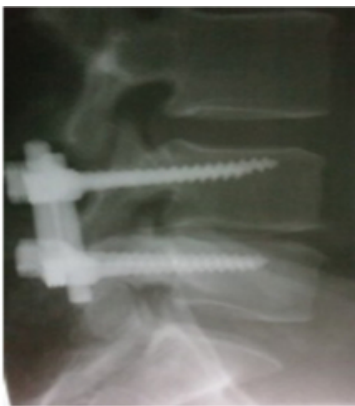**History:** A 49 year-old labourer presented with a clinical problem of progressive lower limbs weakness and difficulty with urination or voiding for a period of three weeks. He has been under the care of the author for a period of a year. He had a problem of chronic low backache and instability. When last reviewed by the author, he had no neurological problems or complaints and lumbar x-rays showed early disc degenerative changes.

**Examination:** Generally, the findings were not remarkable. Neurologically, he had bilateral and symmetrical motor weakness: L5 = <sup>1</sup>/5, S1 = <sup>2</sup>/5, weak sphincter function or anal tone, sensation (light touch and pinprick) was decreased in the perineal area. Reflexes were decreased.

**Pathology:** ordinary x-rays showed early degenerative changes at L4/L5. An urgent MRI was requested. It showed compression of the cauda equina at L4/L5 level. Decompression was done four days later due to administrative delays. Operation: L4/L5 discectomy was done. Arthrodesis was done using transpedicular technique (figure 2).

## **Figure 2**

Fig2



**Figure 2.** Lateral view of the lumbar spine showing L4/L5 transpedicular fixation Following discectomy.

**Post-operative course:** rehabilitation was done a week later. He progressed very well. He resumed light duty six months after the operation. He was reviewed a year later; he was completely independent. He had full bladder and bowel control. The motor power had improved bilaterally and

symmetrically to <sup>4</sup>/5. The last review was done eighteen months after the operation and there was no further motor improvement.

## **DISCUSSION**

Our patients do show that late decompression in CES is a worthwhile procedure. The final outcome following decompression even in these late cases is unpredictable. Neurological improvement reached a plateau one year following decompression. Both patients improved to such an extent that they reached independent status by one year. Bladder and sphincter functions also recovered fully. Both patients had slight motor weakness when reviewed for the last time.

The literature shows contradictory results following surgical decompression of CES. Kennedy J.G. et al.<sup>4</sup> showed that there is a relationship between delayed decompression (20 - 72 hours) and poor outcome: delayed surgery is associated with poor outcome. They showed that the rate of slow onset and favourable outcome did not reach statistical significance. Scott Shapiro<sup>5</sup> in his series showed that delayed surgery of more than 48 hours leads to persistent severe motor deficits, persistent bladder, sphincter and sexual dysfunctions. Assad Qureshi et al.<sup>6</sup> in their prospective series argued that the duration of symptoms prior to surgery did not appear to influence the outcome. They stated that the severity of bladder dysfunction at the time of surgery is the dominant factor in the recovery of bladder function. Decompression, whether done early (< 24 hours), or late (within 24 to 48 hours or more than 48 hours), did not lead to significant difference in outcome. The value of early surgical intervention versus late was also questioned by Gleave J. R. M. et al.<sup>3</sup> Their study did not show significant difference between early versus late surgery. Sean S. Kholes et al.<sup>7</sup> did a critical analysis of the meta-analysis done by Kostuik et al.; they demonstrated methodological flaws in the study. One of the major flaws was that the study underestimated the value of early surgery.

Michael J. H. McCarthy et al.<sup>8</sup> in their recent study arrived at the following conclusions:

Symptoms duration before operation and speed of onset do not affect the outcome more than two years after surgery.

Patients who had CES do not return to normal status.

There is no hard evidence that early surgery leads to better outcome. Prospective and well powered studies are needed

to address this problem.

## References

1. Gleave J. R. W. and MacFarlane. Cauda equina syndrome: what is the relationship between timing of surgery and outcome? *British Journal of Neurosurgery* 2002; 16(4): 325 - 328.
2. Kennedy J. G., Soffe K. E., McGrath A., Stephens M. M., Walsh M. G., and McManus F. Predictors of outcome in cauda equina syndrome. *European Spine Journal* (1999) 8: 317 - 322.
3. Kennedy J. G. , Hannon J., Mullet , and O'Rourke K. Cauda equina syndrome. *Current opinion in Orthopaedics* (2000) 11: 192 - 195.
4. Kohles Sean S., Kohles David, Karp P., Erlich V. M., and Pollisar N. L. Time-dependent surgical outcomes following Cauda Equina Syndrome diagnosis. *Spine* (2004) Volume 29, Number 11, pp 1281 - 1287.
5. Markam D.E. Cauda Equina Syndrome: diagnosis, delay and litigation risk. *Current Orthopaedics* (2004) 18, 58 - 62.
6. McCarthy Michael J. H., Aylott Caspar E., Grevitt Michael P., and Hegarty J. Cauda Equina Syndrome. Factors affecting long-term functional and sphincter outcome. *Spine* ( 2007) Volume 12, Number 2, pp 207 - 216.
7. Qureshi Assad and Sell Phillip. Cauda equina syndrome treated by surgical decompression: the influence of timing on surgical outcome. *European Spine Journal* (2007) 16: 2143 - 2151.
8. Shapiro Scott. Medical realities of Cauda Equina Syndrome secondary to lumbar disc herniation. *Spine* (2000), Volume 25, Number 3, pp 348 - 352.

**Author Information**

**N. S. Motsitsi, M.MED. F.C.S.**

Head of Department, Department of Orthopaedic Surgery, Kalafong Hospital