

# Stress Fracture Of The Supracondylar Region Of The Femur Induced By The Weight Of The Tibial Ring Fixator

S Dhar, M Mir

## Citation

S Dhar, M Mir. *Stress Fracture Of The Supracondylar Region Of The Femur Induced By The Weight Of The Tibial Ring Fixator*. The Internet Journal of Orthopedic Surgery. 2006 Volume 4 Number 1.

## Abstract

Since its introduction the Ilizarov method has been applied to various orthopaedic pathologies including infected non unions, limb lengthening, deformity correction, filling of defects, arthrosis, arthrodesis, osteomyelitis, occlusive vascular disease and achondroplasia.[4].

The biology of bone and soft tissue regeneration under the conditions of tension stress have virtually solved the healing problems of bone.[8].

In infected non union of long bones, the previous methods of treatment were associated with disuse osteoporosis, soft tissue dystrophy and persistent infection.[9]. In comparison the stable fixation afforded by the Ilizarov apparatus avoids joint immobilization, positively influences osteogenesis, improves circulation while avoiding stiffness.[8,11]. Inherent to the success of this method is the emphasis on early weight bearing, range of motion and gait training.[11]

Significant complications with Ilizarov procedures have been shown to be rare and less severe.[11,14]. Paley has described and classified these complications in terms of problems, obstacles and true complications.[14].

We report two cases of stress induced supracondylar fractures of the femur due to the weight of the tibial ring fixator applied for infected non union in the paediatric age group. Complications due to the inherent weight of the fixator construct have never been documented in literature before.

## CASE REPORTS

From 1996 our hospital started using the Ilizarov ring fixator in children under 15 years of age. Upto September 2004 we had applied this methodology in 39 paediatric patients, with the tibia being fixed in 29 cases. Two of these cases developed a supracondylar fracture of the femur more than two months into their treatment period.

### CASE REPORT 1

A ten year old female child was treated for infected non union of the tibia with application of the Ilizarov fixator after debridement, and compression was applied at the fracture site[ monofocal osteosynthesis]. Initially the patient was put on supervised physiotherapy. After 5 weeks the patient was asked to come to the outdoor on a two weekly basis. Ten weeks into the treatment period the patient reported to the hospital with pain in the lower femoral region with swelling. There was no history of trauma. An Xray of the knee was

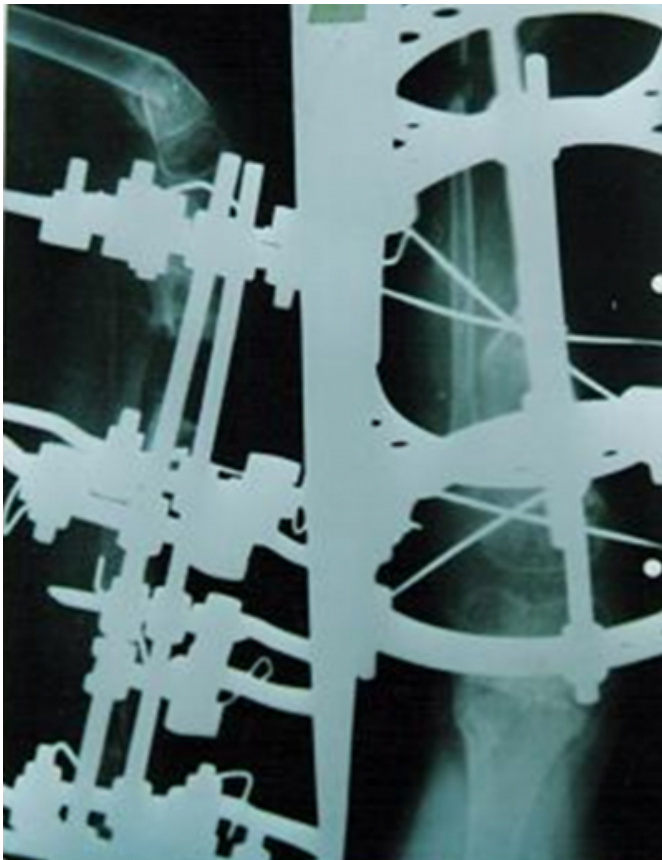taken which showed a fracture of the supracondylar region of the femur, which was angulated anteriorly. As the patient was nearing completion of treatment for the primary pathology hence the fixator was removed and a hip spica applied. The fracture healed uneventfully.

### CASE REPORT 2


An eight year old female child who suffered from a fire arm injury to the tibia was treated by an Ilizarov fixator, with debridement, corticotomy and distraction osteogenesis [bifocal osteosynthesis]. Three months into the treatment period a routine follow up xray showed a fracture of the lower femur which was angulated anteriorly. The patient reported no symptoms of pain or preceding trauma. The xray showed that the fracture was already healing as evidenced by the callus formation. The patient was admitted and supervised for three more weeks by which time the fracture had united. Both the patients had been treated with debridement and conventional external fixation for 8 weeks

preceding the application of the ring fixator.

**Figure 1**



**Figure 2**



## **DISCUSSION**

The purpose of reporting these cases is to highlight the possible effects of the weight of the Ilizarov fixator when combined with aggressive physical rehabilitation in limbs where the primary infective non union has resulted in weakness of the adjacent bones due to disuse porosis, in the paediatric population.

The paediatric applications of the Ilizarov technique have

multiplied recently due to its versatility to include treatment of congenital pseudoarthrosis, clubfoot, congenital hand abnormalities and forearm conditions.<sup>[1,3,5,13]</sup>. Residuals of non union, pseudoarthrosis, segmental defects, shortening, malunion, chronic osteomyelitis, joint contracture and soft tissue atrophy are also managed with this method.<sup>[6]</sup>. The method in these situations often requires a prolonged treatment time.<sup>[10]</sup>.

Non unions of the tibia associated with infection have always been a challenge to the orthopaedic surgeon. This is because of the additional complicating factors like deformity, leg length discrepancy, joint stiffness, soft tissue atrophy and disuse osteoporosis.<sup>[2, 6]</sup>.

The Ilizarov method is a technique for generating both bone and soft tissues through application of tension to the tissue under carefully controlled conditions. This involves use of an external fixator that is rigid to bending and torsion stresses but allows axial micromotion.<sup>[12]</sup>. According to Paley, the fixator permits full weight bearing and complete function. Complete range of motion and cyclical loading with walking are mandatory, because they promote tissue growth.<sup>[12]</sup>.

The biomechanical goals of the external ring fixation are, to maintain the bone ends in stable alignment, control the movement of the bone projectile and allow compression of the target zone. The tension in the wires is to be kept at 50-130 kilograms which mandates sufficiently heavy and rigid rings to prevent distortion.<sup>[6]</sup>. According to Ilizarov, most applications need hinges, posts, support plates, translation assemblies or rotation mechanisms permitting reduction and alignment of osseous fragments in multiple planes, either simultaneously or consecutively.<sup>[4]</sup>. All these facts add to the weight of the fixator. A properly applied frame should not restrict the function of the adjacent joints, while permitting full weight bearing and physiologic function of the entire limb. This enhances local circulation, shortens period of osseous callus formation while promoting conditions for fracture union and functional recovery.<sup>[4]</sup>.

Central to the Ilizarov method is the almost immediate attempt at restoration of range of motion of adjacent joints, weight bearing and gait training.<sup>[7,8,11]</sup>.

Complications of the Ilizarov method have been documented and estimated at 33% to 150%. To induce a sense of perspective Dror Paley classified complications into three

groups i.e. Problems, Obstacles and True complications. He defined a problem as a potential but expected difficulty that is expected to resolve at the end of the treatment period by non operative methods. An obstacle is a potential but expected difficulty that is expected to resolve at the end of the treatment period by operative intervention. True complications are complications that remain unresolved at the end of the treatment period often precluding the original plan. Paley concluded that significant complications associated with the Ilizarov procedures have been shown to be rare.<sup>[14]</sup>.

Both of our cases suffered from infected non union of the tibia. Preceding application of the Ilizarov external fixator both patients had undergone multiple conventional procedures over a period of two months causing disuse porosis of the whole limb. During surgery achievement of construct stability was aimed at. Post operatively the patients were put on an early physiotherapy regimen including range of motion of the adjacent joints and gait training.

Retrospective assessment shows that the weight of the fixator caused an inertia to develop through the swing phase, shortening and at times eliminating the deceleration phase. This caused a repetitive stress of the lower femoral region weakening it enough to allow the fixator weight to break it. Both the patients were not unduly concerned by the fracture attesting to the slowness of the process. Making an effort to reduce the construct weight, using carbon rings and judicious physiotherapy is recommended for paediatric patients with preceding disuse porosis, if the Ilizarov method is considered.

## **References**

1. Dahl M: The gradual correction of forearm deformities in multiple hereditary exostoses. *Hand Clin.* 9: 707-718; 1993.
2. Dendrinos GK, Kontos S, Lyrtsis E: Use of the Ilizarov technique for treatment of non union of the tibia associated with infection. *JBJS Vol-77-A* No 6 June 1995.
3. Desgrippes Y, Souchet P, Bensald H: Use of the Ilizarov external fixator in multioperated recurrent clubfoot. *J Pediatr Orthop 1B*: 181,1992.
4. G A Ilizarov. Clinical application of the tension stress effect for limb lengthening. *CORR Number 250* Jan 1990 8-26.
5. Ilizarov G. Treatment of diseases and injuries of the hand. In Ilizarov GA, Green SA[eds] : *Transosseous osteosynthesis*. Berlin, Springer Verlag, 1992, p 639-670.
6. James Aronson, Eric Johnson and John H Harp. Local bone transportation for treatment of intercalary defects by the Ilizarov technique. *CORR Number 243* June: 71-79: 1989.
7. Jeremy WR Young, Harry Kovelman, Charles S Resnik, Dror Paley. Radiologic assessment of bones after Ilizarov Procedures. *Radiology* ; 177: 89-93: 1990.
8. Massimo Canuti in operative principles of Ilizarov.

Chapter 8 p82-83; 1991 Williams and Wilkins.

9. Meyer S, Weiland AJ and Willenger H. The treatment of infected non union of fractures of long bones. Study of 64 cases with a five to twenty one year follow up. JBJS. 57-A; 836-842; Sept 1975.

10. Michael O Williams. Long term cost comparison of Major limb salvage using the Ilizarov method versus amputation. CORR N 301 p156-158; 1994.

11. Nicholas Rajacich, Deborah F Bell, Peter F Armstrong. Pediatric applications of the Ilizarov method. CORR No

280;p72-80; Jul 1992.

12. Paley D. Biomechanics of the Ilizarov external fixator. In Bianchi Maiocchi A, Aronson J[Eds]; Operative principles of Ilizarov. Baltimore, Williams and Wilkins. 1991, p33-41.

13. Paley D, Catagni M, Argnani F et al. Treatment of congenital pseudoarthrosis of the tibia using the Ilizarov technique. Clin Orthop 280; 81-93, 1992.

14. Paley D. Problems, obstacles and complications of limb lengthening by the Ilizarov technique. Clin Orthop; 260; 81-104; 1990.

**Author Information**

**Shabir Ahmed Dhar, M.S.**

Bone And Joint Surgery Hospital

**Mohammed Ramzan Mir, M.S.**

Bone And Joint Surgery Hospital