

Safety of Electronic Home Monitoring Devices in the Operating Room

Y Sarpong, A Dagal, S Sharar, A Avellino

Citation

Y Sarpong, A Dagal, S Sharar, A Avellino. *Safety of Electronic Home Monitoring Devices in the Operating Room*. The Internet Journal of Anesthesiology. 2010 Volume 29 Number 1.

Abstract

Due to increasing financial burden on the penal systems to keep offenders in the prisons, there have been increasing uses of electronic home monitoring devices to place "less risky" offenders under house arrest. These devices on several occasions have malfunctioned and caused electrical harm to wearers in cases of power surges and lightning strikes. Due to its relative novelty, there is no consensus or guidelines in the literature on how to manage patients with electronic home monitoring devices in surgical cases using monopolar electrocautery which can deliver charges that could potentially cause harm or malfunction of the monitoring system. Recently, we encountered a patient who needed bilateral cranioplasty procedures but had been placed on house arrest unbeknownst to us. During the surgery, we packed several gauzes in between the patient and the device and placed the electrocautery pad on the contralateral leg with power set at 20 MHz. The surgery was performed without any adverse outcome and the patient did well after surgery.

INTRODUCTION

Electronic home monitoring devices are tools used in the penal system to place an offender under house arrest. The device has two parts: one part is the familiar ankle bracelet that offender must wear at all times, and second part is a receiver that syncs with the ankle bracelet and reports through a telephone line to a monitoring station. The device has a limited range of distance from the home phone lines (about 100-150 feet) and if an offender goes out of this range it reports back to the monitoring station.¹ However, the range can be modified to allow offenders to attend functions such as school, work, or perform functions deemed necessary in the rehabilitation of the offenders. The device cannot be temporarily disconnected and has to be completely removed and thrown away. However, if the device is ever tampered with in such a way without law enforcement approval, the monitoring station is alerted and the police can take appropriate actions. Additionally, there are several reports that suggest that these devices can malfunction during lightning strikes, power surges, and when placed in metal-clad mobile homes or cast iron bathtubs.²

Conversely, monopolar electrocautery (i.e., bovie electrocautery) is a surgical instrument used to coagulate blood vessels as well as to cut and ablate tissues during surgery, by the heating effect of an electric current passed

through them.³ A sine wave pattern is utilized for cutting and a pulsed sine wave pattern for coagulation. Machine generates alternating current with very high frequency (0.5-1 MHZ) that is applied to the body through a handheld electrode and the current travels back to the generator through an inactive electrode (grounding pad) attached to the patient.⁴ This makes the patient into an electrical circuit and the power allows the surgeon to dissect and coagulate at the same time. The position of the grounding pad also influences the direction of current flow through the patient. The longer the distance between the instrument tip and the grounding pad, the larger the generated electromagnetic field and the risk of electromagnetic interference (EMI). This electromagnetic circuit has been known to cause interference with other electrical equipment in the operating room such as monitoring equipments and implantable cardiac devices.⁵ Thus, when devices such as electronic home monitoring devices are exposed to monopolar electrocautery it can potentially cause the device to fail or cause bodily harm to the patient.⁶ Recently, we encountered a patient who presented unbeknownst to the surgery and anesthesia teams with an ankle bracelet to undergo surgery using monopolar electrocautery and in this case report we share our experience.

CASE PRESENTATION

This is a 29 year-old gentleman who was involved in a motor vehicle accident and was ejected from the sunroof of his car. At the scene patient's Glasgow Coma Scale (GCS) was 3T and he was transferred to our trauma center. Upon arrival in our emergency room, his head CT showed that he had a symptomatic right subdural and a left epidural hematoma (Figure 1). Thus, he was taken to the operating room for bilateral craniectomies and removal of subdural and epidural hematomas (Figure 1). After 4-6 weeks of inpatient recovery, the patient was discharged home after having made a full recovery (Glasgow Outcome Score 5).

After 7 months post accident, the patient was taken to the operating room for bilateral cranioplasty procedures to replace the patient's craniectomy bone sites (Figure 2). After intubation, it was noticed that the patient had an electronic home monitoring device on his left ankle. Fearing the potential interference of the monopolar electrocautery and the electronic home monitoring device, the grounding pad was placed on the contralateral thigh and 4 x 4 gauzes were placed between the skin and the device itself (figure 3). The monopolar electrocautery was set at a low frequency (20MHz) while the case was performed. During the case there was no injury to the patient or change in the patient's vital signs. Additionally, after the surgery no burn marks were seen around the patient's ankle and the patient did not have any trouble from the legal system.

Figure 1

Figure 1. Axial head CT showing bilateral craniectomies for evacuation of subdural and epidural hematomas.

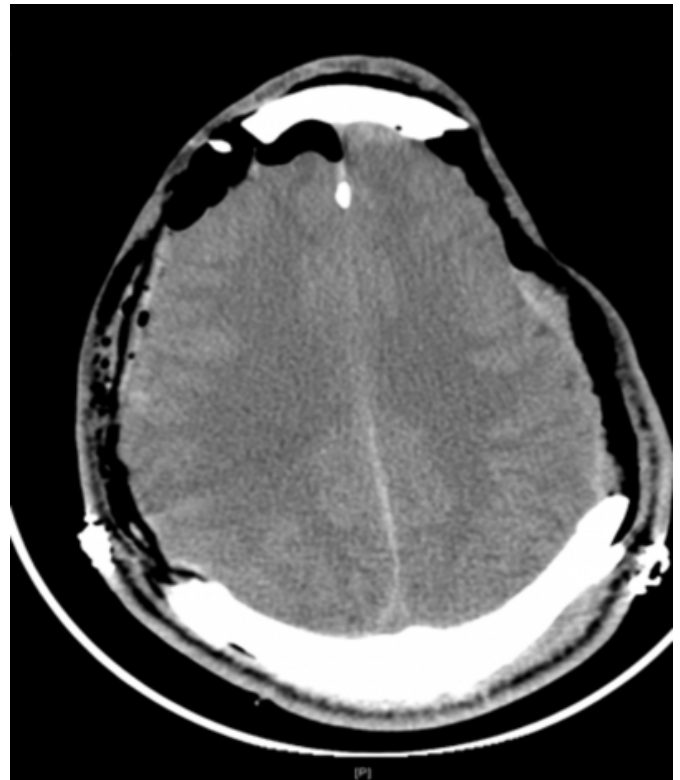

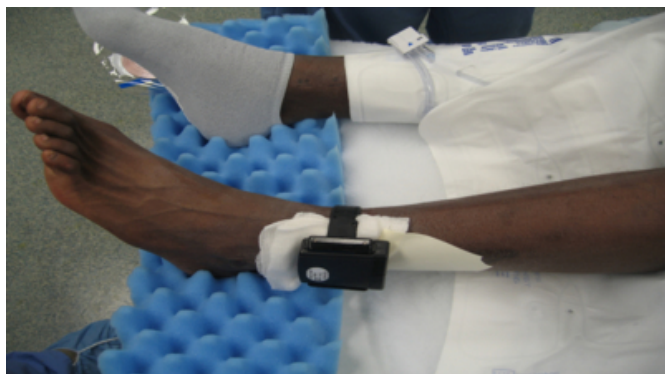
Figure 2

Figure 2. Axial head CT showing bilateral cranioplasty procedures.

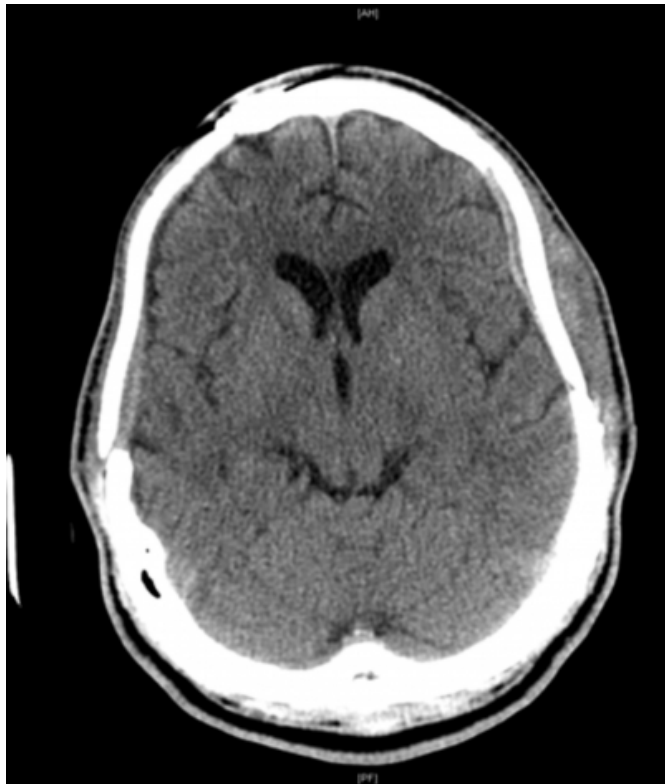

Figure 3

Figure 3. Patient's left ankle with the home monitoring device on the day of surgery for his bilateral cranioplasty procedures.



DISCUSSION

Due to progressive overcrowding of our jail systems, the criminal justice systems is moving towards the progressive use of home monitoring arrest device. These justice systems are choosing to place “less risky” offenders such as driving under influence (DUI) offenders, sex offenders, petty criminals, and first time juvenile offenders on this house monitoring arrest system.⁷ It is a sobering thought that there

have been reports that these devices can malfunction when exposed to electrical discharges such as the one caused by monopolar electrocautery, it is important for us to report our experience and offer further insight.

Law enforcement agencies indicate that the home monitoring device can be removed, a new one provided, the alarm system modified, and security provided for the wearer if they are given notice prior to the surgery date. However, there are no guidelines or consensus on how to manage a home monitoring device intraoperatively. Thus, if there is an emergent situation in which considerable physical or mental harm can befall the patient, the proper precautions can be taken as was done in this case which were (1) placement of grounding pad on contralateral thigh, (2) padding between the device and the ankle with 4 x 4 gauzes, and (3) setting the monopolar electrocautery at low frequency (20 MHz) which proved to be safe. Moreover, manufacturers of house monitoring arrest devices deny that such problems exist in their newer brands of house monitoring arrest device. However, the manufacturers provide no evidence concerning electrical discharges and their machines especially when sustained electrical discharges are applied to the body. In this case report we encountered a patient needing surgery wearing house monitoring arrest bracelet. We made modification and the patient did well during surgery without any harm to himself and consequently without any problems from the justice systems. On the contrary, this is one only reported case in the literature and we recommend more studies aiming at elucidating the problems we mentioned in this paper. However, we suggest that more coordination be established between the justice system and hospital systems concerning this special group of patients and their surgical needs as even though it was safe in our patient, it would be in the best interest of all to have had the home monitoring device removed prior and/or during surgery and then have it reapplied by the legal system after surgery.

References

1. Shamontiel. The Pros and Cons of House Arrest. Associated Content 2005.
2. Anderson D. Alternatives to Prison. New York; New Press 1998; 37-51.
3. Diamantis et al. Comparison of Monopolar Electrocoagulation, Bipolar Electrocoagulation, Ultracision, and Ligasure. Surgery Today 2006;36:908-913.
4. Schutt D et al. Sequential Activation of Ground Pads Reduces Skin Heating During Radiofrequency Tumor Ablation; In Vivo Porcine Results. IEEE Transactions on Biomedical Engineering 2010;57:746-753.
5. Dawes J et al. Electrosurgery in Patients with Pacemaker and Implanted Cardioverter Defibrillators. Ann of Plastic Surgery 2006; 57:33-36.

6. Bales J et al. Electrocautery-induced asystole in a scoliosis patient with a pacemaker. *Journal of Pediatric Orthopedics B* 2007; 16: 19-22.

7. Bierman N, Demarzon W. Crimes underscore risks of “house arrests” on electronic monitors. *High Beam Research* 2003

Author Information

Yaw Sarpong, M.D.

Resident, Department of Neurological Surgery, Harborview Medical Center

Armagan Dagal, MD FRCA

Assistant Professor, Department of Anesthesia and Pain Medicine, Harborview Medical Center

Sam R. Sharar, M.D.

Professor, Department of Anesthesia and Pain Medicine, Harborview Medical Center

Anthony M. Avellino, M.D., M.B.A.

Professor, Department of Neurological Surgery, Harborview Medical Center