

# Acquired Dextro-Position Of Heart: An Unexpected Finding In A Patient Presenting With Dyspnea

N Gourineni, V Pothula, A Tonelli

## Citation

N Gourineni, V Pothula, A Tonelli. *Acquired Dextro-Position Of Heart: An Unexpected Finding In A Patient Presenting With Dyspnea*. The Internet Journal of Internal Medicine. 2005 Volume 6 Number 1.

## Abstract

Cardiac dextro-position is defined as the presence of the heart in the right hemi thorax with normal alignment of the major axis of the heart. In true congenital dextrocardia the cardiac apex is pointed to the right and is formed by the left ventricle, however in dextro-position the left atrium and ventricle are located in the left side of the heart chambers. We report a rare case of acquired dextro-position secondary to left diaphragm hemi paresis presenting with severe dyspnea.

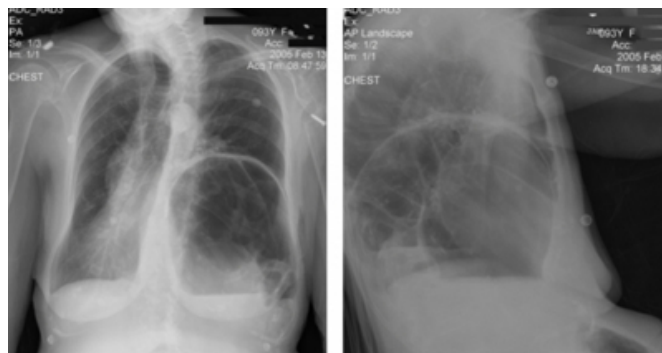
## CASE REPORT

A 93-year-old woman with long history of left hemi diaphragmatic paralysis possibly related to a blunt chest trauma was admitted after several days of progressive shortness of breath, abdominal distension, nausea and vomiting. Her surgical history included abdominal surgery for unclear reasons 10 years ago. Chest examination showed decreased breath sounds and gurgling sounds with tympanic percussion at the left lung base. Abdominal examination revealed distension with hyperactive bowel sounds.

Abdominal X-ray findings were consistent with small bowel obstruction. The patient underwent exploratory laparotomy with lysis of adhesions. Interestingly chest X-ray showed marked elevation of left hemidiaphragm with colon underneath with associated right sided displacement of the heart. The EKG showed decrement of the R wave voltage throughout the precordial leads. Chest CT and echocardiogram showed normally positioned cardiac chambers but displaced to the right side of the chest.

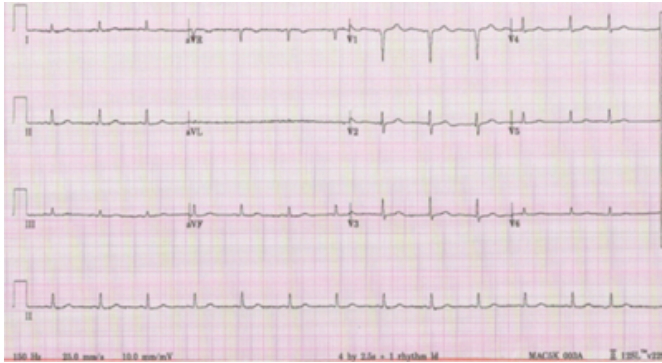
## Figure 1

Figure 1: Chest X-Ray evidencing a large left diaphragmatic herniation with right side heart displacement. The trachea is also lateralized to the same side. The aortic knob is located in the left side of the chest.



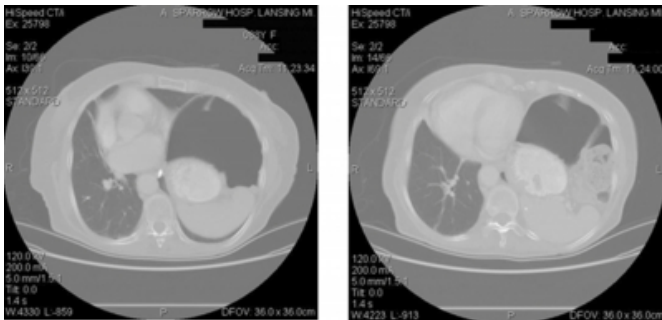
**Figure 2**

Figure 2: Electrocardiogram showing normal sinus rhythm and decremental loss of voltage from V3 to V6. The q wave in V2 and V3 can be explained by the direction of the first vector of depolarization. The higher R voltage in V3 and the subsequent decrement is explained by the orientation of the second voltage of depolarization. P waves are positive in lead DI.



**Figure 3**

Figure 3: Computer tomography at the level of the chest, involving the right (RV) and left (LV) ventricles. A large diaphragmatic hernia is seen to the left (L) of the heart, displacing it to the right (R) side of the chest.



## DISCUSSION

Dextro-position of heart can be congenital and acquired. Congenital dextroposition of heart associated with other cardiopulmonary anomalies constitutes scimitar syndrome or hypoplastic lung syndrome, pneumomediastinum in newborn (2), hypoplasia of right lung (3). Acquired dextroposition of heart is seen in post pneumonectomy patients is due to multiple factors : 1) Obliteration of the post pneumonectomy space which depends on both reabsorption and organization of the fluid it contains, 2) The diameter depends on the folding of the collapsed subcostal and mediastinal pleura, 3) The collapse of pleura depends on retraction of the intercostal space, elevation of the

diaphragm, and hyper expansion of the non-operated lung. The latter is the most important and manifests as mediastinal shift, which occurs though either rotation or transfer (4). The probable explanation of dextro-position in our case could most probably be due to elevation of hemidiaphragm with retraction of intercostals spaces causing collapse of pleura and mediastinal shift. Treatment of dextroposition of heart is symptomatic. Most patients with scimitar syndrome can be treated non- operatively (5,6). In some cases surgical correction of abnormality by anastomosis of anomalous vein to the left atrium could be considered (5,7,8). We treated our patient symptomatically.

## CONCLUSION

Cardiac dextroposition is defined as simple horizontal displacement of heart to the right side of the chest, most commonly secondary to mechanical causes. Acquired dextro position of heart is seen most commonly in post-pneumonectomy patients. A severe left hemi diaphragmatic paralysis as a cause for right heart displacement and dyspnea is remarkably rare. This last symptom was aggravated by the more pronounced left diaphragmatic elevation secondary to the small bowel obstruction. The physical exam and complementary studies confirmed the diagnosis.

## References

1. Snider AR. General echocardiographic approach to the adult with suspected congenital heart disease. Otto C. The practice of clinical echocardiography. Philadelphia: Saunders; 2002. p. 850-851.
2. . Franken EA Jr. Pneumomediastinum in newborn with associated dextroposition of the heart. Am J Roentgenol radium Ther Nucl Med 1970 Jun;109(2):252-60.
3. Abdullah MM, Lacro RV, Smallhorn J, et al. foetal cardiac dextroposition in absence of an intrathoracic mass: sign of significant right lung hypoplasia. J Ultrasound Med. 2000 Oct;19(10):669-76.
4. Biondetti PR, Fiore D, Sartori F, Colognato A, Ravasini R, Romani S. Evaluation of post-pneumonectomy space by computed tomography. J Comput Assist Tomogr. 1982; 6:238-242.
5. Folger GM. The scimitar syndrome: anatomic ,physiologic,developmental and therapeutic considerations. Angiology 1976; 27:373-407.
6. Fraser RG, Pare PJ, pulmonary abnormalities of developmental origin In :Fraser PG ,Pare PJ, eds. Diagnosis of the chest. Fraser RG, Pare PJ. Philadelphia,1977; 602-656.
7. Murphy JW, Kerr AR, Kirklin JW. Intracardiac repair for anomalous pulmonary venous connection of right lung to inferior vena cava. Ann Thorac Surg 1971;11:38-42.
8. Risch F, Hahn C. The technique of surgical correction of anomalies of the pulmonary veins in series of 25 cases Thorax 1958;13:251-260.

**Author Information**

**Nandu Gourineni, M.D.**

Department of Medicine, Michigan State University

**Vijayasimha R. Pothula, M.D.**

Department of Medicine, Michigan State University

**Adriano Tonelli, M.D.**

Department of Medicine, Michigan State University