

Results of Modified Proximal Femoral Nail in Peritrochanteric Fractures in adults

P Kamboj, R Siwach, Z Kundu, S Sangwan, P Walecha, R Singh

Citation

P Kamboj, R Siwach, Z Kundu, S Sangwan, P Walecha, R Singh. *Results of Modified Proximal Femoral Nail in Peritrochanteric Fractures in adults*. The Internet Journal of Orthopedic Surgery. 2006 Volume 6 Number 2.

Abstract

Background: In management of peritrochanteric fractures, design or technical problems have been identified with all devices, especially in managing unstable, comminuted fractures. Dynamic hip screw (DHS) superceded the earlier implants such as Jewett nail plate, but failure of fixation with DHS can still occur in up to 20% of cases. An intramedullary device has some theoretical advantages over extramedullary devices.

Methods: The present study comprised of 30 skeletally mature patients, in which proximal femoral nailing (PFN) was done for peritrochanteric fractures, admitted during the years 2001- 2003. Due to narrow diameter of femoral necks of Indian patients we modified the diameter of proximal part from 17mm to 14mm and that of neck screw from 11mm to 7.5mm.

Results: Critical analysis of the results of this series of proximal femoral nailing was done both anatomically and functionally according to the criteria laid by Frew and Murray. We achieved excellent results in 15 cases, good in 9, fair in 3 and poor in 3 cases. Incidence of screw cutout, penetration into joint, varus was very less in PFN as compared to DHS. All patients were followed up for a minimum of 2 years.

Conclusion: We conclude that proximal femoral nail is the implant of choice for subtrochanteric fractures and its use in unstable trochanteric fractures is very encouraging.

Level of Evidence: Level IV (Case series)

INTRODUCTION

Hip fractures are among the most devastating injuries in the elderly. Epidemiological studies have suggested that the incidence of fractures of proximal femur is increasing, not unexpectedly, since the general life expectancy of the population has increased significantly during past few decades. These fractures are associated with substantial morbidity and mortality; approximately 15% to 20% of patients die within one year of fracture. Trochanteric fractures are more common in women than in men by a margin of 3 to 1. Subtrochanteric fractures, which account for 10% of proximal femoral fractures, have a bimodal distribution pattern, appearing commonly in patients 20 to 40 years of age and in those over 60 years of age. A trivial fall or a sudden twist can cause a trochanteric fracture in elderly while in younger patients it usually results from high energy trauma. Intertrochanteric fractures usually unite if

reduction and fixation are adequate, and late complications are infrequent. Subtrochanteric fractures are associated with high rates of nonunion and implant fatigue failure because of the high stresses in this region.¹

Operative treatment, which allows early rehabilitation and offers the patient the best chance for functional recovery, is the treatment of choice for virtually all trochanteric fractures.²

Dynamic hip screw (DHS) has been the major implant for fixation of these fractures in the last two decades, but it has its own problems of cutting through, screw giving away from shaft, implant failure and penetration of the joint by the screw and the rate of fixation failure can go as high as 20%.^{1,3-6} So intramedullary devices (Ender nail, Gamma nail PFN) with the main advantage of being near to the weight bearing axis have taken over as the modality for fixation of these fractures.

MATERIALS AND METHODS

The present study comprised of 30 skeletally mature patients of trochanteric fractures admitted in Department of Orthopaedics, at our institute during the years 2001- 2003.

All these patients were subjected to detailed history to ascertain age, sex, menopausal status, mechanism of injury, related injuries, pre-injury ambulatory status, and pre-existing local and systemic conditions that may affect recovery. Full clinical examination was done to assess the general condition of the patient, condition of the neighboring joints, and any associated injuries. Radiographs were taken in two (antero-posterior and lateral) planes to assess the nature, type and personality of the fracture. Personality and type of fracture was studied in detail according to AO classification by examining the X-rays of the hip to be operated. The grade of osteoporosis was noted according to Singh's index of osteoporosis. Laboratory investigations were done as per requirement

Each patient was operated upon as early as possible (within two weeks) after getting fitness for anesthesia. Till the time of operation the patient was put on a skin/skeletal traction as needed.

IMPLANTS

The PFN was developed by AO/ASIF. It is available in two varieties, the standard and the long cannulated. The standard PFN consist of a 240 mm long nail. The distal part of the nail is available in 10, 11 or 12 mm diameter and its proximal part is 17mm in diameter. The angle between the two parts measures 6 degrees and is situated at 11 cm from the top of the nail. Two screws can be inserted through the proximal part, an 11 mm neck screw and a 6.5 mm anti-rotation screw. Distal locking can be static or dynamic. The tip of the nail is specially shaped to reduce stress concentration.

The long PFN comes in lengths of 340, 380 and 420 mm and is side specific. They are cannulated nails with diameter of distal part as 10mm.

MODIFICATION

Keeping in view the smaller diameters of the proximal femur in Indian population⁷ and recalling from the complications of shattering of proximal femora associated with the Gamma nail as reported by Leung et al, we modified some of the diameters of PFN to suit the smaller diameters of proximal femora of our population. We reduced the diameter of proximal part from 17 mm to 14 mm; also the diameter of

neck screw was decreased to 7mm from 11mm.

OPERATIVE PROCEDURE

The patient was positioned supine on the fracture table under spinal or general anesthesia as the condition of the patient permitted. The fracture was reduced by longitudinal traction and the limb was placed in neutral or slight adduction to facilitate nail insertion through the greater trochanter. A straight lateral incision was made from tip of the greater trochanter, extending 4-6 cm proximally; the gluteus maximus muscle was dissected in line with its fibers. Where open reduction was required we extended the incision distally, incising the iliotibial band in line with the skin incision. The entry portal for the PFN was made at the tip of the greater trochanter, halfway between its anterior and posterior extent. A Kirschner (K) wire was inserted at the tip of the greater trochanter under C-arm control. The K-wire is advanced into the femoral shaft in such a way that it is located in the middle of the shaft in both directions. In cases where standard PFN was used, we manually reamed the proximal part of the femur with a 14 mm reamer; while where long PFN was used we had to ream the distal femur also with increasing diameters of reamers up to 11 mm. After mounting the appropriate sized nail on the insertion device the nail was introduced manually into the femoral shaft. Via the aiming arm, which was attached to the insertion device, first the guide wire for the neck screw was introduced into the femoral neck in such a way that the screw was placed in lower half of the neck on the antero-posterior view and centrally on the lateral view. Thereafter, the guide pin for the antirotational hip pin was introduced. The hip pin was introduced first with the tip just about 25 mm medial to the fracture line, and then the neck screw of appropriate size was inserted. Afterwards depending on the type of fracture, distal interlocking either statically or dynamically was achieved via the same aiming arm in standard PFN and with free hand in long PFN. The stability of the construct was assessed and wounds were closed in layers over negative suction drain. Antiseptic dressing was done. Per-operatively one dose of antibiotic was also administered.

RESULTS

Thirty cases of trochanteric fractures were included in the study. The average age was 56.93 years ranging from 20-85 years. There were 17 females and 13 males and maximum (14 patients) were leading a sedentary life style. Out of 30, sixteen patients sustained injury due to fall at home, 8 met with road traffic accidents and 6 cases were pathological

fractures. 16 patients had AO type 31-A3 fracture. Bone stock was good to very good in 14 cases according to the Singh's index.

Most of the patients were operated between 8-14 days after injury though one patient with pathological fracture who presented after 1½ years of fracture was operated late. Closed reduction was tried in all cases and achieved in 17 patients, in the rest of 13 cases fracture had to be opened. Standard PFN was used in 18 cases and long in the rest of 12 cases as the fracture in those cases was extending in the diaphysis. Nail of diameter 10 mm was used in 21 cases which indicate that the canal diameter in Indian patients is quite low. Due to smaller diameter of neck of Indian femora we were not able to pass antirotational hip pin in 4 patients. The average time required for surgery was 89 minutes with a range between 45-210 minutes. In 19 cases one unit of blood was transfused. In one case with trochanteric fracture extending into the diaphysis encirclage wiring to hold the reduced fracture fragments was done. The average hospital stay was 12.90 days. Protected weight bearing either with a walker or crutches was allowed on an average 11.8 days after nailing. Three patients, one with intraoperative fracture shaft femur, one with contra lateral fracture shaft femur, and one with contra lateral fracture both bone leg were allowed to bear weight after 6 weeks. Unprotected full weight bearing was started when radiological evidence of union was seen; average time for radiological union was 13.9 weeks. 24 patients achieved full painless movements at hip and knee 4 had some restriction in movements at the time of final follow up. 5 patients had slight pain on activities rest 25 had no pain. In our study out of 30 patients 3 were using stick for walking before the injury. Postoperatively 6 used a stick and 2 were walking with help of a walker.

Critical analysis of the results of this series of proximal femoral nailing was done both anatomically and functionally (Fig. 1,2,3) according to the criterias laid by Frew and Murray.

Figure 1

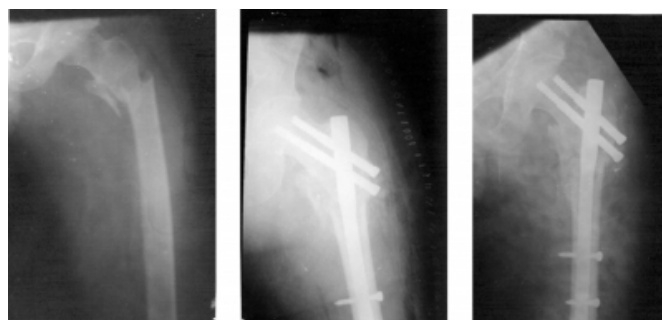


Figure 1 (a) Preoperative x-rays of a patient having unstable intertrochanteric fracture.

Figure 1 (b) Immediate post-operative x-ray.

Figure 1 (c) Follow up x-ray showing good consolidation.

Figure 2



Figure 2 (a) Patient (whose x-rays are shown in figure 1) squatting

Figure 2 (b) Same patient sitting cross legged

Figure 3

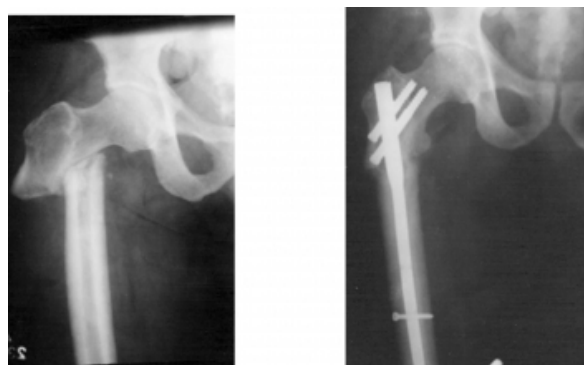


Figure 3 (a) Preoperative x-rays of non united Subtrochanteric fracture

Figure 3 (b) Follow up X-ray showing good consolidation

Following results were achieved as shown in the table 1.

Figure 4

Table 1: Showing anatomical and functional results

Results	Anatomical		Functional	
	No. of cases	Percentage	No. of cases	Percentage
Excellent	14	48.27	15	51.73
Good	8	27.59	9	31.03
Fair	3	10.34	2	06.90
poor	4	13.80	3	10.34

The most common complication in our study was poor placement of screws which occurred in 3 cases. These were the cases done in the beginning of the study and once the learning curve was achieved this complication did not occur. The other complications encountered were as shown in table 2.

Figure 5

Table 2: Complications

General complications	No of cases.
1. Decubitus ulcer	1
2. Urinary tract infection	1
3. Chest infection	1
4. Deep vein thrombosis	1
Local complications	Case No.
1. Iatrogenic fracture	1
2. Hematoma	2
3. Superficial infection	1
4. Disproportionate screw length	1
5. Poor placement of screws	3
6. Loss of reduction	2
7. Cut out of the implant	1
8. Secondary varus	2
9. Shortening < 2 cm	2
10. Heterotrophic calcification	1
11. Delayed union	2
12. Non union	1

DISCUSSION

Fractures involving the peritrochanteric region of the femur occur most frequently and are perhaps the most commonly stabilized fractures in orthopaedic surgery.^{8, 9}

Every trochanteric fracture must be assessed individually and it will be irrational to establish fixed routines of treatment. Numerous difficulties may arise in the management of unstable intertrochanteric fractures because (1) Proximal femoral fractures tend to occur in very elderly

and debilitated, resulting in a relatively high rate of complications. (2) Degree of osteoporosis. (3) Reverse obliquity of the fracture line. (4) Comminution on the medial side / stability of the fracture. (5) The occasional limitation of movements at hip or knee due to stiffness.

It is because of these difficulties that have given rise to so much controversy among surgeons as to the best method of managing proximal femoral fractures. Various modalities of treatment exist. The conservative mode has gone into disrepute due to the complications associated with it, leaving only few indications for its use, like an elderly patient whose medical condition carries an excessively high risk of mortality from anesthesia and surgery, or non-ambulatory patient who has minimal discomfort following fracture. Operative management consisting of fracture reduction and stabilization, which permits early patient mobilization and minimizes many of complications of bed rest, has consequently become the treatment of choice for trochanteric fractures.^{1, 2, 9, 10-12}

Numerous implants are available both intramedullary and extramedullary and excellent results have been reported with all. One of the implants used for fixation of trochanteric fractures is proximal femoral nail. PFN is designed to overcome some of the difficulties encountered with earlier designs of intramedullary implants meant for stabilization of proximal femoral fractures. It provides stable internal fixation with biomechanical advantage of a shorter lever arm, which is more stable under loading. The anti-rotation screw prevents the rotational element of the proximal fracture fragment; fluting the nail tip decreases the stress at the distal end and positioning the distal locking bolts more proximal than in other devices avoided the abrupt changes in stiffness of the construct thus decreasing the incidences of distal femoral fractures reported with the use of other similar devices.¹²⁻¹⁴

The indications of PFN are enormous ranging from extra capsular femoral fractures to the distal third femoral fractures.

The optimum outcome of treatment of any fracture depends upon (1) Anatomical reduction. (2) Stable internal fixation. (3) Preservation of the blood supply to the bone fragments and the soft tissues by means of atraumatic surgical technique. (4) Early active pain free mobilization of muscles and joints, adjacent to the fracture, preventing the development of the fracture disease. (5) Good wound healing. PFN fulfills most of the above mentioned criterias

It is clear from the above study that proximal femoral nailing have low infection rate as it avoids the long incision necessary for a long plate hip screw device, provides excellent functional results, early mobility and weight bearing allowing the old patients out of bed early thus preventing the complications of recumbency, has low incidence of femoral shaft fracture at the tip of the implant as compared to other intramedullary implants, low non union / delayed union rates.

We conclude that proximal femoral nail is an attractive implant for subtrochanteric fractures and its use in unstable trochanteric fractures is very encouraging. This study has shown that this device can be safely used by the average surgeon in the average hospital to treat common and sometimes difficult fractures.

CORRESPONDENCE TO

Dr. Pradeep Kamboj 11-Couples Hostel, Medical Campus,
Pt. B.D. Sharma PGIMS, Rohtak Haryana-124001
Telephone- +919992014147 Email: kambojdr@gmail.com

References

1. Guyton JL. Fractures of hip, Acetabulum and Pelvis. Canale ST, editor. Campbell's Operative Orthopaedics. 9th ed. Mosby, St. Louis: 1998: p. 2181- 99.
2. Koval KJ, Zuderman JD. Intertrochanteric fractures. In: Bucholz RW, Heckman JD, editors. Rockwood and Green's fractures in adults. 5th ed. Philadelphia: Lippincott Williams and Wilkins 2001: p. 1635-63.
3. Butt MS, Krikler SJ, Nafie S, Ali MS. Comparison of dynamic hip screw and gamma nail: a prospective, randomized, controlled trial. *Injury* 1995; 26: 615-18.
4. Ordway CB. Comparison of condylocephalic nail with sliding screw and side plate for intertrochanteric fractures of the hip. *J Bone Joint Surg (Orthop Trans)* 1982; 6: 339.
5. Nunn D . Sliding hip screws and medial displacement osteotomy. *J R Soc Med* 1988; 81(3): 140-42.
6. Simpson AH, Varty K, Dodd CA. Sliding hip screws: modes of failure. *Injury* 1989; 20: 227-31.
7. Siwach R C, Dahiya S. Anthropometric study of upper end of femur. Silver jubilee oration Indian Orthopaedics Association Con 2003 Patna.
8. Lindsey RW, Teal P, Probe RA, Rhoads D, Davenport S, Schauder K. Early experience with the Gamma interlocking nail for peritrochanteric fractures of the proximal femur. *J Trauma* 1991; 31(12): 1649-58.
9. Haidukewych G, Israel A, Berry D. Reverse obliquity fractures of the intertrochanteric region of the femur. *J Bone Joint Surg Am.* 2001; 83A: 643-50.
10. Davic TRC, Sher, Horsman A, Simpsen M, Porter BB, Clecketts RG. Intertrochanteric femoral fractures: mechanical failure after internal fixation. *J Bone Joint Surg* 1990; 72: 26-31.
11. Harris LJ. Closed retrograde intramedullary nailing of peritrochanteric fractures of femur with a new nail. *J Bone Joint Surg* 1980; 62: 1185-93.
12. Al-yassari G, Langstaff RJ, Jones JWM, Al-Lami M. The AO/ASIF proximal femoral nail (PFN) for the treatment of unstable trochanteric femoral fracture. *Injury* 2002; 33: 395-99.
13. Simmermacher RKJ, Bosch AM, Vander WC. The AO/ASIF proximal femoral nail (PFN): a new device for treatment of unstable proximal femoral fractures. *Injury* 1999; 30: 327-32.
14. Domingo LJ, Cecilia D, Herrera A, Resines C. Trochanteric fractures treated with a proximal femoral nail. *Int Orthop* 2001; 25: 298-301.

Author Information

P. Kamboj, MS

Assistant Professor, Department of Orthopaedics, Pt. B.D. Sharma PGIMS

R.C. Siwach, MS,DNB

Professor and Head, Department of Orthopaedics, Pt. B.D. Sharma PGIMS

Z. S. Kundu, MS, DNB

Reader, Department of Orthopaedics, Pt. B.D. Sharma PGIMS

S.S. Sangwan, MS, DNB

Professor and Director, Department of Orthopaedics, Pt. B.D. Sharma PGIMS

P. Walecha, MS

Assistant Professor, Department of Orthopaedics, Pt. B.D. Sharma PGIMS

R. Singh, MS

Assistant Professor, Department of Orthopaedics, Pt. B.D. Sharma PGIMS