

Simultaneous treatment of upward migrated DJ stent and proximal ureteral stones: A Case Report

? Kenan

Citation

? Kenan. *Simultaneous treatment of upward migrated DJ stent and proximal ureteral stones: A Case Report*. The Internet Journal of Urology. 2006 Volume 5 Number 1.

Abstract

Upward migration of DJ stent associated with proximal ureteral stones is a rare situation. A 41-year-old man who had upward migrated DJ stent and proximal ureteral stones is presented. Upward migrated DJ stent was removed by ureteroscopy and proximal ureteral stones were successfully fragmented by pneumatic lithotripter. Upward migrated DJ stent can be removed and proximal ureteral stones can be treated with minimally invasive endoscopic surgery at the same session.

INTRODUCTION

Upward migration of DJ stent is occasionally encountered in urologic practice^[1]. Ureteroscopy is usually used to remove upward migrated DJ stent^[2,3]. However, DJ stent can be complicated by encrustation, stone formation. The management of these complications remains a challenging task. Generally, a combined approach of percutaneous nephrolithotomy or extracorporeal shock wave lithotripsy (SWL) with ureteroscopy, intracorporeal lithotripsy can be used to remove them. If the endourologic procedure fails, open surgery should be used to extract the stents^[1,4,5]. Herein, the author reports the use of minimal invasive treatment in a patient who had upward migrated DJ stent and proximal ureteral stones.

CASE REPORT

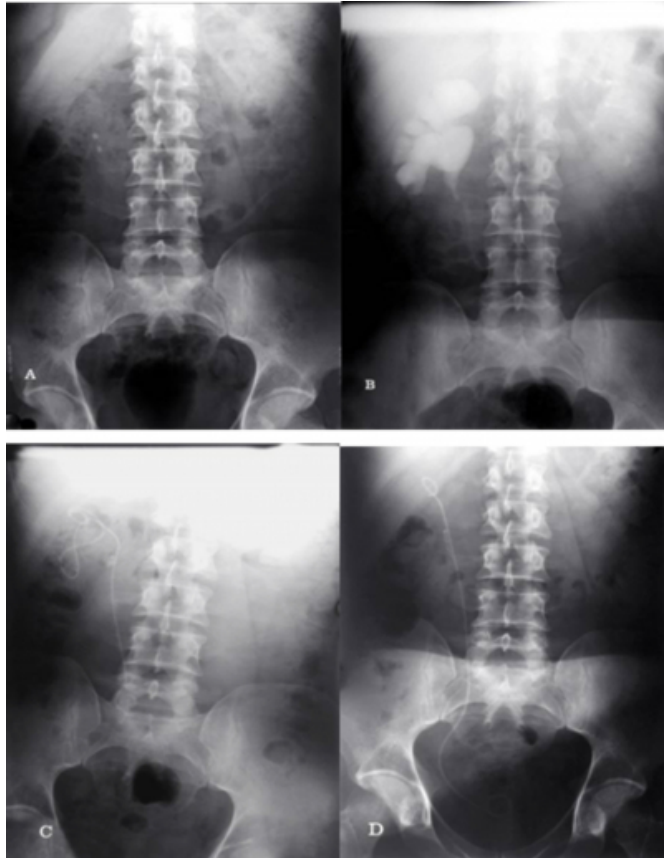A 41-year-old man presented with right flank pain, haematuria, dysuria and pollacuria. Before referred to our hospital, DJ stent had been placed to drain the right kidney one month ago and SWL had been performed on the right side proximal ureteral stones twice. Physical examination revealed slight tenderness on the right flank region. Laboratory studies including blood count, blood chemistry were normal. Urine samples showed microscopic haematuria and pyuria; however, urine culture yielded no significant colonization. Proximal ureteral stones had been diagnosed at plain abdominal x-ray on the right-sided urinary system and intravenous urography (IVU) also had revealed grade IV hydronephrosis on the same side before SWL and DJ stent placement (Fig.1A,B). Upward migrated DJ stent was determined on plain abdominal x-ray on the right-sided

urinary system (Fig.1C).

Ureteroscopic management was planned. Under general anaesthesia, 8/9.8 Fr Wolf semirigid ureteroscope was inserted into bladder. A 5 F ureteral catheter was placed prior to insertion of the ureteroscope. After insertion of the ureteroscope the ureteral catheter was removed. Upward migrated DJ stent was removed by the grasping forceps successfully. After identification of the stone, pneumatic lithotripsy was performed and successful fragmentation was achieved without any complications. A new 5F DJ stent was inserted. The operative time was less than 45 minutes. Successful fragmentation was demonstrated on post-operative first day plain abdominal x-ray (Fig.1D).

Figure 1

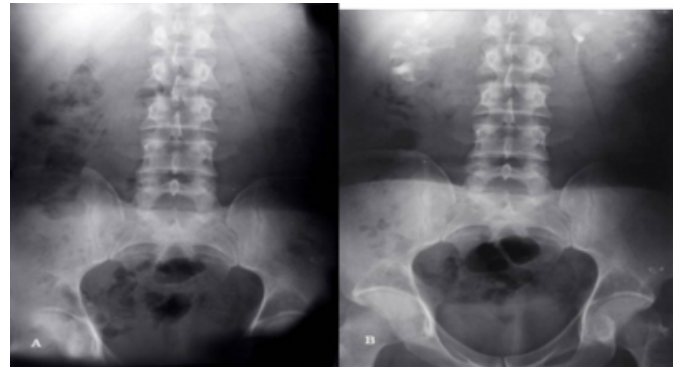
Figure 1 AB: Plain abdominal x-ray and IVU are showing proximal ureteral stones and grade IV hydronephrosis on the right-sided urinary system. C: Plain abdominal x-ray is demonstrating upward migrated DJ stent on the same side. D: Post-operative first day plain abdominal x-ray is showing successful fragmentation (stone-street).



The patient was discharged post-operative first day. The patient received intravenous first generation cephalosporin preoperatively, which was maintained 7 days an oral quinolone. The DJ stent was removed by cystoscopy under local anaesthesia two weeks after the treatment. An IVU was obtained after the withdrawal of the DJ stent on the third week and it showed complete stone clearance except mild dilatation on the right-sided urinary system (Fig.2A,B).

Figure 2

Figure 2 AB: Post-operative plain abdominal x-ray and IVU are demonstrating complete stone clearance except mild dilatation on the right-sided urinary system.



DISCUSSION

Upward migration is one of the major complication of the DJ stents. The incidence of upward migration has been reported 0.6-3.5%^[1,6]. The etiology of upward migration of DJ stent is multifactorial, resulting from short stent, duration of stent, the angle of distal part of stent <180 degrees, placement of stent in upper pole instead of pelvis^[1,7]. This patient had grade IV hydronephrosis and it seems to be a risk factor for upward migration of the stent.

The standard clinical approach to management of upward migrated stent is ureteroscopic removal. The other treatment modalities are the use of a Fogarty catheter, ureteric balloon dilators, stone basket and forceps^[3,7]. If the stent is encrusted or stone formation is developed; multiple endourological approaches, including SWL, ureteroscopic lithotripsy, percutaneous cystolithotomy and percutaneous nephrolithotomy are always needed for rendering patients stone-free and stent free^[3,4,5,7]. If the endourologic procedure fails, open surgery should be used to extract the stents. Eghazarian et al^[8] were the first to introduce ureteroscopy using intracorporeal lithotripsy with a Lithoclast as an effective method for treating a calcified stent. Singh et al^[9] have suggested a protocol for managing heavily encrusted and jammed stents. When the stone burden is mild or moderate, ESWL and traction can be used initially. If the stone burden is severe, ureteroscopy with intra-corporeal lithotripsy is a possibility. If the affected renal unit is nonfunctional or less than 10% functional, a nephrectomy should be considered.

In this case, SWL had been performed however, sufficient fragmentation had not been achieved. Ureteroscopy was performed due to upward migrated stent together with

proximal ureteral stones. The upward migrated stent was removed and ureteroscopic lithotripsy was performed successfully at the same session without any complication.

CONCLUSIONS

Follow-up stented patients is valuable in early detection of upward migrated DJ stent. Upward migrated DJ stent can be removed and proximal ureteral stones can be treated with minimally invasive endoscopic surgery at the same session.

CORRESPONDENCE TO

Kenan ISEN Ofis cami sok. Ayyıldız Apt. Kat: 5 No:15
Diyarbakır TR-21100, TURKEY Tel: +90.532.6180293 E-mail: kenanisen@hotmail.com

References

1. Slaton JW, Kropp KA. Proximal ureteral stent migration: an avoidable complication? J Urol 1996; 155:58-61.
2. Tan MO, Yuceturk C, Uygur MC, et al. Case report: Further upward migration of a misplaced double-J ureteral stent. Int Urol Nephrol 2002; 34: 285-287.
3. Bagley DH, Huffmanval JL. Ureteroscopic retrieval of proximally located ureteral stents. Urology 1991; 37: 446-448.
4. Borboroglu PG, Kane CJ. Current management of severely encrusted ureteral stents with a large associated stone burden. J Urol 2000; 164: 648-650.
5. LeRoy AJ, Williams HJ, Segura JW, et al. Indwelling ureteral stents: Percutaneous management of complications. Radiology 1986; 158: 219-222.
6. El-Faqih SR, Shamsuddin AB, Chakrabarti A, et al. Polyurethane internal stents in treatment of stone patients: morbidity related to indwelling times. J Urol 1991; 146: 1487-1491.
7. Clin JL, Denstedt JD. Retrieval of proximally migrated ureteral stents. J Urol 1992; 148: 1205-1206.
8. Eghazarian C, Lechevallier B, Bredhean D, et al. An incrusted ureteral stent: use of a lithoclast. Prog Urol 1995; 5: 410-414.
9. Singh I, Gupta NP, Hemal AK, et al. Severely encrusted polyurethane ureteral stent: management and analysis of potential risk factors. Urology 2000; 58: 526-531.

Author Information

?sen Kenan, M.D.

Clinic of Urology, State Hospital of Diyarbakır