

# Spinal Anesthesia In A Patient With Kyphoscoliosis

M Saraswat, M Radhakrishnan

## Citation

M Saraswat, M Radhakrishnan. *Spinal Anesthesia In A Patient With Kyphoscoliosis*. The Internet Journal of Anesthesiology. 2001 Volume 6 Number 1.

## Abstract

Spinal anesthesia produces rapid, profound sensory analgesia using small volumes of drug without systemic pharmacologic effect. Spinal anesthesia is probably the most widely used regional technique in surgical patients. This procedure is usually withheld in cases of spinal deformities due to technical reasons. We report such a case with severe thoracolumbar kyphoscoliosis who was successfully given spinal anesthesia by Taylor's approach.

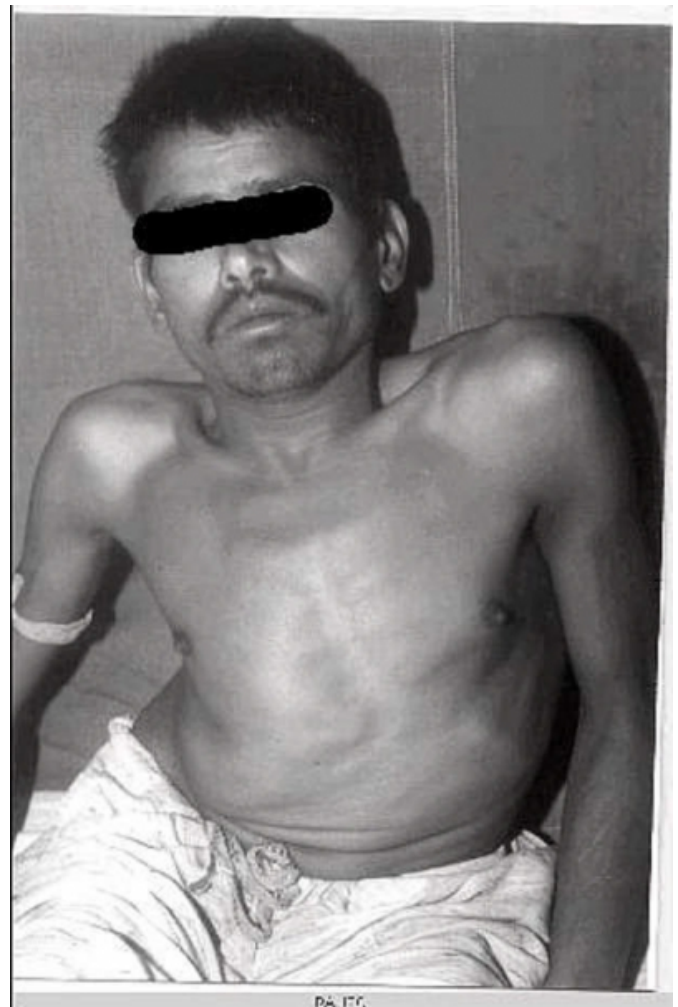## CASE REPORT

A 40-year old man presented to the Orthopaedics Department with infected stump following below knee amputation on the right side. He underwent bilateral below knee amputation 5 months ago, the details of which were not known. Debridement and revision of stump was planned.

The patient gave a history of breathing difficulty on moderate exertion for the last 2 years. History of deformity in the spine was present from his childhood. No other history relevant to the respiratory tract such as infections, bronchospasm, or cor pulmonale were present. On examination, his vitals signs were stable. His chest was clear and the mouth opening was adequate. He had severe kyphoscoliosis to the left and in the thoracolumbar region. (fig 1, fig.2)

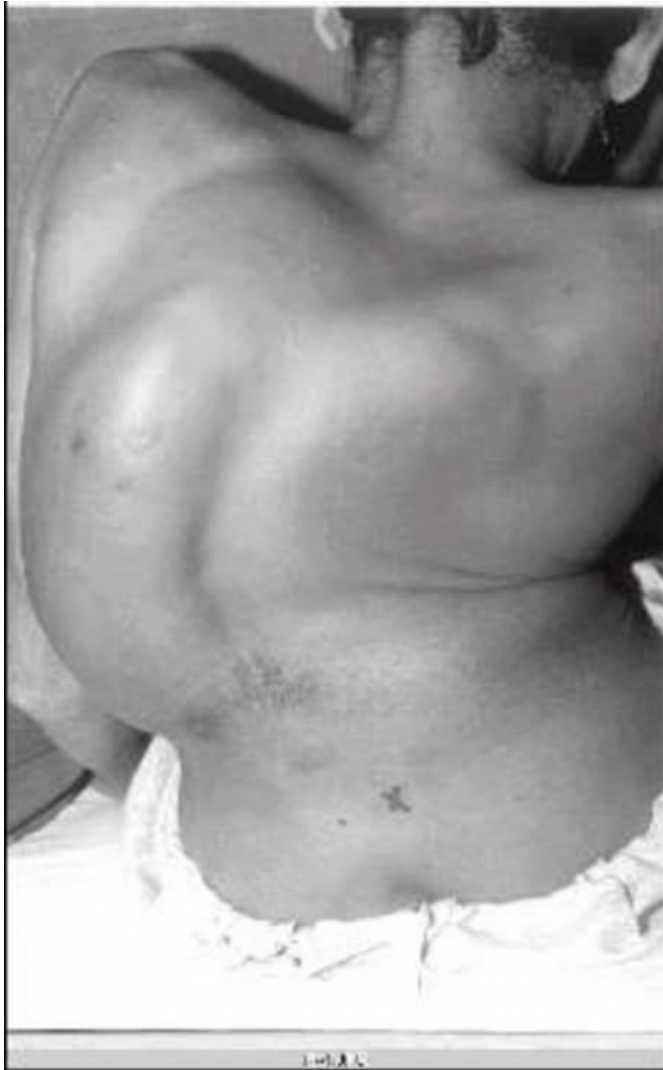## Figure 1

Figure 1: Kyphoscoliosis frontal view



**Figure 2**

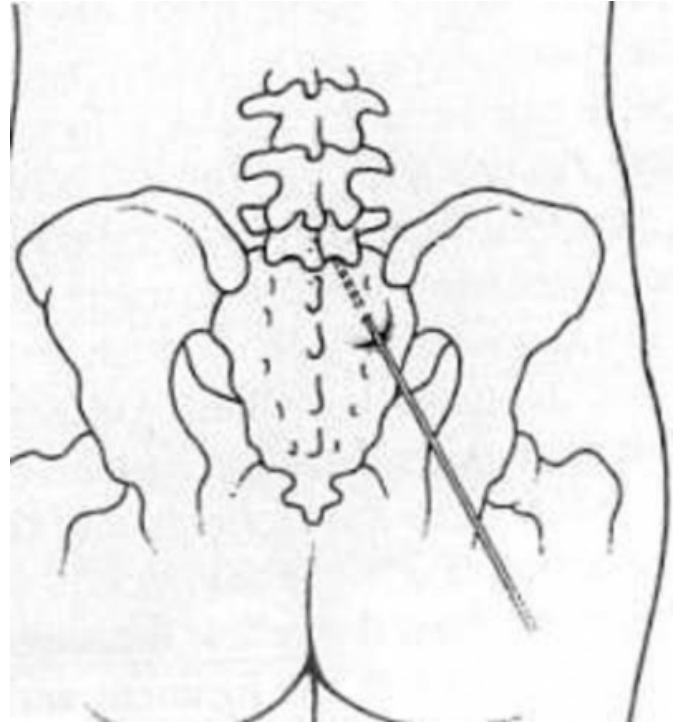
Figure 2: View from back



Injection of Glycopyrrolate 0.2mg was given as premedication. The patient was preloaded with 500ml of crystalloid. In the sitting position, the right posterior superior iliac spine (PSIS) was identified. A point 1cm below and medial to the PSIS was marked<sub>2</sub> (fig.3).

**Figure 3**

Figure 3: Direction of needle



Using a 23G Quincke type spinal needle, the site was entered in cephalomedial direction. Dural puncture was successful at the second attempt. After ensuring free flow and aspiration of cerebrospinal fluid, 60mg of 5% lidocaine (hyberbaric) was deposited into the subarachnoid space. The patient was then laid supine. No sedation was given. The sensory level of blockade was up to T<sub>10</sub> level. After 5 minutes, surgery started and lasted for an hour. Another 750 ml of crystalloid was given in the perioperative period. There were no breathing problems. No significant changes in pulse rate and blood pressure were noted.

## DISCUSSION

Kyphoscoliosis is one of the common causes for chronic extrinsic restrictive lung disease. In patients associated with respiratory problems, spinal anesthesia is an excellent option for lower extremity surgeries. But levels above T<sub>10</sub> may impair respiratory muscle activity.

A deformity of the vertebral column is considered a contraindication for spinal anesthesia because of technical reasons. This patient had no features suggestive of cor pulmonale. Due to spinal deformity, dural puncture was not tried at a lumbar level. General anesthesia was not chosen because of the possibility of worsening of respiratory function both intra and postoperatively. Therefore, lumbosacral (Taylor's) approach was chosen, as L<sub>5</sub>-S<sub>1</sub> is

widest in interlaminar space<sub>1</sub>.

There is a rare possibility that primary dorsolumbar scoliosis can produce structural secondary lumbosacral curve. This alters the relationship between PSIS & L5-S1 intervertebral space.

Depressant drugs were not used in view of the narrow margin of ventilatory reserve in this patients, as well as adverse effects on the pulmonary vascular resistance that would occur with respiratory acidosis from hypoventilation.

### **CONCLUSION**

In patients where a midline approach at the lumbar level is

difficult, the lumbosacral approach is an excellent alternative for providing spinal anesthesia to perineal and lower extremity surgery.

### **CORRESPONDENCE TO**

Radhakrishnan.M No:179,Periyarnagar, Rajagopalapuram, Pudukottai-622003 TamilNadu,India E-mail:mrks1974@yahoo.com

### **References**

1. David L.Brown.Spinal epidural and caudal anesthesia. Ed.Ronald D Miller:5th edn (vol:1).Anesthesia.Churchill livingstone,2000
2. TaylorJA. Lumbosacral subarachnoid tap. J Urol 1940;43:561

**Author Information**

**Manju Saraswat, MD, DA**

Professor and Head, Department of Anesthesiology, M.G.M. Medical College

**M Radhakrishnan, MB, BS**

Postgraduate Resident Trainee, Department of Anesthesiology, M.G.M. Medical College