

Extensive Recurrent Pleomorphic Adenoma Of The Cheek: A Treatment Dilemma

S Ashwani, D Sareen, A Agarwal, I Singh

Citation

S Ashwani, D Sareen, A Agarwal, I Singh. *Extensive Recurrent Pleomorphic Adenoma Of The Cheek: A Treatment Dilemma*. The Internet Journal of Otorhinolaryngology. 2004 Volume 3 Number 2.

Abstract

We present the case of a 60-year-old female presenting with an extensive pleomorphic adenoma of the left half of face. The patient had undergone two surgeries and received a curative dose of radiotherapy for the tumour in our institution over a span of 5 years preceding this presentation. The patient could not be offered a surgical treatment owing to the extensive nature of the tumour and remained a treatment dilemma. A brief review of literature is also mentioned.

INTRODUCTION

Pleomorphic adenoma is the most common tumour of salivary glands, which affects women more commonly than men and usually presents in middle age and beyond. It is a slow-growing, well-circumscribed tumour and removal can be curative. Primary tumours are usually unifocal and, therefore, reappearance of the disease after surgical excision is unlikely to represent a separate or new primary tumour. Although, such a disease is referred to as "recurrent", it is not an accurate term. Recurrence generally follows incomplete excision or spillage of tumour cells during removal. Also, there is a general agreement that once a pleomorphic adenoma has recurred, the likelihood of further recurrence increases. We present one such case with an extensive recurrence that was inoperable.

CASE REPORT

A 55-year-old female presented to us 5 years back with complaints of left-sided, gradually progressive, painless, non-tender facial swelling of 4 years duration. An F.N.A.C. revealed it to be a pleomorphic adenoma of the cheek. A CT-Scan showed it to involve the left cheek, infratemporal fossa and pterygopalatine fossa. The tumour was excised via a trans-maxillary approach using an extended Weber-Fergusson incision. The patient presented back 1 year after the surgery with recurrence (confirmed by biopsy). CT-Scan revealed the tumour to be involving and completely eroding the maxillary antrum with extension into the left pterygopalatine fossa. The tumour was widely excised using a trans-facial approach. The excision biopsy revealed no evidence of malignancy. The patient presented back to us 3

years following surgery with a recurrence again. The patient was treated with 48 Greys of radiation in divided doses over a period of 6 weeks with marked reduction in size of the tumour. The patient remained asymptomatic for about 1 year following radiotherapy, when she presented back with another recurrence.

On examination, a diffuse, soft to firm, non-tender swelling was seen extending from the lower eyelid above to the angle of mandible below and from the dorsum of nose medially to the temporal region laterally on the left side of face (FIGURE 1). Intranasally, an ulcero-proliferative pinkish mass arising from the lateral wall of left nasal cavity could be seen with no bleed on probing. The patient had trismus with an ulcero-proliferative mass involving bilateral hard and soft palate, left lower alveolus along with gingivo-buccal sulcus and left half of floor of mouth (FIGURE 2).

Figure 1

Figure 1: Showing extent of facial swelling.

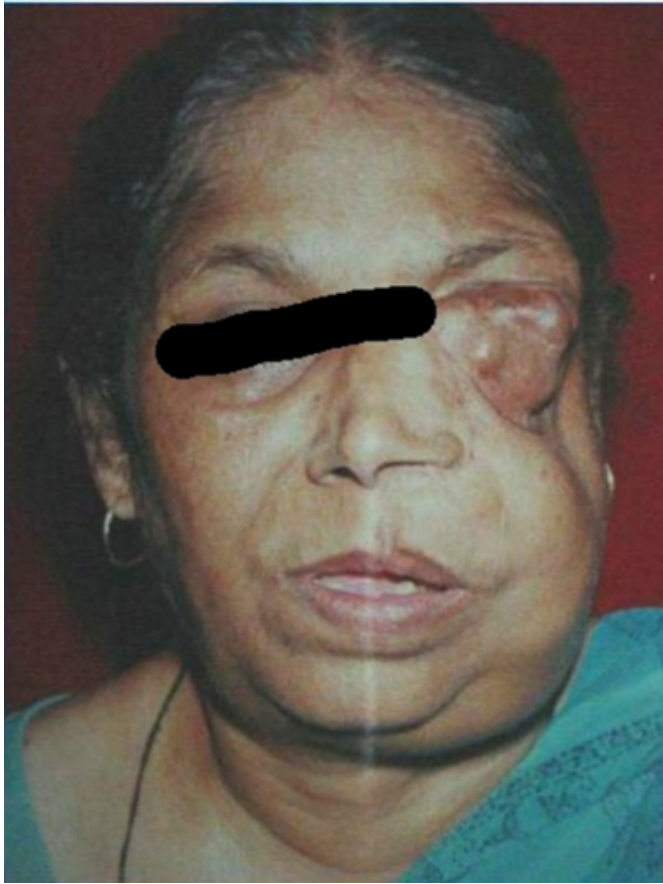
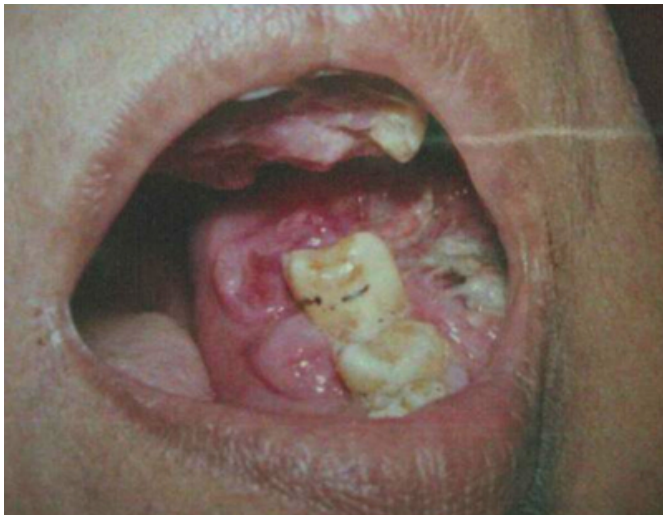
Figure 2

Figure 2: Showing the intraoral involvement by the tumour.



The biopsy revealed a pleomorphic adenoma. The MRI of the patient revealed a heterogeneously enhancing mass extending superiorly till the cribriform plate and greater wing of sphenoid, inferiorly till the floor of mouth, medially involving the left nasal cavity, laterally involving the

infratemporal fossa and masseteric space and posteriorly till the anterior wall of sphenoid sinus and the pterygopalatine fossa. The mass caused destruction of left hemimandible and pterygoid plates (FIGURES 3, 4 and 5).

Figure 3

Figure 3: Sagittal MRI-Scan- Showing superior and inferior extent of tumour mass (White Arrow).

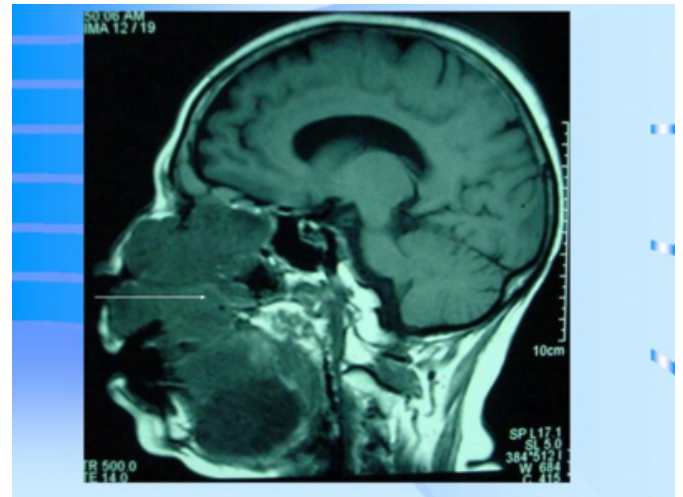


Figure 4

Figure 4: Axial MRI-Scan- Showing medial and lateral extent of tumour mass (White Arrow).

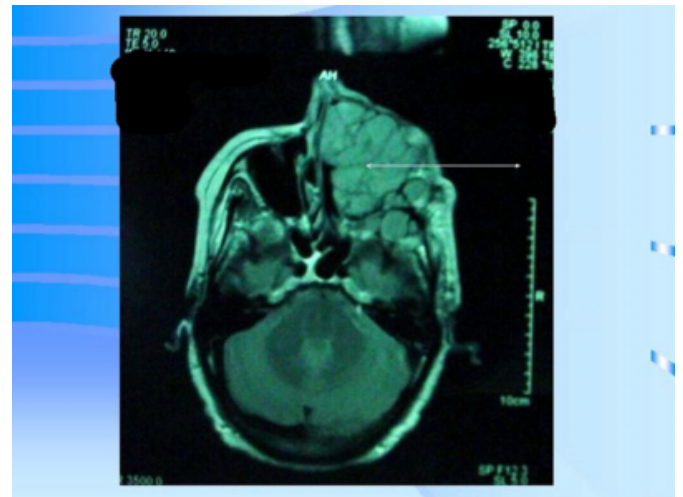
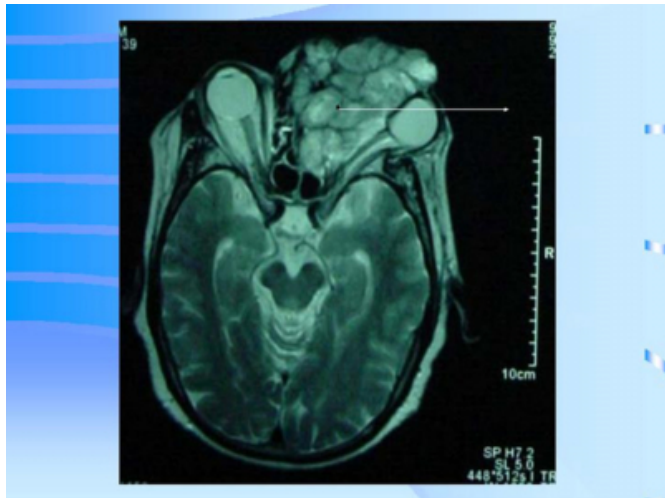


Figure 5

Figure 5: Axial MRI-Scan- Showing posterior and anterior extent of tumour mass (White Arrow).



Owing to the extensive spread of the tumour, the patient was not offered any treatment on this occasion.

DISCUSSION

The historical initial treatment of choice for pleomorphic adenomas was enucleation. This was because of an apparent capsule around the tumour. This has been associated with an unacceptable degree of recurrence and thus, it has been replaced by the surgical procedures that required the tumour to be excised with a cuff of surrounding normal tissue. However, whichever technique being used, recurrences still occur. The incidence of local recurrence is between 5-50% depending upon the type and adequacy of treatment.

Various factors have been implicated to have some predictive value in the causation of recurrence. The age of patient at the time of appearance of the tumour has been linked to the incidence of recurrence in some studies. The reported age of patients with recurrent adenomas ranges from 26.9 to 33.5 years. However, our case was a much older patient (55 years at the time of presentation). Multicentricity of the tumour has been postulated as an important cause of recurrence, but most of the later studies are against this concept. Some studies have also postulated the histological patterns of the primary tumour with tumours showing increased nodularity and a myxoid pattern being associated with a greater risk of recurrence. In spite of all these postulated factors, incomplete excision, and spillage of cells during excision remain the most important factors responsible for recurrence.

The management of a recurrent pleomorphic adenoma is not

easy. This is because a large number of such recurrent tumours have multicentric origin and many have bone-destroying capacity. The treatment options available for such recurrences are a wide surgical excision and/or radiotherapy. Use of radiation therapy as an adjuvant to surgery has been shown to decrease further recurrence rates. This was the reason why we subjected our patient to radiation therapy. Radiotherapy carries a small but definite risk of malignant transformation of the tumour. However, it was not apparent in our patient. In spite of wide surgical excisions and radiotherapy, our patient developed another recurrence, which was too extensive to be excised. With no treatment option left, the case remains a management dilemma.

CONCLUSION

Although benign in nature, recurrent pleomorphic adenoma is a difficult tumour to manage. The best chance of complete removal of the tumour is at the time of first surgery when the excision must be wide field. After an initial recurrence, the likelihood of further recurrences increases.

CORRESPONDENCE TO

Dr ASHWANI SETHI E-80, NARAINA VIHAR, New Delhi-110028 INDIA. Phone No: 91-11-9811338978 E mail: dr_sethi@rediffmail.com

References

1. Eveson JW and Cawson RA. Salivary gland tumours. A review of 2410 cases with particular reference to histological types, site, age and sex distribution. *J Pathol* 1985; 146: 51.
2. Patey DH and Thackrey AC. The treatment of parotid tumours in the light of a pathological study of parotidectomy material. *Br J Surg* 1958; 45: 477.
3. McGregor AD, Burgoyne M and Tan KC. Recurrent pleomorphic salivary adenoma-the relevance of age at first presentation. *Br J Plast Surg* 1988; 41: 177-181.
4. Jackson SR, Roland NJ, Clarke RW and Jones AS. Recurrent pleomorphic adenoma. *J Laryngol Otol* 1993; 107: 546-549.
5. Gleave EN, Whittaker JS and Nicholson A. salivary tumours-Experience over thirty years. *Clin Otol* 1979; 4: 247-257.
6. Batsakis JG. Tumours of the head and neck. 2nd edn. Williams and Wilkins, Baltimore 1979, pp1-79.
7. Stanley RE, Mackenzie IJ and Maran AGD. The surgical approach to recurrent pleomorphic adenoma of the parotid gland. *Ann Acad Med Singapore* 1984; 13: 91-95.
8. Watkin GT and Hobsley M. influence of local surgery and radiotherapy on the natural history of pleomorphic adenoma. *Br J Surg* 1986; 73: 74-76.
9. Delarue J. les "Tumeurs mixtes" plurifocales de la glande parotide. *Ann Anat Pathol* 1965; 1: 34-58.
10. Laskawi R, Schott T and Shroder M. recurrent pleomorphic adenomas of the parotid gland: clinical evaluation and long-term follow-up. *Br J Oral Maxillofac Surg* 1998; 36: 48-51.
11. Yasumoto M, Sunaba K, Shibuya H and Kurabayashi T. Recurrent pleomorphic adenoma of the head and neck.

Neuroradiol 1999; 41: 300-304.

12. Dawson AK. Radiation therapy in recurrent pleomorphic

adenoma of the parotid. Int J Radiat Oncol Biol Phy 1989;
16: 819-821.

Author Information

Sethi Ashwani, M.S.

Senior Resident, Department of ENT and Head and Neck Surgery, Maulana Azad Medical College and associated L. N. Hospital

Deepika Sareen, M.S.

Junior Resident, Department of ENT and Head and Neck Surgery, Maulana Azad Medical College and associated L. N. Hospital

A.K. Agarwal, M.S.

Director Professor and Head, Department of ENT and Head and Neck Surgery, Maulana Azad Medical College and associated L. N. Hospital

Ishwar Singh, M.S.

Professor, Department of ENT and Head and Neck Surgery, Maulana Azad Medical College and associated L. N. Hospital