

# Neurology pictorial: Scars of psychosurgery: frontal lobotomy

J Torgovnick, N Sethi, E Arsura, P Sethi

---

## Citation

J Torgovnick, N Sethi, E Arsura, P Sethi. *Neurology pictorial: Scars of psychosurgery: frontal lobotomy*. The Internet Journal of Neurology. 2009 Volume 12 Number 2.

## Abstract

Sir,

Frontal lobotomy, a form of psychosurgery popular in the 1930s to 1950s, involved severing white matter tracks to and fro from the prefrontal cortex<sup>1</sup>. There were many modifications of the basic procedure. The American neurologist Walter Freeman popularized the transorbital frontal lobotomy in which electroconvulsive therapy was used for anesthesia and then an ice-prick resembling instrument called the leucotome was inserted into the orbital roof by lifting the upper eyelid<sup>2,3</sup>. A hammer or a mallet was then used to drive the leucotome through the thin layer of orbital bone into the patient's brain. The leucotome was then swept across from side to side severing the connections of the prefrontal cortex.

Initial popularity of the procedure among both physicians and the lay public led to its widespread use for then poorly defined clinical conditions like schizophrenia, depression and anxiety disorders. Over time frontal lobotomy began to be performed by non-surgeon physicians in the field (mental asylums and prisons) often in non-sterile conditions. Moreover this barbaric surgery was sometimes carried out in children and incarcerated criminals (often without their informed consent) for mood disorders and "youthful defiance" with the intention of re-integrating them into mainstream society<sup>1</sup>. More than 40,000 people were lobotomized in the United States alone.

By the 1950s with the advent of chlorpromazine therapy for psychosis, interest in frontal lobotomy started waning. Moreover the side-effects of this procedure started coming to light. These included increased morbidity and mortality due to peri-procedural complications like infection and cerebral hemorrhage. Patients after the procedure frequently were left with a blunted and at times disinhibited affect, incontinent

and mentally retarded.

Even today in 2008, scars of this barbaric surgery can be seen in the occasional patient scanned for some unrelated neurological condition serving as a timely reminder to us neurologists about the perils of ill-advised psychosurgery (Fig 1, 2, 3).

**Figure 1**

Fig1,2,. Non-contrast CT scan of the head (parenchymal window) showing stigmata of frontal lobotomy

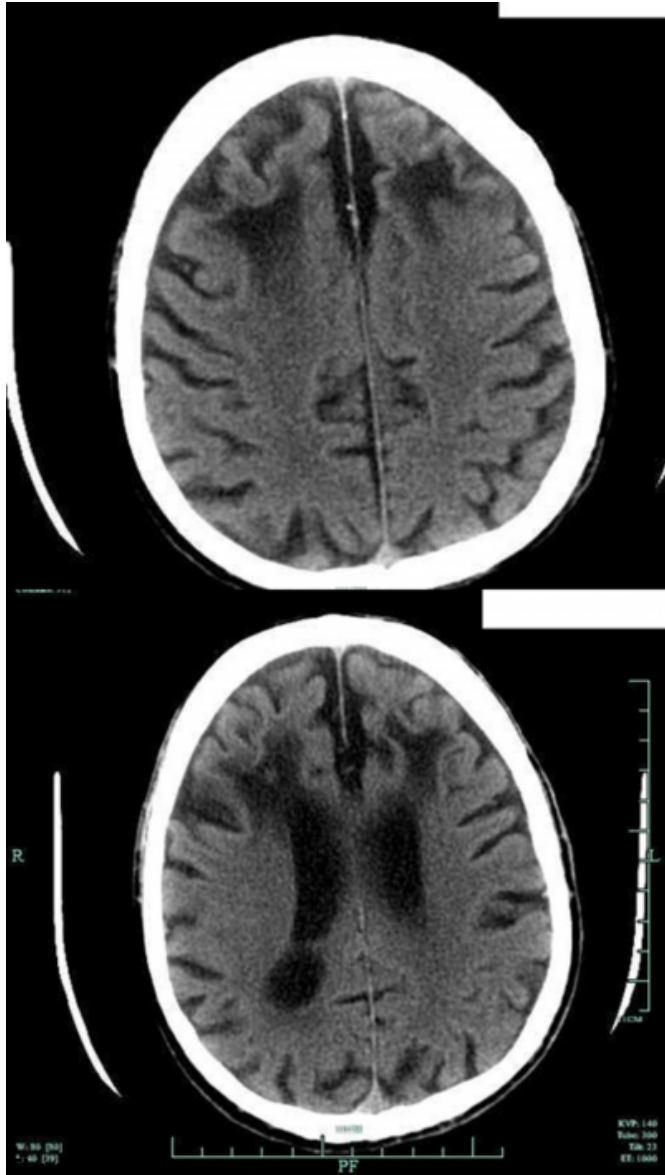
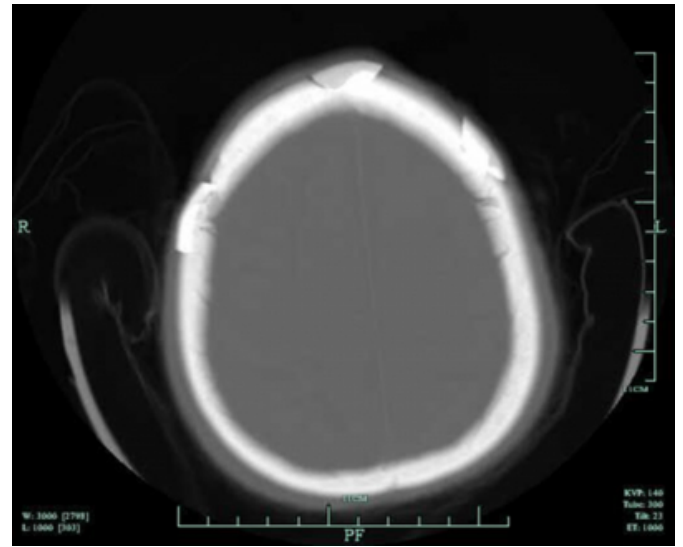


Fig 3. Non-contrast CT scan of the head (bony window)

showing stigmata of frontal lobotomy.



### References

1. Mashour GA, Walker EE, Martuza RL. Psychosurgery: past, present and future. *Brain Res Rev.* 2005 Jun; 48(3):409-19.
2. Freeman W. Frontal leucotomy and its congeners. *Dis Nerv Syst.* 1958 Jan; 19(1):11-5.
3. Freeman W. Frontal lobotomy 1936-1956: a follow up study of 3000 patients from one to twenty years. *Am J Psychiatry.* 1957 Apr; 113(10):877-86.

**Author Information**

**J. Torgovnick, M.D**

Department of Neurology, Saint Vincent's Hospital and Medical Centers

**N.K. Sethi, M.D**

Comprehensive Epilepsy Center, NYP-Weill Cornell Medical Center

**E. Arsura, M.D**

Department of Medicine, Saint Vincent's Hospital and Medical Centers

**P.K. Sethi, M.D**

Department of Neurology, Sir Ganga Ram Hospital