

Rhinosporidiosis Of The Face

D Pal, S Maity, M Chowdhury

Citation

D Pal, S Maity, M Chowdhury. *Rhinosporidiosis Of The Face*. The Internet Journal of Tropical Medicine. 2008 Volume 5 Number 2.

Abstract

Rhinosporidiosis and its causative organism are known more than hundred years but its mode of infection and transmission is still unknown. Here we report a case of rhinosporidiosis in the face induced by trauma with successful outcome with surgery.

INTRODUCTION

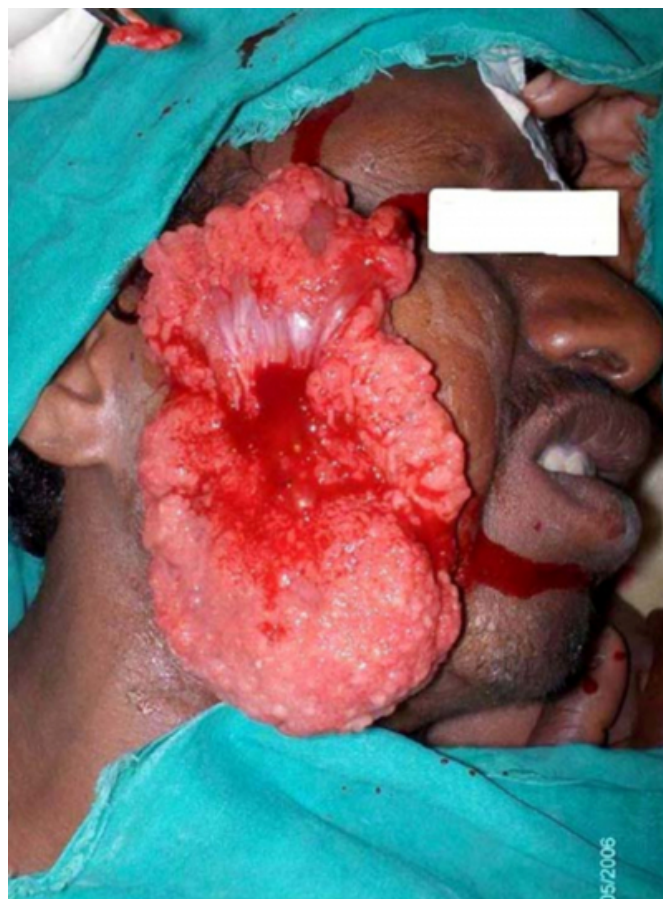
Rhinosporidiosis is a chronic granulomatous disease of muco- cutaneous tissue first described by Guillermo Seeberi in 1900 from Buenos Aires ¹. The first case from India was reported by O'Kineay in 1903 ¹². Life cycle of this fungus was described by Ashworth in 1923 ¹²³. Face is one of the rare site of infection. Infection with contaminated soil through a traumatized mucosa is a strong factor in human cases ⁴⁵. Nowadays adequate surgery with electrocoagulation of the base has established its roll in management of such cases ³⁴⁵.

CASE REPORT

A 37-year-old man from a rural background presented with a slow growing painless swelling on his left cheek for last three years. Initially it was the size of a nut, but

Figure 1

Figure 1: Pedunculated, polypoid mass over face with haemorrhage from the biopsy site.

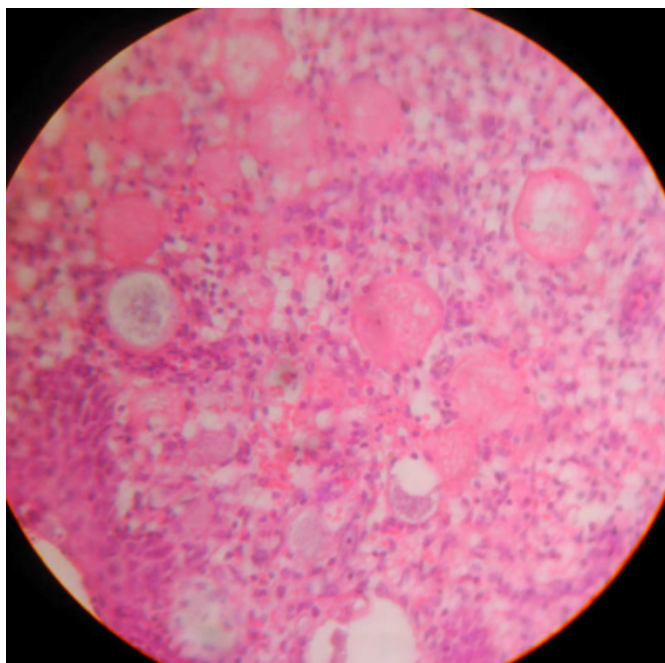


gradually attained the size of 4cm x 3cm (Fig.-1) within three years. Few months back before the appearance of the swelling he had a road traffic accident with abrasion in that region, which healed on application of antibiotic ointment. On examination there was a large pedunculated polypoid mass on the right side of the face with nodular surface. The

draining lymph nodes were just palpable. He was normoglycaemic with a normal haemogram and renal biochemical parameters. Chest x-ray was normal. Biopsy from the swelling showed the typical sporangia of varying sizes having thick walls with moderate infiltration of lymphocytes and plasma cells with overlying hyperplastic squamous epithelium (Fig.-11). Excision of the mass with thorough electro coagulation of the base was done. There is no recurrence till one year of follow up.

Figure 2

Figure 2: Microphotograph showing sporangia of varying sizes with infiltration of lymphocytes and plasma cells. (H & E X 400)



DISCUSSION

Rhinosporidiosis is a chronic granulomatous condition commonly found in India and Sri-Lanka and rarely in Europe¹². Anterior nares and conjunctiva is the most common site of infection, but other rare sites are nasopharynx, larynx, maxillary antrum, skin of limbs, lachrymal sac, urethra, vagina, parotid duct, bone, vagina and rectum¹²³. Face is a very uncommon site of rhinosporidiosis and so far to our knowledge till now no

such case has been reported in the face.

Though it is a fungal disease caused by *Rhinosporidium seeberi*, but its mode of transmission is controversial. Contaminated water and soil seems to be the source of infection¹². The presumed mode of infection from natural habitat of *R. seeberi* is through the traumatized epithelium²³. Frequent bathing in stagnant contaminated pond may lead to infection over a traumatized skin or mucosa⁴⁵. This particular case had a past history of abrasion injury contaminated with soil in the site of the disease. Absence of the disease in the family members of such cases or in the sexual partner in urethral cases proves that the disease is neither infectious nor contagious³. Usually it presents as a discrete, friable, painless, sessile or pedunculated polypoid mass. Sometimes white pin head-sized spots may be seen on the surface due to matured sporangia. A strong suspicion in the endemic areas gives clue to the diagnosis of such condition. Only histology gives the definite diagnosis with identification of the organism in its diverse stages, and the stroma contains chronic inflammatory cells which include macrophages and lymphocytes with numerous neutrophils around the free endospores³. Adequate surgical excision with electro coagulation of the base is the best treatment¹²³⁴⁵ though there is a high chance of recurrence which is mainly due to inadequate excision².

CORRESPONDENCE TO

Dr. Dilip Kumar Pal Vinayak Garden, Flat No.- A/3D 41, Simla Road, Kolkata-700006 West Bengal, INDIA Ph- 0-91-9433132553 E. mail: dr_dkpal@rediffmail.com drdkpal@yahoo.co.in

References

1. Samadder RR, Sen MK. Rhinosporidiosis in Bankura. Indian J Pathol Microbiol 1990; 33: 129-136.
2. Ratnakar C, Madhavan M, Sankaran V, Veliath AJ, Majumdar NK, Rao VA. Rhinosporidiosis in Pondicherry. J Trop Med Hyg 1992; 95: 280-283.
3. Arseculeratne S N. Recent advances in rhinosporidiosis and *Rhinosporidium seeberi*. Ind J Med Microbio 2002; 20: 119-131.
4. Pal DK, Bhattacharyya N, Bag AK, Singh L. Recurrent rhinosporidiosis of male urethra. Ind J Surg 2006; 68: 97-98.
5. Vishwanath S, Hanchanale, Rao A R, Joseph G. A case of Urethral rhinosporidiosis. Urology 2005; 66: 1106-1107.

Author Information

Dilip Kumar Pal, M.S., FAIS, M.Ch(Uro)

Professor and HEAd, Dept. of Urology, Bankura Sammilani Medical College

Sukumar Maity

Professor and Head, Dept. of Surgery, Midnapore Medical College

Manoj Kumar Chowdhury, MD

Professor and Head, Dept. of Pathology, Bankura Sammilani Medical College