

# Traumatic Nasal Bone Graft Fracture

M Enoz, G Payasli, I Yazgin, S Cevli

## Citation

M Enoz, G Payasli, I Yazgin, S Cevli. *Traumatic Nasal Bone Graft Fracture*. The Internet Journal of Otorhinolaryngology. 2006 Volume 7 Number 1.

## Abstract

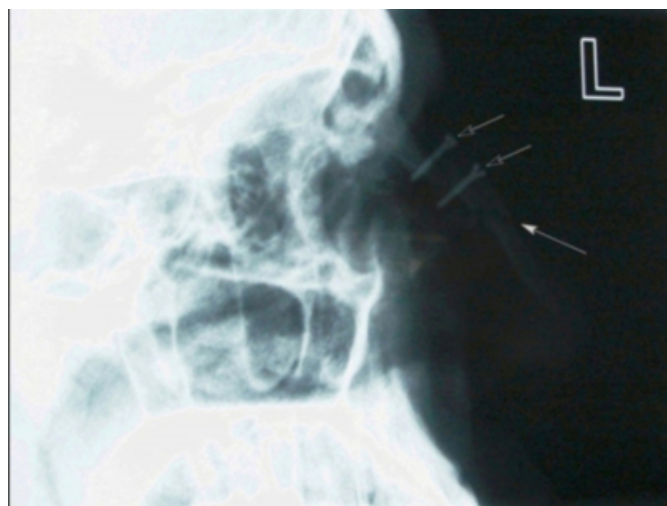
In cases of facial trauma, nasal fractures account for approximately 40 percent of bone injuries but traumatic nasal bone graft fracture is a very rare entity and treatment of this condition is complicated. A patient with nasal bone graft fracture due to trauma is presented and treatment modalities are discussed briefly.

## CASE REPORT

A 30-year-old male patient was admitted to our Clinic of Otolaryngology Head and Neck Surgery, Maresal Cakmak Military Hospital with complaining of facial trauma directly to his nose. In his past medical history, bone graft which was taken from crista iliaca anterior superior reconstruction operation was performed 10 years ago for treatment of saddle nose deformity. The lateral cranial graphy showed that nasal bone graft fracture (Figure 1).

### Figure 1

Figure 1: Lateral cranial graphy, nasal bone graft and two screws (white blank arrows) those are stabilized the graft to nasal bone are showing. Fracture line (filled white arrow) is showing at the 2 centimeters below the inferior screw.



The appearance of the nose was edematous and was not displaced. There was no other facial injury, septal hematoma or epistaxis. Neurologic examination and other system examination were normal. Full blood count was normal.

After the diagnosis of the nasal bone graft fracture, external thermoplastic splint device is applied to nasal dorsum for two weeks. Closed reduction was not performed because of there was no nasal bone displacement. Edema on the nose was disappeared at the second week. Two months later, the lateral cranial graphy showed that fracture line is persisted and there was minimal crepitation with palpation of the nose.

## DISCUSSION

Injuries to the nose are relatively common; in cases of facial trauma, nasal fractures account for approximately 40 percent of bone injuries<sup>(1)</sup>.

The general consensus regarding the preferred treatment for simple displaced nasal fracture is closed manipulation<sup>(2,3,4,5)</sup>.

To our knowledge, there is not any case of "traumatic nasal bone graft fracture" exist on the literature other than this.

It is sophisticated that which treatment modality is proper for this case?

1. Regrafting,
2. Graft reconstruction with mini plaque or screw,
3. Waiting for secondary healing.

First is required more instrumentation and morbidity. In our case we waited for secondary healing because of nasal displacement was not found. However graft fracture was not completely healed after the two months thus we planned to graft reconstruction.

This case highlights that, nasal bone graft fracture is a very

rare entity and the healing time of nasal bone graft fracture may be longer than classical nasal fracture. Thus the patient must be followed up closely. Confirmation of this knowledge required that further investigations.

### **CORRESPONDENCE TO**

Murat Enoz Address: Maresal Cakmak Military Hospital,  
25700, Yenisehir, Erzurum / Turkey Phone: +905554293937  
Fax: +902123439040 Email: muratenoz@gmail.com

### **References**

1. Bartkiw TP, Pynn BR, Brown DH. Diagnosis and management of nasal fractures. *Int J Trauma Nurs.* 1995;1:11-8.
2. Illum P, Kristensen S, Jorgensen K, Brahe Pedersen C. Role of fixation in the treatment of nasal fractures. *Clin Otolaryngol.* 1983;8: 191-5.
3. Robinson J. The fractured nose: late results of closed manipulation. *NZ Med J.* 1984;97:296-7.
4. Crowther J, O'Donaghue G. The broken nose: does familiarity breed neglect? *Ann R Coll Surg Engl.* 1987;62:259.
5. Illum P. Long-term results after treatment of nasal fractures. *J Laryngol Otol.* 1986;100:273-7.

**Author Information**

**Murat Enoz, MD**

Department of ORL & Head and Neck Surgery, Maresal Cakmak Military Hospital

**Goksun Payasli, MD**

Department of Orthopaedics and Traumatology, Maresal Cakmak Military Hospital

**Ilker Yazgin, MD**

Department of ORL & Head and Neck Surgery, Maresal Cakmak Military Hospital

**Salih Cenap Cevli, MD**

Department of General Surgery, Maresal Cakmak Military Hospital