

Tuberous sclerosis: MRI findings

S Singh, V Chowdhury, G Chand

Citation

S Singh, V Chowdhury, G Chand. *Tuberous sclerosis: MRI findings*. The Internet Journal of Radiology. 2007 Volume 9 Number 1.

Abstract

We report a case of tuberous sclerosis.

CASE HISTORY

A 6 year old male child was evaluated for recurrent seizures. A MR examination was performed. T₂W axial (Fig. 1). FLAIR coronal (Fig. 2) and inversion recovery sequences (Fig. 3) were obtained.

Figure 1

Figure 1: Axial TW MR image showing the subependymal nodules along the lateral ventricles as small hypointense foci. There is abnormal high signal in the cortical tubers.

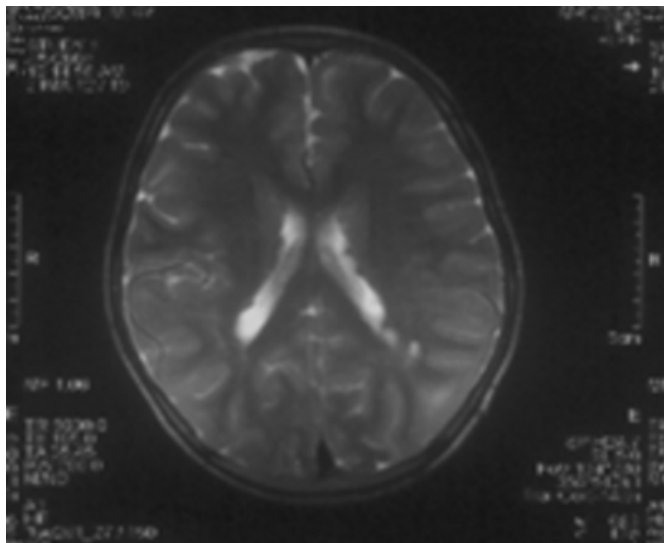


Figure 2

Figure 2: FLAIR coronal MR image depicted the “gyral core sign” seen as enlarged gyri with abnormal central signal hyperintensity.

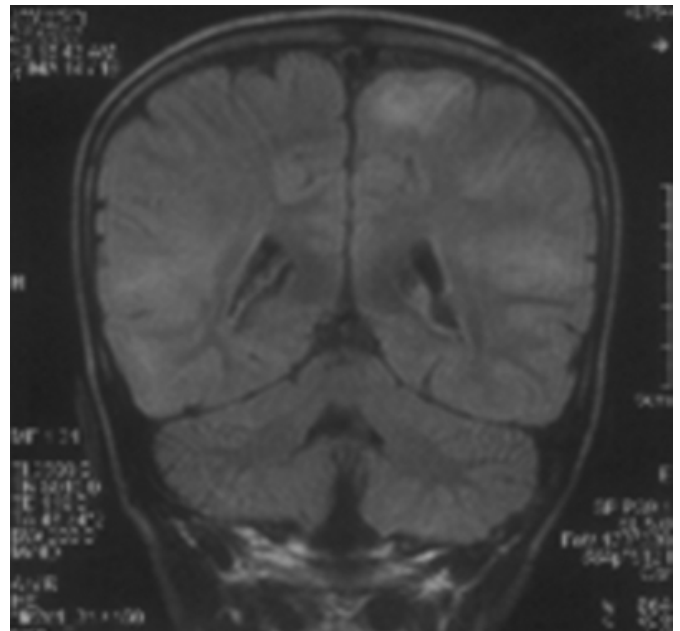
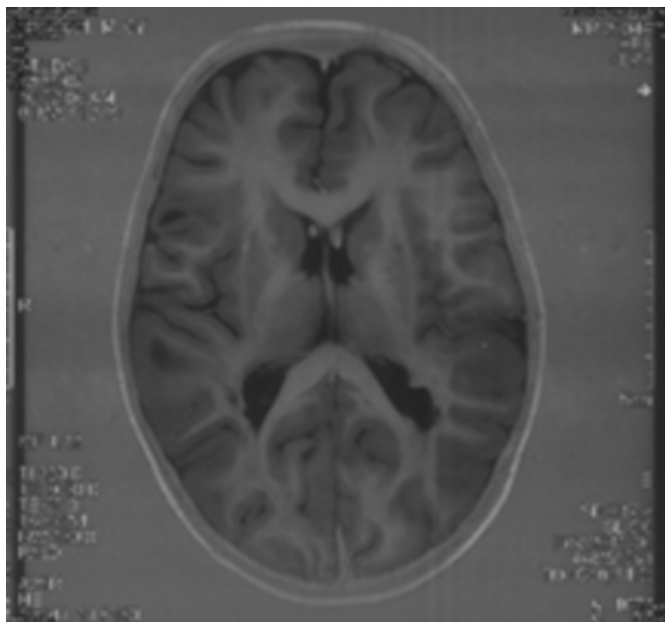


Figure 3

Figure 3: Inversion recovery image best depicted the cortical tubers as large misshapen gyri. There was a slight hyperintensity to the subependymal nodules probably because of the presence of microcalcification.



DISCUSSION

Tuberous sclerosis (TS) is an inherited systemic disease with prominent cutaneous visceral and CNS manifestations. Eponyms for TS include Bourneville disease, Pringle disease cerebral sclerosis and epiloia. The original diagnostic criteria for TS required all the elements of the classic Vogt triad: adenoma sebaceum, epilepsy and mental handicap. However it has been revealed TS has a variable expression of mental retardation [1].

Imaging features without any physical findings or symptoms can also be used to make the diagnosis of TS. The diagnostic features include the presence of multiple subependymal nodules, multiple cortical tubers especially if associated with subcortical white matter edema. A subependymal giant cell astrocytoma and focal cortical calcifications are also highly

suggestive of TS.

Multiple cortical tubers are diagnostic of TS. Cortical tubers are visualized as large misshapen gyri [2]. The abnormal hamartomatous tissue of the cortical tubers has prolonged T₁ and T₂ and appears bright on T₂ weighted images. Cortical tubers only rarely show contrast enhancement on MR with gadolinium [3]. There is a characteristic gyral core sign- the subcortical white matter is abnormally bright and surrounds a sulcus with its gray matter borders of normal intensity [4]. The subependymal nodules may be more obvious on CT because of calcifications and may be subtle on MR [5]. The subependymal giant cell astrocytoma (SGCA) is a benign and slow growing tumour with the major morbidity being related to ventricular obstruction – owing to the propensity of the tumour to arise at the foramen of Monro. On contrast administration there is intense enhancement of the SGCA.

Visceral changes of TS include retinal hamartoma, multiple cysts and angiomyolipomas in the kidney, lymphangiomyomatosis and honey comb lung and angiofibroma of face, Shagreen patch and hypomelanotic macules on the skin [1].

CORRESPONDENCE TO

Dr. SAPNA SINGH 212, SFS FLATS, PHASE IV ASHOK VIHAR DELHI – 110052 TEL. 65434906 e.mail – spsrailways@singhindia.com

References

1. Gomez MR ed. Diagnostic criteria In: Tuberous sclerosis, 2nd ed, New York: Raven Press, 1985: 9-20.
2. Nixon JR, Houser OW, Gomez MR et al. Cerebral tuberous sclerosis Imaging. Radiology 1994; 170: 869-873.
3. Martin N, Debuossche C, De Broucher T et al. Gadolinium DTPA enhanced MR imaging in tuberous sclerosis. Neuroradiology 1990; 31: 492-497.
4. Altman NR, Pruser RU, Donovan Post MJ. Tuberous sclerosis: Characteristics at CT and MR imaging. Radiology 1988; 167: 527-532.
5. Fitz CR, Harwood Nash DCF, Thompson JR. Neuroradiology of tuberous sclerosis in children. Radiology 1974; 110: 635-642.

Author Information

Sapna Singh, M.D., D.N.B (Radio-diagnosis)

Assistant Professor (Radio-diagnosis), Department of Radio-diagnosis, Maulana Azad Medical College Delhi

Veena Chowdhury, M.D. (Radio-diagnosis)

Director-Prof. & Head, Department of Radio-diagnosis, Maulana Azad Medical College Delhi

Gyan Chand, M.D. (Radio-diagnosis)

Department of Radio-diagnosis, Maulana Azad Medical College Delhi