

# CMV Pneumonia in a Renal-Transplant Recipient: Diagnosis and Treatment

B Vahid, D Salerno, T Raman

## Citation

B Vahid, D Salerno, T Raman. *CMV Pneumonia in a Renal-Transplant Recipient: Diagnosis and Treatment*. The Internet Journal of Pulmonary Medicine. 2004 Volume 5 Number 2.

## Abstract

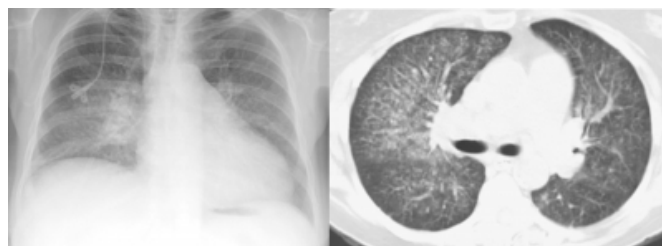
We present a case of CMV pneumonia in a recipient of cadaveric renal transplant. CMV pneumonia was diagnosed by positive CMV polymerase chain reaction in bronchoalveolar lavage. The subject of diagnosis and treatment of CMV pneumonia after renal transplant is reviewed.

## CASE REPORT

The patient is a 68 year-old female that was admitted to the hospital with shortness of breath, low grade fever and cough which started about 2 weeks before presentation. Her physical activity was severely limited secondary to dyspnea. Six months before presentation, she underwent a cadaveric renal transplantation for end-stage renal failure due to poorly controlled type 2 diabetes mellitus. The patient was CMV seronegative pre-operatively and the donor was CMV seropositive. On admission her medications included sirolimus and tacrolimus for immunosuppression and sulfamethoxazole-trimethoprim for *Pneumocystis jiroveci* (*Pneumocystis carinii*) pneumonia prophylaxis. She also received ganciclovir for 3 months after transplantation. Physical examination revealed temperature of 100.4°F, heart rate of 60 beats/min, respiratory rate of 16 breaths/min, blood pressure of 145/60 mmHg. Oxygen saturation was 92% on room air. Mucous membranes and skin were without lesion or rash. Chest auscultation revealed bilateral fine inspiratory crackles. Cardiac, abdominal, and neurological exams were unremarkable. Chest radiograph and computed tomography (CT) scan of chest showed diffuse bilateral fine nodular infiltrates (Figure 1).

## Figure 1

Figure 1: Chest radiograph and CT scan of chest showing bilateral fine nodular infiltrates



The differential diagnosis included sirolimus pulmonary toxicity, viral pneumonia (CMV, HSV, EBV, RSV, and adenovirus), bacterial pneumonia, fungal infection, and *Pneumocystis jiroveci* pneumonia. *Pneumocystis jiroveci* pneumonia is less likely as the patient had received prophylaxis with sulfamethoxazole-trimethoprim. Bronchoscopy with bronchoalveolar lavage was performed. BAL cultures for bacterial, respiratory viruses, fungi, *Legionella*, and *Mycobacterium* were negative. BAL cytology was negative for *Pneumocystis jiroveci*. The Cytomegalovirus (CMV) polymerase chain reaction (PCR) in the BAL showed more than 1,000,000 copies/ml of CMV DNA. The CMV PCR of blood was positive for 40,515 copies/ml of CMV DNA. These findings were consistent with diagnosis of CMV pneumonia. Treatment with ganciclovir was started. In the three weeks following treatment the patient's dyspnea and fever resolved.

## DISCUSSION

Solid organ transplantation for treatment of end-stage renal failure, cirrhosis, heart failure, and lung disease has become

more common in past two decades. New immunosuppressive agents, advanced surgical techniques and improved post-transplant care have contributed to improve outcome in the transplant recipients. Renal transplantation is the most commonly performed solid organ transplantation and accounts for approximately 60% of the cases. Chronic immunosuppression is essential to ensure allograft survival. Immunosuppression increases susceptibility to potentially lethal infectious complications especially pneumonia <sup>1</sup>. CMV is the most common viral pathogen responsible for pneumonia in solid organ transplant recipients <sup>2</sup>.

### DEFINITIONS

Understanding the difference between CMV infection and CMV disease is essential. CMV pulmonary infection is defined as the detection of CMV in the lungs by culture or PCR, irrespective of symptoms or signs of disease. CMV disease is defined as CMV infection with symptoms and/or tissue invasion of CMV and organ damage. Therefore CMV pneumonia is defined as the detection of CMV in lungs with the presence of fever, respiratory symptoms, and pulmonary infiltrates in the absence of other respiratory pathogens <sup>3</sup>.

### PATHOPHYSIOLOGY

After the initial infection, CMV remains in a persistent state in the host. The cells of the myeloid lineage constitute an important reservoir. In carriers, CMV DNA is present in a small proportion of CD34+ myeloid progenitor cells, CD14+ monocytes, dendritic cells, and megakaryocytes without detectable viral replications <sup>4</sup>. CMV replication can be detected in healthy CMV seropositive individuals affected by surgery-related stress and catecholamine release. Such conditions are typical after allogeneic solid-organ transplantation <sup>4</sup>. The virus also may be reactivated due to immunosuppression and increased cytokine production and release induced by sepsis, graft rejection, and drugs like OKT3 <sup>5</sup>. Chronic illness, malnutrition, and metabolic derangements in the renal-transplant candidates put them at higher risk for infection even in pre-operative period. In first six months after transplantation maintenance immunosuppressive therapy is usually maintained at a high level to decrease the chance of allograft rejection. The commonly used immunosuppressive agents like cyclosporine, tacrolimus, and sirolimus prevent IL-2 production or action resulting in T-lymphocyte suppression <sup>1</sup>. This suppression of the cell-mediated immunity increases the risk of CMV pneumonia especially in the first 6 months after surgery <sup>2, 6</sup>. It is now clear that the endorgan damage caused by CMV is the result of replication of the virus

leading to high viral loads. The documented risk factors of donor seropositivity, recipient seronegativity and post-transplant viremia can be explained by high viral load <sup>7</sup>. The regression line of viral load against risk of disease is not linear but sigmoidal suggesting a threshold concept of pathogenesis <sup>7</sup>. It has been suggested that with increase viral replication, cell-to-cell spread of the virus happens and at some point during this process, endothelial cells become infected. Mononuclear and polymorphonuclear leukocytes adhere to infected endothelium and take up the virus and the pp65 matrix protein. Finally infected endothelial cells detach from endovascular lining and can be found in peripheral blood as cytomegalic endothelial cells. These large cells (up to 35 µm) may plug in pulmonary capillary bed and contribute to spread of infection to the lung <sup>5</sup>. CMV induced inflammatory response results in local cytokine production. Cytokines like IL-1, IL-6, and TNF $\alpha$  have been implicated in the pathogenesis of pneumonitis. Another possible mechanism of tissue injury is complement activation. Complement system activation has been shown in active CMV infection <sup>5</sup>.

### CLINICAL MANIFESTATIONS

The overall incidence of CMV pneumonia is 2 to 10% according to different studies in renal-transplant recipients <sup>8</sup>. Subclinical pneumonitis also has been reported in renal-transplant recipients with CMV infection but no clinical symptoms <sup>5</sup>. The development of CMV pneumonia depends on patient's level of immunosuppression and prior CMV serostatus. CMV seronegative patients that receive kidney transplantations from CMV-negative donors (Donor-negative, Recipient-negative) have the lowest incidence of CMV infection. When infection does occur in these patients, it may be caused by false seronegativity in the donor or recipient, community exposure, or perioperative transfusion of leukocyte-containing blood. The use of leukocyte-poor blood substantially decreases the risk of virus transmission. In the case of CMV seronegative recipients of renal-transplants from CMV seropositive donors (Donor-positive, Recipient-negative), primary CMV infection can occur. Without prophylaxis, approximately 70 to 90% of these patients will develop primary CMV infection. Furthermore, 50 to 80% will have CMV disease and roughly 30% will develop pneumonia that is a major contributor to morbidity and mortality. In the absence of prophylactic therapy, the mortality rate is as high as 15%. Up to 70% of CMV seropositive transplant recipients (Recipient-positive) show CMV "reactivation" following transplantation, but only 20%

will develop CMV disease including pneumonia <sup>8</sup>.

CMV disease typically occurs one to six months after transplantation when prophylaxis is not used or one to four months after discontinuation of CMV prophylaxis. Symptoms of CMV pneumonia are nonspecific including cough, dyspnea, and hypoxemia <sup>2</sup>. Other common clinical symptoms of CMV infection in renal-transplant recipients include fever (71%), nausea (32%), and vomiting (25%). Common laboratory findings are elevation of creatinine (74%), thrombocytopenia (43%), and elevation of alkaline phosphatase (24%), leukocytosis (22%), and leucopenia (21%) <sup>9</sup>. Atypical lymphocytosis and a mild elevation in liver enzymes (aspartate aminotransferase and alanine aminotransferase) can also be seen <sup>3</sup>.

In one study, the renal-transplant recipients on mycophenolate mofetil for immunosuppression had increased frequency of organ involvement with CMV and in the number of organs involved with CMV compared to the patients on azathioprine <sup>10</sup>. Immunosuppressive therapy containing tacrolimus or mycophenolate mofetil was also associated with a significantly higher percentage of CMV infections compare to cyclosporine-based immunosuppression <sup>11</sup>. The risk factors for CMV pneumonia in renal-transplant recipients are summarized in table1 <sup>10,11,12</sup>.

Figure 2

Table 1: Risk factors for CMV pneumonia in Renal-Transplant Recipients

Risk Factors
1. Seropositive-Donor, Seronegative-Recipient
2. Post-transplant Viremia
3. OKT3 or ATG administration
4. Tacrolimus or mycophenolate mofetil immuno-suppressive therapy

ATG: Antithymus Globulin

RADIOGRAPHIC FINDINGS

One study showed that the chest radiograph might initially be normal in renal-transplant recipients with respiratory symptoms, while the CT scan of chest demonstrates multiple pulmonary abnormalities <sup>13</sup>. Chest radiographic patterns observed are 1) lobar consolidation 2) focal parenchymal haziness 3) bilateral reticulonodular infiltrates <sup>2</sup>. High resolution CT scan findings in CMV pneumonia include ground-glass opacities, small cenrilobular nodules, and air-space opacities <sup>14, 15</sup>. CT scan findings of CMV pneumonia are nonspecific. In on study of non- HIV

immunocompromised patients, the sensitivity of high resolution CT scan of chest was 50% and the positive predictive value was only 26% for diagnosis of CMV pneumonia<sup>16</sup>.

DIAGNOSIS

The diagnosis of CMV pneumonia is based on symptoms of fever, dyspnea, hypoxemia, and typical infiltrates on chest imaging, combined with the detection of CMV in the BAL. The definitive diagnosis of CMV pneumonia can be made by histological examination of lung tissues obtained by transbronchial or open-lung biopsy. Pathologic finding of cytomegalic cells associated with an inflammatory reaction and tissue destruction are characteristics for CMV pneumonia <sup>3</sup>. Transbronchial and open-lung biopsies are invasive procedures with potential complications. It is desirable to make the diagnosis of CMV pneumonia by non-invasive or less invasive diagnostic methods to avoid complications. The widely used assays for diagnosis of CMV disease are CMV viral culture, antigenemia, DNA, and mRNA <sup>4</sup>.

CMV DETECTION BY CULTURE

The conventional tube CMV culture can take weeks to become positive and has been largely replaced by the rapid shell-vial culture technique. This technique can be processed in 24 to 48 hours. Unlike the conventional culture, the shell-vial assay technique does not depend upon the development of a cytopathic effect in tissue culture. Instead, a fluorescence tagged monoclonal antibody is used to detect a CMV antigen that is expressed early in viral replication. CMV detection by culture (Shell-Vial Assay) in BAL defines pulmonary CMV infection and not necessarily CMV pneumonia <sup>3</sup>.

CONVENTIONAL BAL CYTOLOGY

Nuclear and cytoplasmic inclusion bodies in conventional BAL cytology are the hallmark of CMV disease. Although the sensitivity of CMV inclusion bodies in BAL is only 36.3%, it is very specific for CMV disease (specificity of 99.3%) <sup>3</sup>. The absence of diagnostic CMV nuclear or cytoplasmic inclusions in specimens positive by other modalities (viral culture, hybrid capture assay, and PCR) may in part be explained by low levels of viral replication, insufficient for the appearance of diagnostic inclusions <sup>17</sup>. In advance stages of CMV infection, full virus replication with cytopathic effect results in development of typical inclusions. Therefore, conventional cytology may not be able to detect early stages of CMV infection resulting in

lower sensitivity in CMV disease <sup>3</sup>.

### ANTIGENEMIA

The CMV pp65 antigen assays are done by using pp65 antigen monoclonal antibodies. The results are reported as the number of cells staining positive per 100,000 leukocytes. In symptomatic renal-transplant recipients, positive pp65 antigenemia with cutoff of 10 positive cells /10<sup>5</sup> granulocytes is associated with a sensitivity of 86 - 92% and specificity of 65 - 70% for the diagnosis of CMV disease <sup>18</sup>, <sup>19</sup>. Using an antigenemia cutoff of 100 positive cells/10<sup>5</sup> granulocytes the sensitivity and specificity for diagnosing CMV disease improves to 100% and 96% respectively <sup>20</sup>. The sensitivity is only 46% and specificity only 73% when a pp65 antigen assay is used to predict the development of the CMV disease in an asymptomatic patient with CMV antigenemia, <sup>19</sup>. The quantitative CMV PCR assay and quantitative antigenemia assay do not always show parallel changes in CMV viral load. It has been shown in transplant patients those who are non-neutropenic and are antigen negative can have high viral loads in plasma by quantitative CMV PCR assay. It seems that these two assays are complementary for the diagnosis and treatment of CMV disease <sup>21</sup>. CMV pp65 can be used to monitor treatment of CMV disease <sup>22</sup>.

### PCR

Qualitative and quantitative CMV PCR are available. CMV PCR can be used on whole blood, leukocytes, and plasma <sup>4</sup>. Compare to CMV pp65 antigenemia, CMV PCR (more than 130 CMV DNA copies/ 10<sup>5</sup> peripheral blood leukocytes) has a sensitivity of 95% and specificity of 50% to detect CMV disease <sup>23</sup>. Low specificity is due to CMV DNAemia that was detected in many asymptomatic patients <sup>20</sup>. Quantitative PCR also can be used in the monitoring of viral load during antiviral treatment <sup>22</sup>.

### HYBRID CAPTURE ASSAY

RNA probes are used to detect CMV DNA. Experience with this assay is limited, but has shown promising results <sup>4</sup>.

### NUCLEIC ASSAY SEQUENCE-BASED AMPLIFICATION

This assay allows specific nucleic assay sequence-based amplification of viral mRNA <sup>4</sup>. The assay is a qualitative assay that detects a late mRNA (pp67) <sup>24</sup>. Compare to CMV pp65 antigenemia pp67 the RNA assay has a sensitivity of 20% and specificity of 93% <sup>23</sup>.

### DIFFERENTIAL DIAGNOSIS

Differential diagnosis of CMV pneumonia includes other viral pneumonias (HSV, VZV, RSV, Parainfluenza, and Influenza), P jiroveci pneumonia, drug toxicity, diffuse alveolar hemorrhage, bacterial infections, and fungal infections (D).

### TREATMENT

Ganciclovir has proved effective in the treatment of CMV pneumonia especially in renal-transplant recipients. In other solid-organ and bone marrow recipients Ganciclovir has not been as successful to treat CMV pneumonia<sup>25</sup>. Inside the cells, Ganciclovir is converted to Ganciclovir triphosphate by a gene product of UL97<sup>4</sup>, and inhibits viral DNA polymerase by competitively inhibiting the incorporation of deoxyguanosine triphosphate into viral DNA. The efficacy of intravenous Ganciclovir 5 mg/kg twice a day against CMV is 91.5%. In contrast, Ganciclovir given orally 1 g three times a day is less effective (46.5%) <sup>7</sup>. The recommended dose of intravenous Ganciclovir is 5 mg/kg every 12 hours for 3 weeks combined with high-titer CMV immune globulin. Unlike CMV retinitis, prolonged maintenance therapy with oral Ganciclovir is not recommended. The major toxicities of Ganciclovir includes: granulocytopenia, thrombocytopenia, azoospermia, and rise in serum creatinine. Anemia can also be seen with prolonged treatment <sup>25</sup>. Ganciclovir-induced granulocytopenia can be prevented with the administration of Granulocyte colony-stimulating factor or Granulocyte-macrophage colony stimulating factor. Since 1989, resistant strains of CMV to Ganciclovir have been described. For treatment of infections caused by Ganciclovir resistant CMV strains, Foscarnet is the alternative drug. Foscarnet directly inhibits viral DNA polymerase. Foscarnet has substantial toxicities including renal failure, seizures, and hypocalcemia. Cidofovir is a nucleotide analogue with antiviral activity against CMV. Cidofovir is effective in treating CMV infections but the toxic profile of the drug, especially the nephrotoxicity, has limited its use. Combined Ganciclovir-Foscarnet treatment has also been used for treatment of CMV infections but data are limited. Results of a randomized study in allogeneic stem cell-transplant recipients and solid-organ recipients that compared the combination of Ganciclovir and Foscarnet versus Ganciclovir did not support a synergistic effect of combination therapy<sup>4</sup>. After the institution of antiviral therapy pp65 antigenemia and PCR stay positive longer than shell vial culture <sup>26</sup>.

## PROPHYLAXIS

The optimal duration of prophylaxis is unknown. Oral Acyclovir, oral Ganciclovir, and Valganciclovir have been studied for CMV prophylaxis in transplant patients. In high risk renal-transplant recipients (Donor-positive, Recipient-negative) high dose Acyclovir (3,200 mg/day) decreases the incidence of CMV disease<sup>27</sup>. In one study no CMV antigenemia was detected in 3 months after renal transplant when patients were on oral Ganciclovir prophylaxis. After the 3-month period of prophylaxis recurrence of antigenemia and symptomatic CMV was observed in Donor-positive, Recipient-negative patients but not in Donor-positive, Recipient-positive patients. This study suggests that a 3-month period of oral Ganciclovir appears to be sufficient for Donor-positive, Recipient-positive patients, but longer periods of prophylaxis may be needed in Donor-positive, Recipient-negative patients<sup>28</sup>. Most institutions use approximately three months of prophylaxis.

A preemptive strategy is based on the idea that periodic monitoring of CMV DNA PCR or pp65 antigenemia assay allows the detection of very early systemic infection. This permits prompt treatment, which may limit morbidity and mortality. Studies in solid-organ transplant recipients showed conflicting results in regard to prophylaxis versus preemptive treatment<sup>4</sup>.

## FOOT NOTE

CMV: Cytomegalovirus

BAL: Bronchoalveolar lavage

HSV: Herpes Simplex Virus

RSV: Respiratory Syncytial virus

EBV: Epstein Barr Virus

PCR: Polymerase Chain Reaction

VZV: Varicella Zoster Virus

## ACKNOWLEDGEMENTS

We thank Miss Poopak Shahideh for her support.

## CORRESPONDENCE TO

Bobbak Vahid Department of Pulmonary and Critical Care Medicine, Thomas Jefferson University, 1015 Chestnut Street, Suite M-100, Philadelphia, PA 19107, USA  
Telephone: 215-9556591, Fax: 215-9550830 Fax Number: 215-9550830 E-mail: Bobbak.vahid@mail.tju.edu

## References

1. Chakinala M, Trulock E. Pneumonia in the solid organ transplant patient. *Clin Chest Med*. 2005; 26:113-121.
2. Shorr A, Susla, GM, O'Grady, NP. Pulmonary infiltrates

- in the non-HIV-infected immunocompromised patient: Etiologies, diagnostic strategies, and outcome. *Chest*. 2004; 125:260-271.
3. Tamm M, Traenkle P, Grilli B, et al. Pulmonary cytomegalovirus infection in immunocompromised patients. *Chest*. 2001; 119:838-843.
4. Gandhi MK, Khanna R. Human cytomegalovirus: Clinical aspects, immune regulation, and emerging treatments. *Lancet Infect Dis*. 2004; 4:725-738.
5. de Maar E, Kas-Deelen A, van der Mark, TW, et al. Cytomegalovirus pneumonitis after kidney transplantation is not caused by plugging of cytomegalic endothelial cells only. *Transpl Int*. 1999; 12:56-62.
6. Grimaldi A, Baeletta A, Rascente F, et al. Infectious complications in the renal transplant recipient. *Transpl Proc*. 2005; 37:2502-2503.
7. Griffith P. The treatment of cytomegalovirus infection. *Journal antimicrobial Chemotherapy*. 2002; 49:243-253.
8. Chang G, Wu C, Pan S, et al. The diagnosis of pneumonia in renal transplant recipients using invasive and noninvasive procedures. *Chest*. 2004; 125:541-547.
9. Pour-Reza-Gholi F, Labibi A, Farrokhi F, et al. Signs and symptoms of cytomegalovirus disease in kidney transplant recipients. *Transpl Proc*. 2005; 37:3056-3058.
10. Sarmiento J, Dockrell D, Schwab T, et al. Mycophenolate mofetil increases cytomegalovirus invasive organ disease in renal transplant patients. 2000; 14:136-138.
11. Reichenberger F, Dickmann M, Binet I, et al. Diagnostic yield of bronchoalveolar lavage following renal transplantation. *Transpl Infect Dis*. 2001; 3:2-7.
12. Sagedal S, Nordal K, Hartmann A, et al. Pre-emptive therapy of CMVpp65 antigen positive renal transplant recipients with oral ganciclovir: A randomized, comparative study. *Nephrol Dial Transplant*. 2003; 18:1899-1908.
13. Gulati M, kaur R, Jha V, et al. High-resolution CT in renal transplant patients with suspected pulmonary infections. *Acta Radiol*. 2000; 41:237-241.
14. Gasparetto E, Ono S, Escuissato D, et al. Cytomegalovirus pneumonia after bone marrow transplantation: High resolution CT findings. *British J Radiol*. 2004; 77:724-727.
15. Shimada A, Koga T, Shimada M, et al. Cytomegalovirus pneumonitis presenting small nodular opacities. *Intern Med*. 2004; 43:1198-1200.
16. Emoto T, Matsumoto T, Tanaka N, et al. HRCT findings of pulmonary complications in non-AIDS immunocompromised patients: Are they useful in differential diagnosis? *Radiation Medicine*. 2003; 21:7-15.
17. Masih A, Woods G, Thiele G, et al. Detection of cytomegalovirus in bronchoalveolar lavage: A comparison of techniques. *Modern pathology*. 1991; 4:108-112.
18. Schroeder R, Michelin T, Bortolotto A, et al. Antigenemia for cytomegalovirus in renal transplantation: Choosing a cutoff for the diagnosis criteria in cytomegalovirus disease. *transplant Proc*. 2005; 37:2781-2783.
19. Bernabeu-Wittel M, Pachón-Ibáñez J, Cisneros E, et al. Quantitative pp65 antigenemia in the diagnosis of cytomegalovirus disease: Prospective assessment in a cohort of solid organ transplant recipients. *J infect*. 2005; 51:188-194.
20. Lo C, Ho K, Yuen K, et al. Diagnosing cytomegalovirus disease in CMV seropositive renal allograft recipients: A comparison between the detection of CMV DNAemia by polymerase chain reaction and antigenemia by CMV pp65 assay. *Clin Transplant*. 1997; 11:286-293.
21. Flexman J, Kay I, Fonte R, et al. Differences between the quantitative antigenemia assay and the cobas amplicor

monitor quantitative PCR assay for detecting CMV viraemia in bone marrow and solid organ transplant patients. *J Med Virol.* 2001; 64:275-282.

22. Piiparinen H, Helanterä I, Lappalainen M, et al. Quantitative PCR in the diagnosis of CMV infection and in the monitoring of viral load during the antiviral treatment in renal transplant patients. *J Med Virol.* 2005; 76:367-372.

23. Mengoli C, Cusinato R, Biasolo M, et al. Assessment of CMV load in solid organ transplant recipients by pp65 antigenemia and real-time quantitative DNA PCR assay: Correlation with pp67 RNA detection. *J Med Virol.* 2004; 74:78-84.

24. Caliendo A, St. George, K, Allegra J, et al. Distinguishing cytomegalovirus (CMV) infection and disease with CMV nucleic acid assays. *J Clin Microbiol.* 2002; 40:1581-1586.

25. Crumpacker C. Drug therapy: Ganciclovir. *N Engl J Med.* 1996; 335:721-729.

26. Storch G, Buller R, Baily T, et al. Comparison of PCR and pp65 antigenemia assay with quantitative shell vial culture for detection of cytomegalovirus in blood leukocytes from solid-organ transplant recipients. *J Clin Microbiol.* 1994; 32:997-1003.

27. Rostaing L, Martinet O, Cisterne J, et al. CMV prophylaxis in high-risk renal transplant patients (D+/R-) by acyclovir with or without hyperimmune (CMV) immunoglobulin: A prospective study. *Am J Nephrol.* 1997; 17:489-494.

28. Murray B, Subramaniam S. Late cytomegalovirus infection after oral ganciclovir prophylaxis in renal transplant recipients. *transpl Infect Dis.* 2004; 6:3-9.

**Author Information**

**Bobbak Vahid**

Department of Pulmonary and Critical care, Thomas Jefferson University

**Daniel Salerno**

Department of Pulmonary and Critical care, Thomas Jefferson University

**Tuhina Raman**

Department of Pulmonary and Critical care, Thomas Jefferson University