

Pyknodysostosis: Anaesthetic considerations – A Case report

S Kiran, M Goel, P Singhal, M Goel, R Gupta

Citation

S Kiran, M Goel, P Singhal, M Goel, R Gupta. *Pyknodysostosis: Anaesthetic considerations – A Case report*. The Internet Journal of Anesthesiology. 2008 Volume 21 Number 2.

Abstract

Pyknodysostosis is a rare autosomal-recessive disorder of osteoclast dysfunction. We describe anaesthetic management of a 35 year old male having pyknodysostosis with fracture shaft left femur. He had anticipated difficult intubation. Therefore, spinal anaesthesia was provided for his fracture fixation. The intra and post-operative period remain uneventful.

IMPLICATION STATEMENT

Patients having pyknodysostosis usually have frequent fractures and may present for open reduction and internal fixation. Their characteristic features predispose them to difficult intubation. Regional anaesthesia is the technique of choice whenever applicable.

INTRODUCTION

Pyknodysostosis is a rare autosomal-recessive disorder of osteoclast dysfunction causing osteosclerosis. The name derives from the Greek “pyknos,” meaning dense. This disorder was first described by Maroteaux and Lamy in 1962¹. The disorder is also known as Toulouse-Lautrec syndrome, named for the famous French artist who was thought to be afflicted with pyknodysostosis². It is an autosomal recessive disorder due to mutation of cathepsin K gene³. It is a systemic bone disease primarily characterized by osteosclerosis, short stature associated with peculiar pigmy like faces and, hypoplasia and absence of mandibular angle. Patients usually presents with frequent fractures, which can occur even after relatively mild trauma. Patients may present with recurrent dental abscesses, or obstructive sleep apnea.

CASE REPORT

A 35 year old male having pyknodysostosis with fracture shaft left femur presented for fracture fixatation. He had alleged history of slipping in water-logged field. The patient had spontaneous fracture four times in the past also which were managed conservatively. General condition of the patient was good. His mental and sexual developments were normal He had a mal-united sub-trochanteric fracture of

right femur. Patient had a history of snoring. He had no history suggestive of disease of internal organs. He had characteristic short stature, pigmy like faces, large head with frontal bossing, separated cranial sutures, open fontanelle, beaked nose, receding jaw, hypoplasia of mandible and obtuse mandibular angle, high arched palate and irregular dentition with a Mallampati Grade IV. He also had abnormal dentition, drumstick like fingers, and skin over dorsum of distal fingers was wrinkled. The patient height was 140 cm, upper limb to lower limb ratio was – 65/81, sitting height – 76 cm, weight – 42 kg, and arm span was – 138.4 cm. All hematological investigations were within normal limits. The patient’s X-rays showed increased bone density and osteolysis of distal phalanges. Lumbar spine X-rays showed reduced inter-vertebral spaces.

Figure 1

Figure 1: Pigmy like faces, beaked nose, receding jaw and obtuse mandibular angle

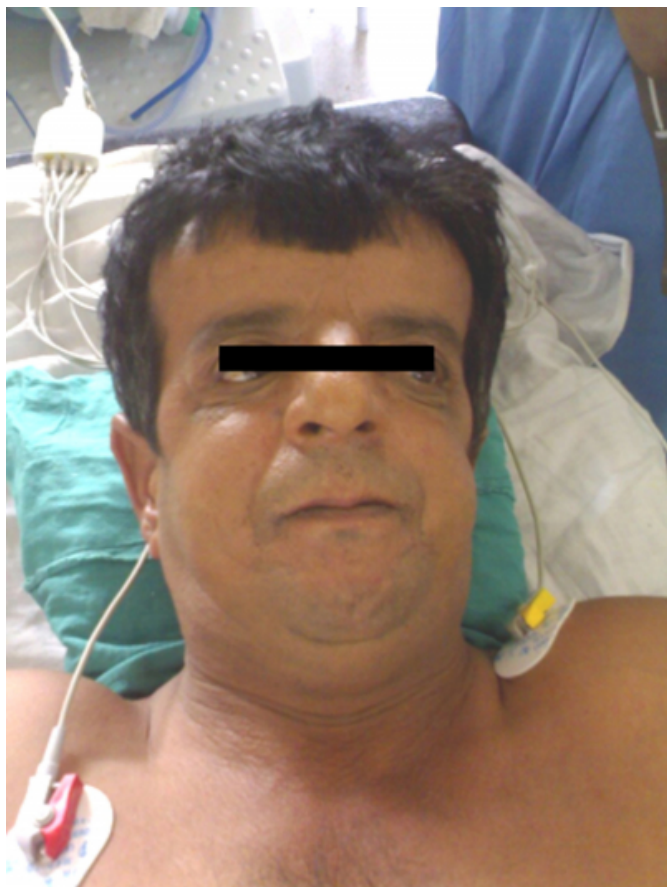

Figure 2

Figure 2. Abnormal dentition and high arched palate

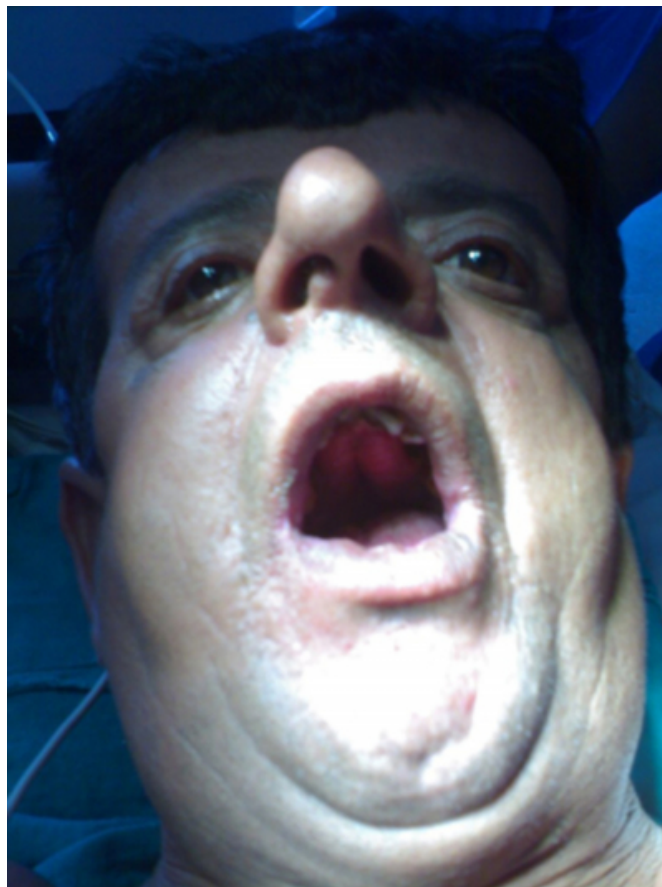
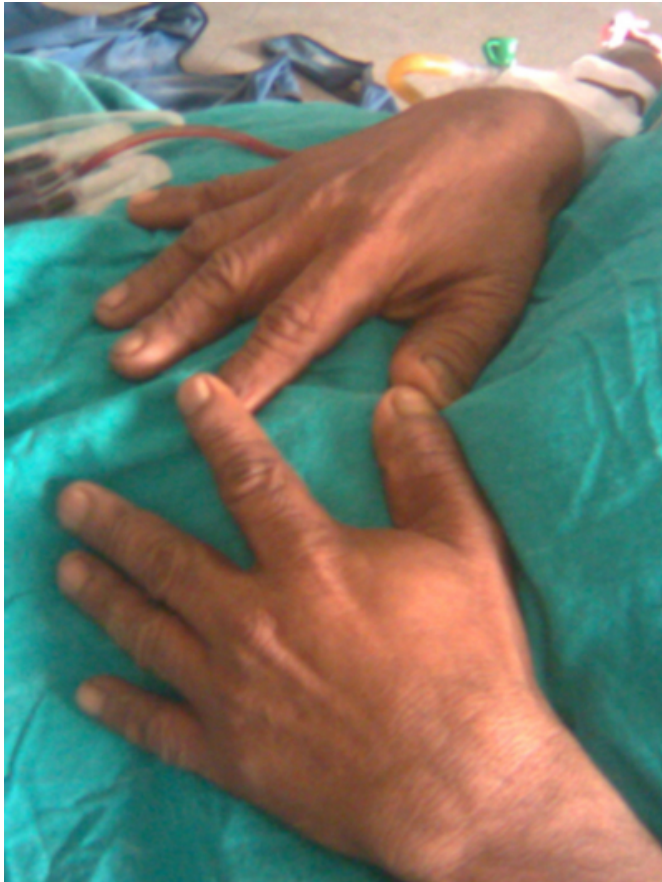

Figure 3

Figure 3: Drumstick like short fingers and wrinkled skin over dorsum of fingers



Upon arrival in operating room intravenous access was established. Monitoring of Electrocardiograph, heart rate, SpO₂ and NIBP was done. Spinal anaesthesia was given with injection bupivacaine hydrochloride, 2.0 ml at L2-L3 space under all aseptic precautions, in sitting position in single attempt. The patient then positioned supine and a sensory level up to T10 was achieved. Intra-operative and Post-operative period was uneventful. The patient was discharged home on 7th day.

DISCUSSION

Pyknodysostosis is a rare autosomal-recessive disorder of osteoclast dysfunction and some features of pyknodysostosis overlap with the more common conditions are osteopetrosis and cleidocranial dysostosis⁴. Differentiating features being short stature, open cranial sutures; there is loss of angle of mandible and hands, feet have aplastic tufts, short phalanges and overriding nails. This condition has been described all over the world affecting all races. The similarity in appearance of patients regardless of sex and race is striking². No age is spared; the youngest patient reported was a nine

month old baby and oldest being 45 years in age. Both sexes are affected with a slight predominance in males. General features of Pyknodysostosis include short stature (height <150 cm), generalized diffuse osteosclerosis with a tendency for fracture even after minimal trauma, hypoplastic clavicles,⁴⁵ as well as acro-osteolysis with sclerosis of the terminal phalanges—a feature that is considered essentially pathognomonic²⁶. Cranial and maxillofacial features include frontoparietal bossing, thick calvaria, open fontanelles and sutures, hypoplastic paranasal sinuses, Wormian bones in the lambdoidal region, relative proptosis, beaked nose, and an obtuse mandibular gonial angle, often with relative prognathism⁷. There may be persistence of deciduous with premature or delayed eruption of permanent teeth causing crowding. The follicles of these un-erupted teeth may become infected, leading to abscess formation⁸. Many of these findings were seen in our patient and differentiating him from osteopetrosis and cleidocranial dysostosis. Facial features, skeletal and dental abnormality were the most impressive findings in this patient Parental consanguinity is recognized in this autosomal-recessive disorder, gene being located on chromosome 1q21⁹. Gene encodes cathepsin K, a cysteine proteinase expressed in normal osteoclasts and is mutated³. Patient's one elder brother also had similar features.

Although there had been various reports describing characteristics features, but there is limited published material describing the anaesthetic considerations in patients with pyknodysostosis. Demonstrating the exact relationships among abnormal findings and managing accordingly the anaesthetic interventions can aid in improving the outcome of the procedures and avoiding unwanted complications in these patients. In these patients general anaesthesia is preferably avoided. Spinal anaesthesia is the technique of choice especially in lower limb surgery. Intrathecal opioids can be added. If general anaesthesia is to be administered then difficult intubation should be anticipated. Clavicular abnormalities can make subclavian catheter placement difficult. History of obstructive sleep apnea may have a risk of airway obstruction in postoperative period hence, it should be carefully addressed.

References

1. Bathi RJ, Masur VN. Pyknodysostosis: a report of two cases with a brief review of the literature. *Int J Oral Maxillofac Surg* 2000;29:439–42.
2. Fleming KW, Barest G, Sakai O. Dental and Facial Bone Abnormalities in Pyknodysostosis: CT Findings. *American Journal of Neuroradiology* 2007;28:132-4.
3. Krane SM, Schiller AL. Hyperostosis, fibrous dysplasia,

and other dysplasias of bone and cartilage. In: Fauci AS, Braunwald E, Isselbacher KJ, et al, eds. *Harrison's Principles of Internal Medicine*. New York: McGraw-Hill;1998:2269–75.

4. Beighton P, Horan F, Hamersma H. A review of osteopetroses. *Postgrad Med J* 1977;53:507–16.

5. Hunt NP, Cunningham SJ, Adnan N, Harris M. The dental, craniofacial, and biochemical features of pyknodysostosis: a report of three new cases. *J Oral Maxillofac Surg* 1998;56:497–504.

6. Helms CA. Metabolic bone disease. In: Brant WE, Helms

CA, eds. *Fundamentals of Diagnostic Radiology*. Philadelphia: Lippincott Williams & Wilkins; 1999; 1049–59

7. Glass RBJ, Fernbach SK, Norton KI, et al. The infant skull: a vault of information. *RadioGraphics* 2004;24:507–22

8. Z Emami-Ahari, M Zarabi, B Javid. Pycnodysostosis. *J Bone Joint Surg* 1969; 51B:307-12

9. Baum VC, O'Flaherty JE. *Anesthesia for Genetic Metabolic and Dysmorphic Syndromes of Childhood*. 2nd ed. Philadelphia: Lippincott Williams & Wilkins; 2007.

Author Information

Sashi Kiran

Professor Anaesthesiology, Pt. B.D. Sharma PGIMS, Rohtak

Meenu Goel, M.D. (Anaesthesia)

Astt. Professor, Dept. of Anaesthesiology, PGIMS, Rohtak

Priyanka Singhal, M.B.B.S.

Post-graduate student, Dept. of Anaesthesiology, PGIMS, Rohtak

Manish Kumar Goel, M.D. (Community Medicine)

Astt. Professor, Dept. of Community Medicine, PGIMS, Rohta

Rakesh Gupta, M.S. (Orthopedics)

Professor, Dept. of Orthopedics, PGIMS, Rohtak